

Expression of a tumor necrosis factor-alpha transgene in murine lung causes lymphocytic and fibrosing alveolitis. A mouse model of progressive pulmonary fibrosis.

Y Miyazaki, ... , P F Piguet, P Vassalli

J Clin Invest. 1995;**96**(1):250-259. <https://doi.org/10.1172/JCI118029>.

Research Article

The murine TNF-alpha gene was expressed under the control of the human surfactant protein SP-C promoter in transgenic mice. A number of the SP-C TNF-alpha mice died at birth or after a few weeks with very severe lung lesions. Surviving mice transmitted a pulmonary disease to their offspring, the severity and evolution of which was related to the level of TNF-alpha mRNA in the lung; TNF-alpha RNA was detected in alveolar epithelium, presumably in type II epithelial cells. In a longitudinal study of two independent mouse lines, pulmonary pathology, at 1-2 mo of age, consisted of a leukocytic alveolitis with a predominance of T lymphocytes. Leukocyte infiltration was associated with endothelial changes and increased levels of mRNA for the endothelial adhesion molecule VCAM-1. In the following months, alveolar spaces enlarged in association with thickening of the alveolar walls due to an accumulation of desmin-containing fibroblasts, collagen fibers, and lymphocytes. Alveolar surfaces were lined by regenerating type II epithelial cells, and alveolar spaces contained desquamating epithelial cells in places. Platelet trapping in the damaged alveolar capillaries was observed. Pulmonary pathology in the SP-C TNF-alpha mice bears a striking resemblance to human idiopathic pulmonary fibrosis, in which increased expression of TNF-alpha in type II epithelial cells has also been noted. These mice provide a valuable animal model for understanding the pathogenesis of [...]

Find the latest version:

<https://jci.me/118029/pdf>



Expression of a Tumor Necrosis Factor- α Transgene in Murine Lung Causes Lymphocytic and Fibrosing Alveolitis

A Mouse Model of Progressive Pulmonary Fibrosis

Yoshitaka Miyazaki, Kimi Araki, Christian Vesin, Irene Garcia, Yusuf Kapanci, Jeffrey A. Whitsett,* Pierre-François Piguet, and Pierre Vassalli

Department of Pathology, University of Geneva, CH 1211 Geneva 4, Switzerland; and *Division of Pulmonary Biology, Children's Hospital Medical Center, Department of Pediatrics, College of Medicine, University of Cincinnati, Cincinnati, Ohio 45229-2899

Abstract

The murine TNF- α gene was expressed under the control of the human surfactant protein SP-C promoter in transgenic mice. A number of the SP-C TNF- α mice died at birth or after a few weeks with very severe lung lesions. Surviving mice transmitted a pulmonary disease to their offspring, the severity and evolution of which was related to the level of TNF- α mRNA in the lung; TNF- α RNA was detected in alveolar epithelium, presumably in type II epithelial cells. In a longitudinal study of two independent mouse lines, pulmonary pathology, at 1–2 mo of age, consisted of a leukocytic alveolitis with a predominance of T lymphocytes. Leukocyte infiltration was associated with endothelial changes and increased levels of mRNA for the endothelial adhesion molecule VCAM-1. In the following months, alveolar spaces enlarged in association with thickening of the alveolar walls due to an accumulation of desmin-containing fibroblasts, collagen fibers, and lymphocytes. Alveolar surfaces were lined by regenerating type II epithelial cells, and alveolar spaces contained desquamating epithelial cells in places. Platelet trapping in the damaged alveolar capillaries was observed. Pulmonary pathology in the SP-C TNF- α mice bears a striking resemblance to human idiopathic pulmonary fibrosis, in which increased expression of TNF- α in type II epithelial cells has also been noted. These mice provide a valuable animal model for understanding the pathogenesis of pulmonary fibrosis and exploring possible therapeutic approaches. (*J. Clin. Invest.* 1995. 96:250–259.) **Key words:** surfactant • promoter • pneumocytes • VCAM-1 • endothelium

Introduction

Idiopathic pulmonary fibrosis is a group of usually fatal disorders of the lung characterized by an alveolitis which progresses to interstitial fibrosis (1). It is generally assumed that the infiltration of inflammatory cells and the proliferation of interstitial

cells associated with fibrosis are caused by an overproduction of cytokines. Platelet-derived growth factor (PDGF), transforming growth factor β (TGF- β), and tumor necrosis factor α (TNF- α) have been incriminated in the pathogenesis of idiopathic pulmonary fibrosis (2–5). TNF- α is a cytokine with both inflammatory and fibrogenic activities (6). TNF- α mRNA and protein have been detected in lungs from patients with idiopathic pulmonary fibrosis (7, 8) and in lungs from mice with pulmonary fibrosis elicited by exposure to bleomycin (9) or silica (10). In those experimental models, pulmonary inflammation and fibrosis were prevented by injection of anti-TNF antibodies (9, 10) or of TNF- α antagonists (11).

Administration of TNF- α , either intravenously or intratracheally, elicits a severe alveolitis resembling the adult respiratory distress syndrome but with little fibrosis (12); this, however, is an acute type of exposure to TNF- α . To assess the potential role of TNF- α in the pathogenesis of the lesions associated with pulmonary fibrosis, it may be necessary to expose the lung to small amounts of this cytokine for a prolonged period of time. We have therefore produced transgenic mice in which the TNF- α gene was placed under the control of the transcriptional promoter of the surfactant protein C (SP-C)¹ gene. SP-C is synthesized and secreted by alveolar type II epithelial cells and serves to enhance the spreading of surfactant phospholipids at the alveolar surface to reduce surface tension of the air-liquid interface (13). TNF- α was expressed in the lungs of these transgenic mice, producing severe alveolitis, alveolar disruption, and progressive pulmonary fibrosis.

Methods

Mice. C57BL/6xDBA2 F1 (B6D2F1), C57BL/6, Balb/c mice of either sex were purchased from IFFA Credo (L'Abresles, France). Transgenic founder mice (B6D2F1) were backcrossed with C57BL/6 or Balb/c mice in our animal facilities to generate F1 hybrid transgenic mice.

Construction of the SP-C/TNF- α . A 3.7-kb fragment from the 5'-flanking region of the human SP-C gene (14, 15) was cloned into the HindIII site of a pBluescript II SK- plasmid (pBSII) (Stratagene, La Jolla, CA). Two kinds of chimeric constructs were prepared: (a) SPC/TNF- α -UT, which contained the entire 3' untranslated region (UTR) of the mouse TNF- α gene (16), obtained by introducing the NarI/SalI fragment containing all the coding sequence and 3'UTR of the TNF- α gene into the EcoRV site of pBSII containing the SP-C promoter; and (b) SPC/TNF- α -pA, which lacked the 3'UTR sequence of the TNF- α gene, obtained by introducing the NarI/EcoRI fragment of the TNF- α

Address correspondence to Pierre Vassalli, Department of Pathology, University of Geneva, 1, rue Michel-Servet, CH 1211 Geneva 4, Switzerland. Phone: 22-70-25-745; FAX: 22-70-25-746.

Received for publication 30 January 1995 and accepted in revised form 22 March 1995.

J. Clin. Invest.

© The American Society for Clinical Investigation, Inc.

0021-9738/95/07/0250/10 \$2.00

Volume 96, July 1995, 250–259

1. **Abbreviations used in this paper:** ICAM-1, intercellular adhesion molecule-1; SP-C, surfactant protein C; UTR, untranslated region; VCAM-1, vascular cell adhesion molecule-1.

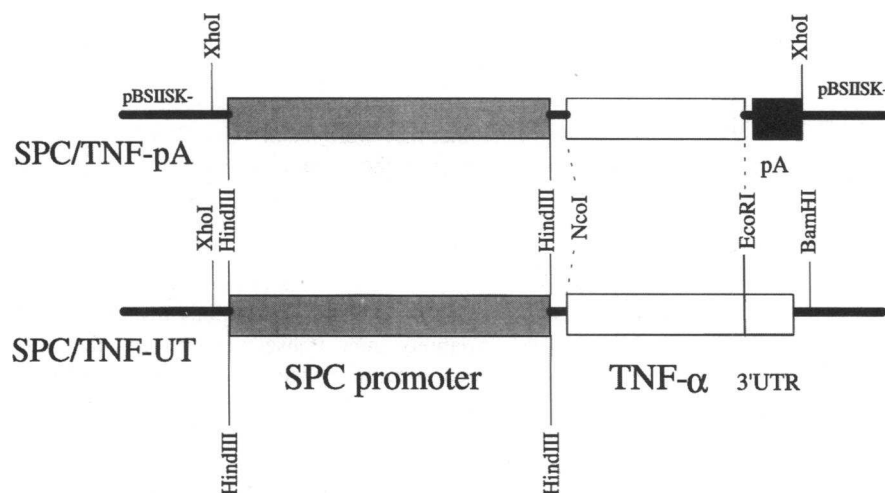


Figure 1. Restriction map of the two constructs used as transgenes. In the upper construct, the 3'UT region of the TNF- α gene has been replaced by a globin intron and a polyadenylation sequence (pA) while the lower construct contains the intact 3'UT region (3'UTR) of the TNF- α gene.

gene into the EcoRV site of pBSII containing the SP-C promoter. A rabbit globin intron and a polyadenylation signal sequence obtained from the pCAGGS plasmid (17) were placed 3' of the TNF- α gene. The structure of these two constructs is shown in Fig. 1.

Generation and identification of transgenic mice. The SPC/TNF- α -UT and SPC/TNF- α -pA DNAs were excised from the parental plasmids by digestion with BamHI and XhoI or XhoI and purified by agarose gel electrophoresis and passage through NACS PREPAC (GIBCO BRL, Gaithersburg, MD). Recovered DNA was resuspended in 10 mM Tris-HCl (pH 7.4)/1 mM EDTA and the concentration was adjusted to 50 ng/ μ l. Purified DNA, kept at -20°C , was diluted 10 times with H_2O before microinjection into the male pronucleus of B6D2F1 fertilized eggs. After egg transplantation into pseudopregnant foster mothers, transgenic offspring were identified by PCR analysis of genomic DNA isolated from tail biopsies, using a 5' primer specific to the SPC promoter (5' AGATATGTGGGAGGAGGCAA 3') and a 3' primer specific to the TNF- α gene (5'GAGAAGAGGGTGAGACATAG 3'). Transgene copy numbers were estimated by Southern blots of genomic DNA.

Northern blot analysis. RNAs, prepared from a variety of mouse tissues by a guanidine isothiocyanate extraction procedure, were analyzed on Northern blots as described previously (18) by hybridization with murine cRNAs probes. Equality of sample loading and efficiency of the transfer were controlled by staining the filters with methylene blue in 0.5 M sodium acetate, pH 4.8. Filters were hybridized with ^{32}P -labeled cRNA probes for: TNF- α (18), interleukin-1 (18), interleukin-6, granulocyte macrophage colony stimulating factor (GM-CSF) (19), c-sis PDGF-B (20), TGF- α (21) and - β (22), E-selectin (23), vascular cell adhesion molecule-1 (VCAM-1) (24), and intercellular adhesion molecule-1 (ICAM-1) (25).

In situ hybridization. ^{32}P -labeled mouse TNF- α cRNA probes and control sense probes were used for in situ hybridization, which was performed as described elsewhere with detection of the radioactive probes on emulsion coated slides (26) or by exposure to x-ray film (27).

Hydroxyproline assay. Hydroxyproline assay was performed as described elsewhere (28).

Histological and morphometric analysis. Mice were exsanguinated by opening the aorta under ether anesthesia. Tissues were taken and fixed immediately by immersion in 4% buffered paraformaldehyde solution. Lungs were fixed by intratracheal instillation of 2% glutaraldehyde or 4% paraformaldehyde after opening of the thorax. Tissues sections were stained by hematoxylin and eosin, Prussian-blue, Grocott, and Gram or by the Gomori's silver impregnation method (29). For morphometric analysis, horizontally oriented histologic sections taken from the left lung were examined with a Vidas image analysis system (C. Zeiss, Oberkochen, Germany) using the software package VIDAS release 2.1 (Kontron Elektronik, GmbH, Eching, Germany). The sections were

scanned with a black and white Burle CCD camera, type FMC-4005 (AVT-Horn, Aalen, Germany) through an Axiophot photomicroscope. The CCD camera was connected via a fram grabber board to a 386 Intel PC. Three to five random selected fields were examined for each section. Images were stored on an optical disk and displayed on a VGA/RGB monitor via a TV video input/output. The background of the image was balanced within a rectangular 512×512 pixel frame. The air spaces were reconstructed by a grain function and the size and number of different areas were recorded. Areas in pixels were converted to square microns using a calibrated reference surface.

Immunohistochemistry. Stainings were performed either on deparaffinized sections obtained from formol-fixed and paraffin-embedded tissue or on cryostat sections from lungs instilled with OCT 4583 (Miles Inc., Elkhart, IN). The following antibodies were used to identify the cells or their content: for fibroblasts, biotinylated mouse monoclonal anti-human α -smooth muscle actin (30), rabbit anti-human desmin (31) (kind gifts from G. Gabbiani, University of Geneva, Geneva, Switzerland), and goat polyclonal anti-human vimentin (Sigma Immunochemicals, St. Louis, MO); for epithelial cells, rat monoclonal antipancytokeratin (Sigma Immunochemicals); for macrophages and T and B lymphocytes, rat monoclonal antibodies against macrophages (F4/80) and against mouse CD4 (GK1.5), anti-CD8 (H-35) T lymphocytes (American Type Culture Collection, Rockville, MD), and biotinylated anti-mouse Ig (Dako, Copenhagen, Denmark). Rabbit antibody anti-TGF- β synthetic peptides were a kind gift of Kathleen Flanders (National Cancer Institute, National Institutes of Health, Bethesda, MD) (32). Antibodies were detected by FITC-labeled goat anti-rat immunoglobulin or by biotinylated anti-rat IgG (Dako) followed by avidin peroxidase.

Platelet trapping assay. Platelets were prepared in citrate-glucose solution and labeled with ^{51}Cr as described (33). About 10^5 platelets (containing $\sim 10^5$ cpm) were injected intravenously; mice were killed 3 h later and radioactivity was measured in various organs.

Bacterial quantification. Lungs were isolated and homogenized in a sterile culture medium. Dilutions of the homogenates were added to bacteriological plates.

Data analysis. All statistical data are expressed as mean values \pm SD. One way ANOVA was performed using MicroCal ORIGIN 2.8 (MicroCal Software, Northampton, MA) for Microsoft Windows 3.1.

Results

Generation of transgenic mice. From 360 eggs injected with the SPC/TNF- α -pA DNA construct, which contains the mouse TNF- α gene without its 3' untranslated region, no transgenic

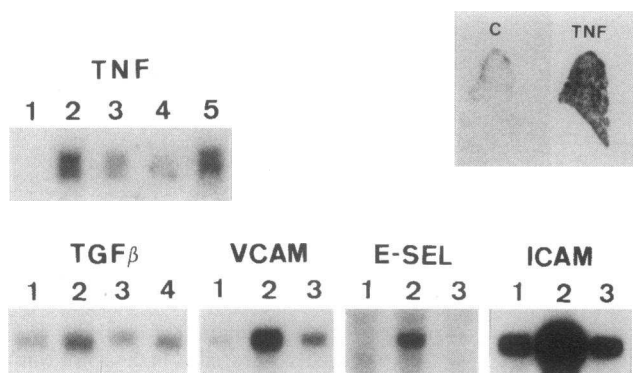


Figure 2. Northern blots and in situ hybridization of lung mRNAs. For Northern blotting, equal amounts of lung RNA were placed in each track, and the evenness of loading was judged by methylene blue staining of the filters showing the ribosomal RNA bands. TNF: lane 1, normal mouse; lanes 2–5, transgenic mice of the same age (see text); mice 2 and 5 had more severe lesions. TGF β : lanes 1 and 4, normal littermates; lanes 2 and 3, transgenic mice. VCAM, E-selectin (*E-SEL*), and ICAM: lane 1, normal littermates; lane 2, normal mice 2 h after LPS injection; lane 3, transgenic mice. In situ hybridization of sections of the whole lung are shown at top right: TNF, hybridization with a ^{33}P -labeled antisense TNF- α probe; C, TNF- α sense probe, with prolonged exposure in order to see lung outline.

mice were obtained. This suggested that expression of this construct results in lethality in utero. To further explore this possibility, an additional 90 eggs were injected and the foster mothers were killed on the 19th day of gestation. 5 dead fetuses were recovered together with 12 living fetuses, which were killed for DNA analysis; none of the living fetuses were transgenic, while the 5 dead fetuses bore the transgene.

From the 500 eggs injected with the SPC/TNF- α -UT DNA, which contains the entire 3'UT region of the TNF- α gene, 13 transgenic mice were obtained. One was dead at birth and two died within 24 h, with cyanosis and signs of respiratory distress. From the 10 transgenic mice which lived and had no early signs of disease, 2 failed to gain weight normally and displayed progressive respiratory symptoms, which led to their death at ~ 1 mo old. Eight mice developed normally and, after mating with normal mice, passed the transgene to offspring following Mendelian rules. Transgenic offspring of each of these lines were killed between 1 and 2 mo of age and their lungs were examined histologically. In each case, varying degrees of lymphocytic alveolitis were observed. Only 2 lines (Tg-2 and Tg-10), which by Southern blot analysis had ~ 10 copies each of the transgene (not shown), were kept by further breeding for more detailed examination of the progression of the disease. There were no consistent differences in the nature and severity of the lesions observed in these two lines (except for some variations within line Tg-2, as mentioned below), and the pathology of the transgenic mice will thus be considered together.

Expression of TNF- α mRNA in the lungs of transgenic mice. TNF- α mRNA was detected on Northern blots of lung RNAs in all transgenic mice examined (Fig. 2); using the same conditions of detection, TNF- α mRNA was not detected in other tissues tested (liver, spleen, heart, kidney, uterus, brain, large bowel, and lymph nodes, not shown). By in situ hybridization of slices of whole lung, TNF- α mRNA was found to be evenly

expressed (Fig. 2), in contrast to the nodular distribution observed previously in lungs of experimental silicosis using the same technique (10). On histologic sections, the main source of TNF- α mRNA appeared to be in alveolar cells, whose localization suggested that they were mainly type II epithelial cells, which is consistent with the pattern of expression of SP-C in the mouse. In advanced lesions, however, the possibility that some labeled cells were macrophages could not be ruled out (Fig. 3 d); this would presumably correspond to TNF- α mRNA of endogenous rather than transgenic origin. Since the severity of the lesions observed on histologic sections from line Tg-2 showed some variability, nine transgenic mice and their littermates were killed at 5 mo of age; the right lung was used for RNA extraction and the left lung for histologic analysis. Two of these mice had a level of TNF- α mRNA clearly higher than the others (Fig. 2), and they also had the most severe lung lesions. To assess whether the severity of the lung disease might be influenced by infection, bacterial cultures of lung extracts were performed, and yielded number of colonies per lung similar to those of control lungs; no bacteria were detected by Gram stains of lung sections and by electron microscopy (see below). It thus appeared that the variation observed in the Tg-2 line reflected variation in the level of transgene expression perhaps resulting from variable degree of methylation (34). Severity of disease in offspring from Tg-10 line was more consistent and correlated with the levels of TNF- α mRNA in the lung. At no stage of the disease was TNF- α detected in the blood by a biological assay. In general, mice were killed after 7 mo to avoid death from progressive respiratory failure.

Pulmonary lesions analyzed by histology, electron microscopy, and immunohistochemistry. The two mice that died within 24 h after birth showed very severe pulmonary hypoplasia with immature, dense alveolar tissue. The other two mice that died at 1 mo had very severe interstitial pneumonia with large areas of pulmonary consolidation, similar in severity to those described below in older mice. From the two transgenic lines chosen for extensive analysis, Tg-2 and Tg-10, 64 F1 mice were killed at various intervals between 2 and 6 mo of age. For the sake of clarity, average lesions at 2 and 6 mo will be described. In Tg-2 line offspring, variation in the severity of the disease resulted in lesions occasionally as severe at time of killing at 2 mo as those observed for other mice, killed at 6 mo, with a few mice dying from respiratory failure before this age.

At 2 mo of age, the lungs were usually macroscopically normal. Leukocytic alveolitis, usually more patchy than diffuse, was a constant finding, with lymphocytic infiltrates more prominent within the interlobular septa, around the extraalveolar small vessels, and under the pleura. Immunohistochemistry showed a majority of CD4 $^{+}$ lymphocytes, but CD8 $^{+}$ and B lymphocytes were also present. Macrophages (identified by staining with the F4/80 antibody) were not especially numerous; neutrophils were also observed, in variable numbers. The air spaces were occasionally lined by cuboid cells, which were identified by electron microscopy as type II pneumocytes. In cases fixed by tracheal instillation rather than by immersion, ruptures of some alveolar septa, resulting in an enlargement of the alveolar spaces, were observed (Fig. 4, a and b); this lesion was quantified by morphometric image analysis (Fig. 5). By electron microscopy, an additional observation was that of frequent endothelial swelling in the alveolar capillaries. The extent of fibrosis, as judged by

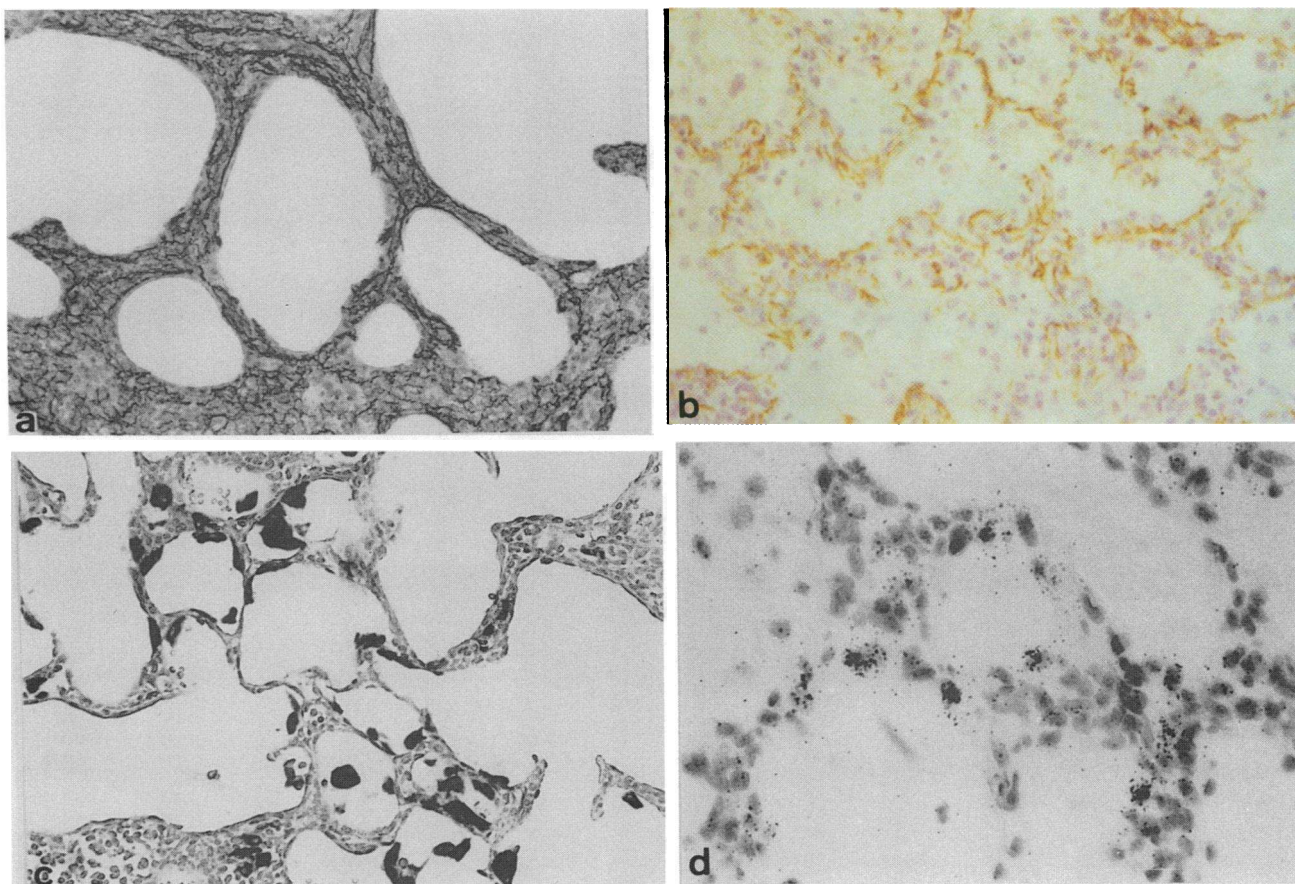
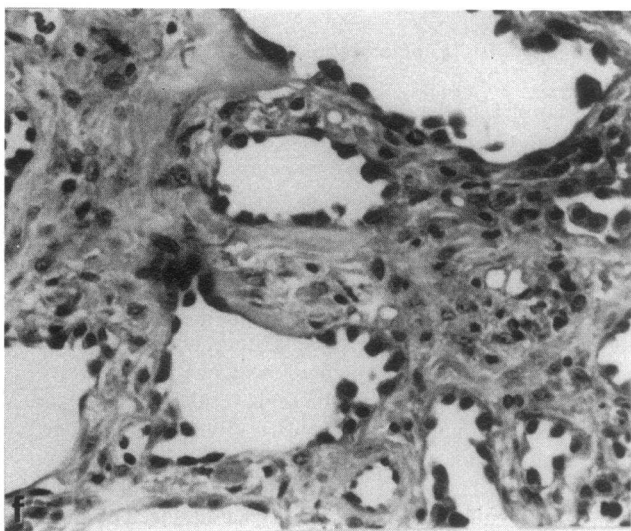
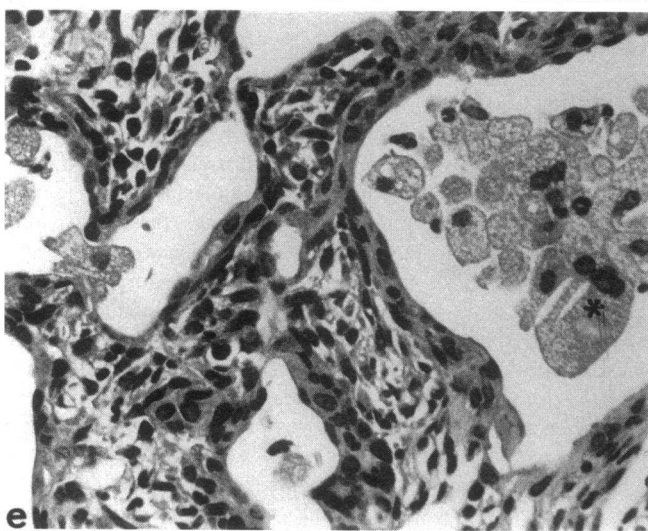
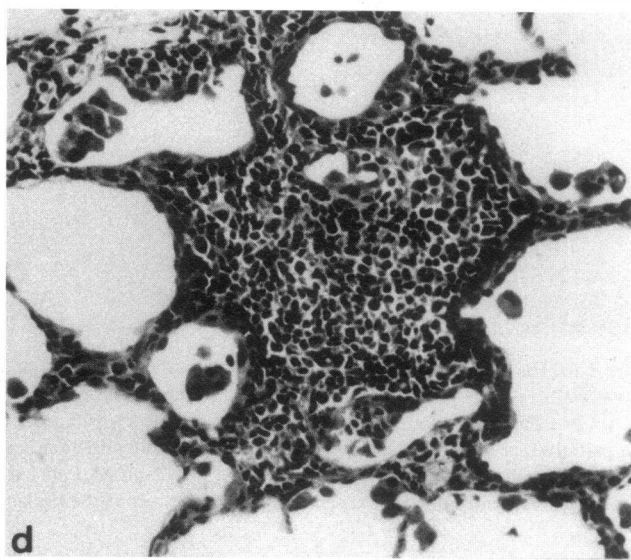
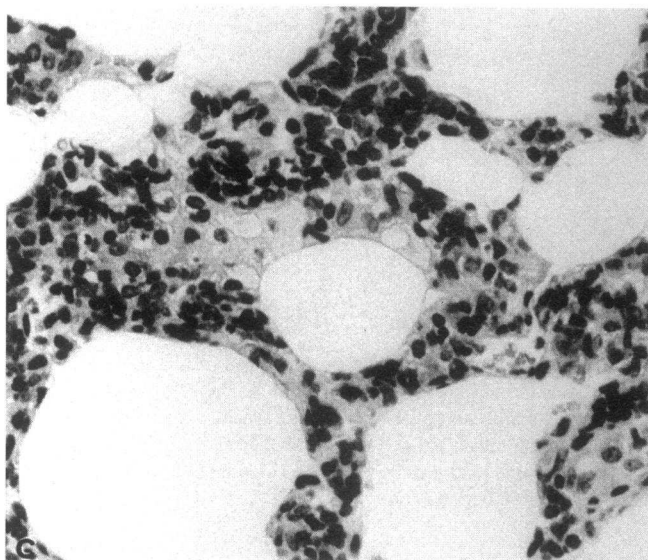
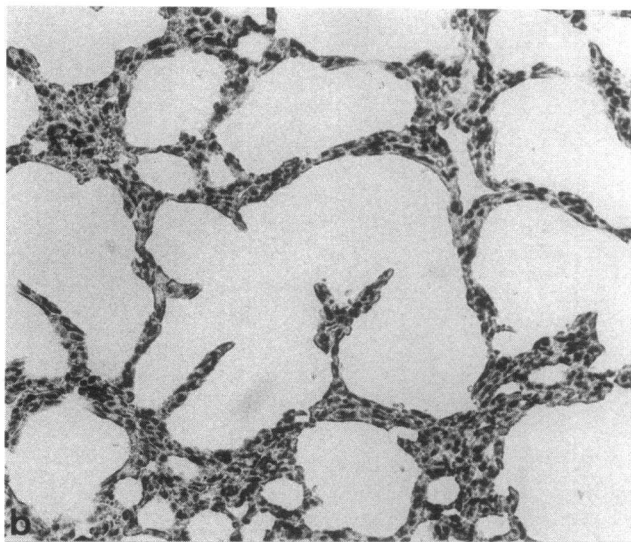
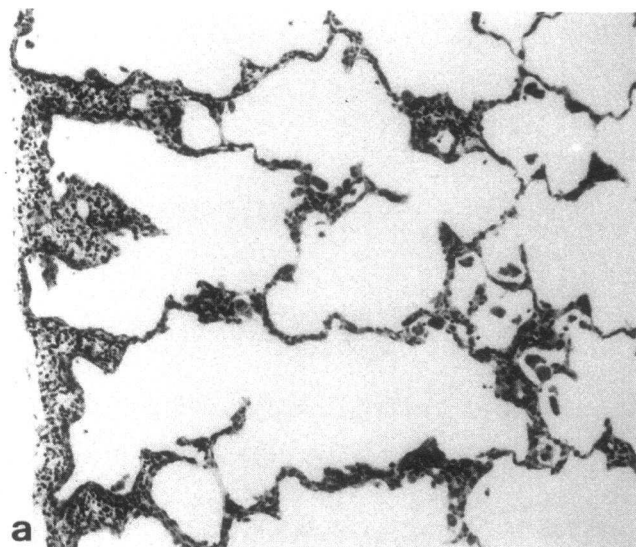


Figure 3. (a) Histologic section stained with Gomori's silver impregnation method, showing the extent of collagen deposition (black) in the thickened alveolar walls, $\times 100$. (b) Immunohistochemical staining for desmin, showing numerous desmin-positive fibroblasts in the thickened alveolar walls, $\times 80$. (c) Prussian blue staining showing, in black, cells laden with iron, either lining the alveolar space or in the air space. These cells appear to be in part alveolar macrophages, in part alveolar epithelial cells. Iron is also seen in some interstitial cells of the thickened alveolar walls, $\times 80$. (d) In situ hybridization with a ^{33}P -labeled TNF- α cRNA probe. Labeled cells are numerous, and their localization is compatible with that of pneumocytes. Hybridization with a sense probe showed very little background and no grain-bearing cell, $\times 250$.

silver staining of histologic sections, was usually minimal at this stage.

At 6 mo of age, the lungs did not collapse at the opening of the thorax and had an irregular, yellow surface. On histologic sections (Figs. 3 and 4), marked thickening of the alveolar septa with remodeling of the air space was widespread. Lymphocytic accumulation, sometimes associated with the presence of polymorphonuclear leukocytes and plasma cells, was in places still conspicuous (Fig. 4), but most commonly decreased or even absent. The respective contribution, in the distortion of lung histologic structures, of epithelial cells, fibroblasts, and macrophages could be best assessed by immunocytochemistry or electron microscopy. Thickening of the septa resulted in large part from an increased number of fibroblasts (Fig. 4 c), as judged by the extent of immunohistochemical staining for desmin (Fig. 3 b). These last cells, however, were not stained by anti-smooth muscle α -actin antibody, in contrast to what has been observed with the myofibroblasts of bleomycin-induced pneumopathy in rats (35). A marked fibrosis of the alveolar spaces was observed on silver-stained sections (Fig. 3 a), and, by electron microscopy, collagen fibrils accumulation was extensive (Fig. 6 c). To quantify the extent of fibrosis, hydroxyproline content was

determined in the lungs of 6-mo-old transgenic mice and of their normal littermates, demonstrating an approximate three-fold increase compared with controls (Fig. 7 a). The thickened alveolar septa were lined by type II epithelial cells (Fig. 4 e), which by electron microscopy (Fig. 6 a) usually appeared poor in lamellated bodies and with empty vacuoles, a change probably indicative of rapid regeneration. In places, these cells were stratified or desquamated in the alveolar lumen where they appeared as clusters of foam cells, sometimes with cholesterol crystals (Fig. 4 e). By histology, identification of the cells in the alveolar spaces as macrophages or type II epithelial cells was often difficult; immunofluorescent staining suggested that they were more frequently epithelial cells than macrophages, and on electron micrographs they were most often clearly identified as type II epithelial cells (Fig. 6 e). Altogether, these epithelial alterations suggested a rather extensive process of cell damage and regeneration among type II pneumocytes. Prussian blue, detecting iron, conspicuously stained some alveolar and interstitial macrophages and apparently some epithelial cells as well (Fig. 3 c), probably reflecting previous microhemorrhages which may have resulted from alveolar wall destruction. In general, the various pulmonary lesions observed in these



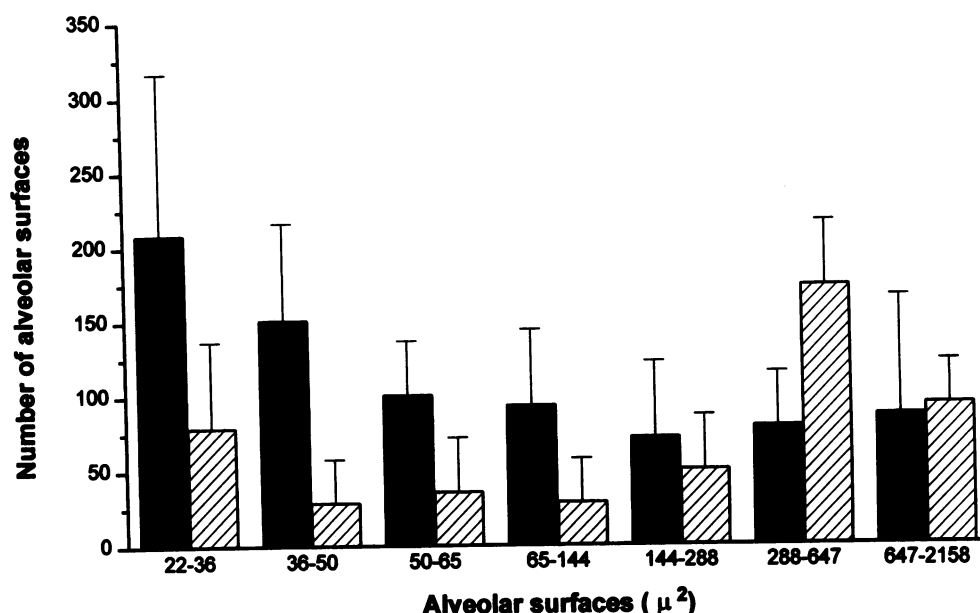


Figure 5. Morphometric analysis of the size distribution of air spaces seen on histologic sections of lungs of normal (black bars) or transgenic (hatched bars) mice. Results are mean of the value observed with five mice. Lungs of transgenic mice have fewer air spaces in the 22–144 μm^2 range, while the number of larger spaces is increased.

transgenic mice bore a marked resemblance to the variety of lesions observed in cases of idiopathic pulmonary fibrosis in humans (see for comparison Fig. 4 f).

Finally, a feature which could be observed only on ultrathin sections was that of vascular changes, consisting mostly of a thickening of the endothelial cytoplasm in the alveolar capillaries (Fig. 6 d). Platelets lining the capillary endothelium and platelet clumps were observed with unusual frequency. To assess potential platelet trapping in these lungs, ^{51}Cr -labeled platelets were injected into groups of transgenic mice and control littermates, demonstrating increased platelet trapping in the lungs of transgenic mice (Fig. 7 b).

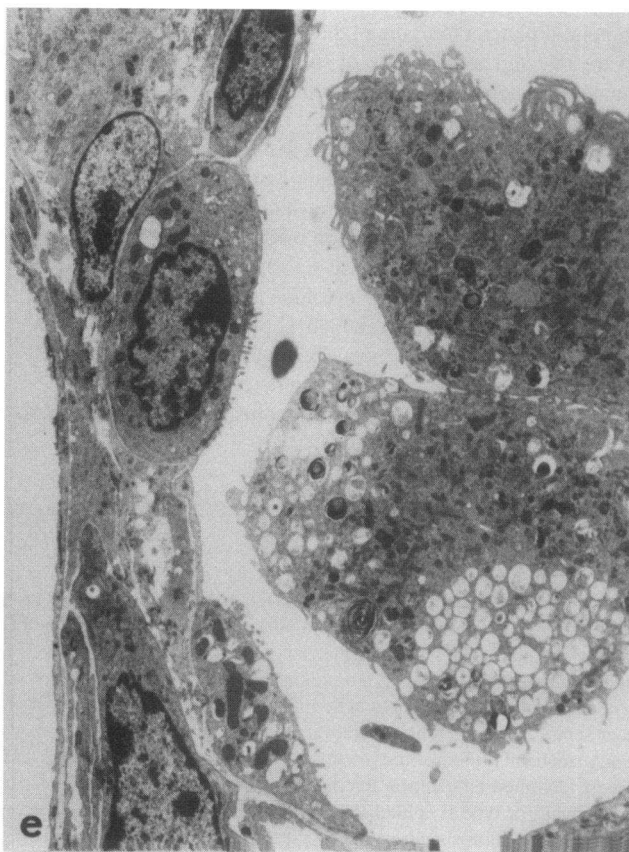
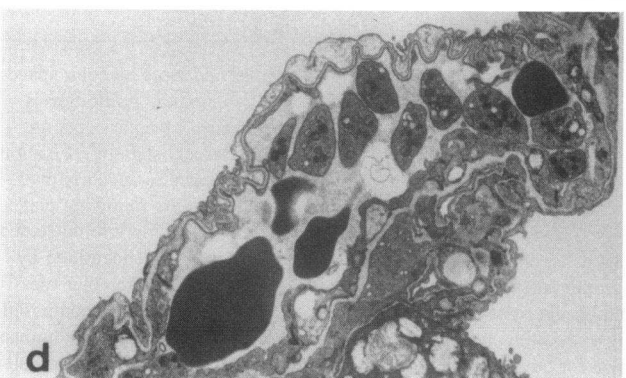
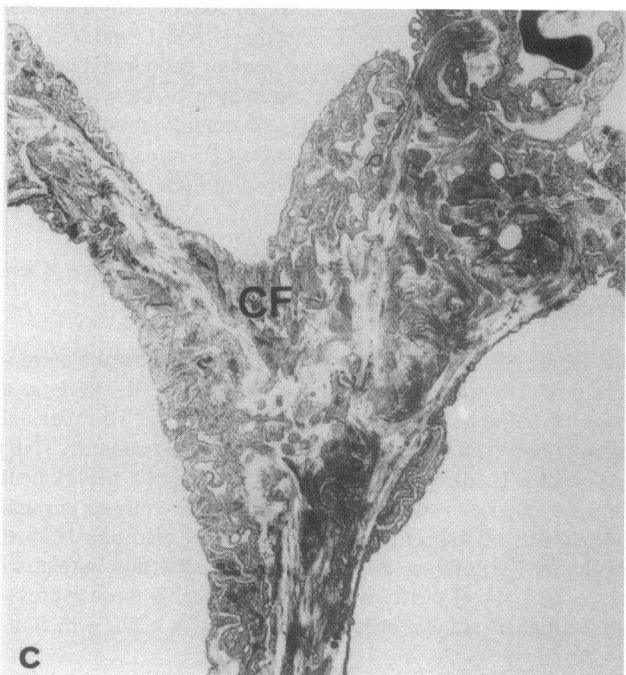
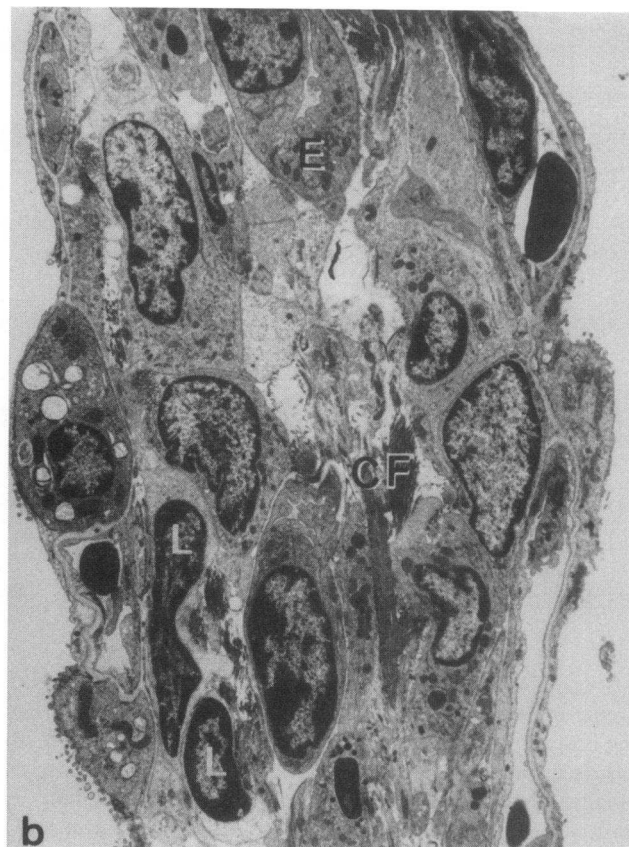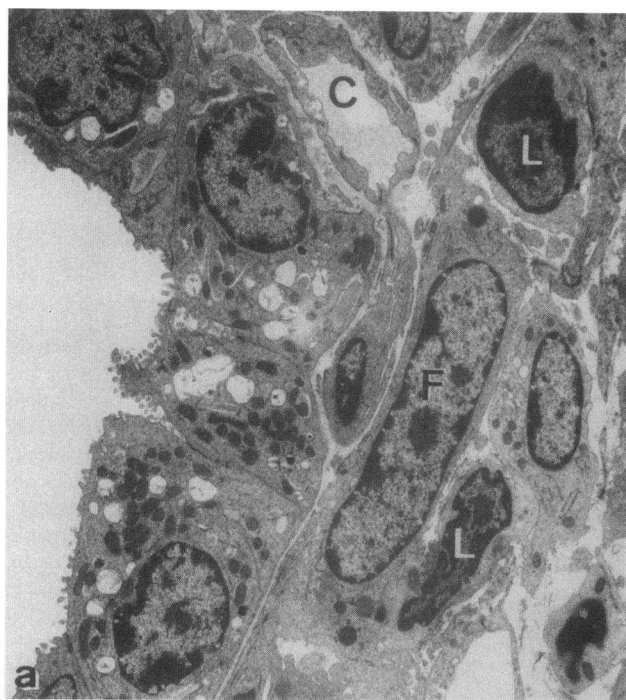Expression of mRNAs for cytokines and adhesion molecules in the diseased lungs. RNA from lungs of transgenic mice and littermates killed at 5–6 mo were studied by Northern blot analysis to determine the levels of mRNAs for interleukin-1, TGF- α , TGF- β 1, GM-CSF, and c-sis PDGF-B. No significant changes were observed in these cytokine mRNAs; lack of accumulation of TGF- β mRNA (which showed slight variations between controls as well as between transgenic mice, see Fig. 2) was in agreement with the failure to detect significant deposits or accumulation of TGF- β by immunohistochemistry, except

in occasional macrophages (Fig. 8). In RNAs from the same lungs, levels of mRNAs for E-selectin, ICAM-1, and VCAM-1 were assessed, since exposure of venular endothelial cells to TNF- α is known to induce the expression of these adhesion molecules (36); RNAs from lungs of control littermates and from the lungs of normal mice 2 h after LPS injection (a condition which markedly increases the level of these mRNAs) were used for comparison. Only VCAM mRNA was found to be increased in the transgenic mice (Fig. 2).

Discussion

The mouse SP-C-TNF- α transgenic lines show that the permanent production of TNF- α by type II pneumocytes leads to a range of pulmonary lesions of varying severity. The prenatal lethality observed with a transgene not including an intact TNF- α 3' untranslated region (37) is likely to reflect a requirement for this sequence to control the level of TNF- α synthesis through mechanisms of transcriptional and probably also translational regulation (38). When the transgene included this regulatory sequence, some of the transgenic mice, probably those expressing the highest amount of lung TNF- α , died at birth, with com-

Figure 4. Histologic sections of lungs at various stages of pulmonary disease. Hematoxylin and eosin stain. (a) Irregular and large alveolar spaces probably resulting from ruptures of alveolar septa (morphometric analysis of this type of lesion is shown in Fig. 5). Lymphocytic infiltration is most conspicuous in the sub-pleural region (left border of the field). Fixation by tracheal instillation, $\times 40$. (b) The thickened alveolar septa are hypercellular and infiltrated mostly by lymphocytes (in majority CD4 and CD8 T lymphocytes, as detected by immunofluorescent staining). Fixation by tracheal instillation, $\times 80$. (c) Higher magnification ($\times 200$) of the rather heterogeneous cell infiltrate of the interalveolar walls, which is made of lymphocytes and of some polymorphonuclear leukocytes, detected by their convoluted nuclei. Fixation by immersion, as in the following plates. (d) A nodular perivascular lymphocytic infiltration (with some degree of apoptosis) is seen at the center, with lymphocytes extending into thickened adjacent septa, $\times 160$. (e) The severely thickened alveolar walls contain various cells, among which fibroblasts are a majority (best identified by immunohistochemistry detecting intracytoplasmic desmin, see Fig. 3 b). The grossly altered alveolar space is lined by hyperplastic alveolar type II cells (best identified by electron microscopy, see Fig. 6 a). The alveolar lumen on the right of the picture contains a cellular aggregate composed of macrophages or type II epithelial cells (see ultrastructural appearance on Fig. 6 e), with cholesterol crystals (*), $\times 250$. (f) Histology of a human case of pulmonary fibrosis, classified as "Usual Interstitial Pneumonitis," shown for comparison, $\times 250$; the severe thickening of the alveolar walls also results mostly from fibroblast accumulation, and the alveoli are lined with cuboidal epithelial cells.



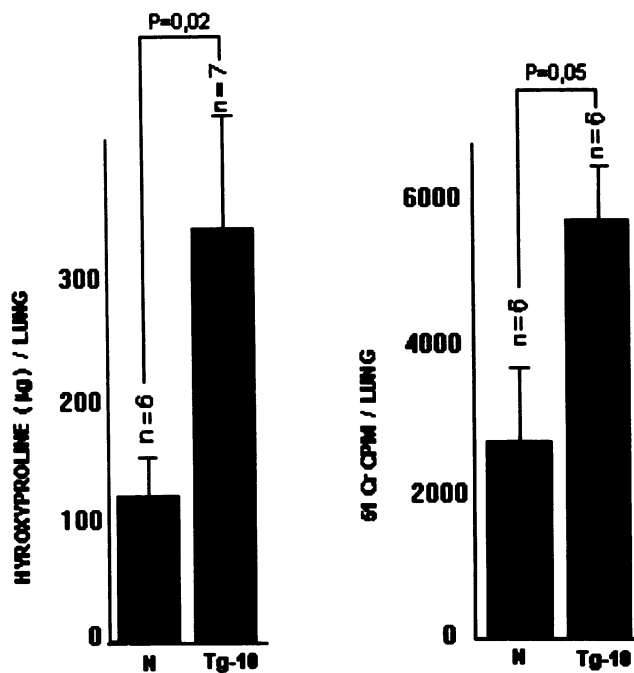


Figure 7. Determination of hydroxyproline content (left) and of platelet trapping after injection of ⁵¹Cr-labeled platelets (right), using lungs of matched normal and transgenic mice.

plex pulmonary lesions indicative of abnormal lung development. In all other mice bearing the transgene, pulmonary disease was observed, whose difference in rapidity of evolution, ranging from death within a few weeks from birth to progression through over 6 mo, appeared to correlate well with the transgene expression, as judged by lung TNF- α mRNA levels.

The first conspicuous lesion was leukocytic alveolitis; the dominant cells were lymphocytes, mostly of the T lineage, although neutrophils and monocytes were also present. This lesion is likely to result from endothelial changes known to be induced by TNF- α , in particular from the expression by endothelial cells of cell adhesion molecules instrumental in leukocyte local infiltration (36). A progressive local lymphocytic infiltration has also been observed in mice bearing a TNF- α transgene placed under the control of an insulin promoter; this resulted in massive insulinitis, apparently secondary to venular endothelial changes in the pancreatic islets (39). In the SP-C-TNF- α transgenic mice, the increased lung expression of VCAM-1 mRNA, in the absence of variations in E-selectin or ICAM-1 mRNAs, suggests that VCAM-1, which acts as a ligand for the integrin VLA-4 borne by T lymphocytes, may play a role in alveolitis. It is

unlikely that the lymphocytic infiltration, which did not show signs of lymphocyte activation as judged by electron microscopy, played a significant role in subsequent alterations of the alveolar walls, in particular fibrosis. In the TNF- α transgenic mice with pancreatic insulinitis, some degree of islet sclerosis was also observed, and it was clearly independent from lymphocytic infiltration, since it was of the same intensity when the transgene was expressed in scid mice, which have neither T nor B lymphocytes and displayed little leukocytic insulinitis (39). It is nevertheless clear that, in the presence of stimulating local antigens, lymphocyte activation can play an important role in the evolution of lesions; for instance, in transgenic mice with TNF- α -induced insulinitis, local expression of the T lymphocyte costimulating molecule B7 (directed by a second transgene) led to lymphocyte activation, which resulted in islet beta cell destruction and lethal diabetes (40). It is reasonable to think that lymphocytic alveolitis accompanied by local immune lymphocytic stimulation, as appears to be present in a number of human interstitial alveolitis, may, similarly, lead to more rapidly progressive pulmonary damage. Neutrophils may also be involved in the progressive alveolar damage observed in the SP-C TNF- α transgenic mice; while these cells were less conspicuous than lymphocytes in the leukocytic infiltrates, their shorter life span might account for their lack of accumulation. Septal ruptures compatible with polymorphonuclear elastase release were observed in early lesions (Fig. 4, a and b); the iron deposits found in such lesions (Fig. 3 c) probably resulted from focal alveolar hemorrhages.

Two features indicated progressive epithelial damage. One was the hyperplasia of type II alveolar epithelial cells, often conspicuous in the lining of the distorted alveolar or residual air spaces, a finding very suggestive of epithelial regeneration. Another conspicuous lesion was intraalveolar epithelial desquamation, taking usually the appearance of intraalveolar aggregates of foamy cells, sometimes containing cholesterol crystals (Fig. 4 e). While it is possible that alveolar macrophages also contributed to this lesion, its ultrastructural appearance, with lamellar bodies and focal intercellular adherence areas, indicated that it was most often made of epithelial cells.

Progressive accumulation of fibroblasts in the alveolar wall could be best evaluated by immunohistochemical staining for desmin, since pulmonary fibroblasts are characterized by their high desmin content (41). Fibroblasts were obviously responsible for the deposition of collagen and progressive destruction of alveolar structures which culminated in extensive fibrosis. While TNF- α has been observed to induce fibroblast proliferation in vitro (42) and in vivo (6), other cytokines may be indirectly involved. TGF- β or PDGF-B has been incriminated as playing an important role in human or experimental pulmonary

Figure 6. Electron micrographs of pulmonary alveolar wall lesions observed in the lungs of 4–6-mo-old mice. (a) The alveolar space on the left is lined by regenerating type II alveolar cells. In the thickened septum, two lymphocytes (L), large interstitial cells, probably fibroblastic (F), and a distorted capillary (C) with swollen endothelium are seen. (b) A thickened alveolar wall contains lymphocytes (L) and interstitial cells, not clearly identifiable, an accumulation of collagen fibrils (CF), swollen endothelial cell probably of a neo-capillary (E) not yet surrounded by a well-formed basement membrane, and several distorted capillaries containing red blood cells. (c) A severely damaged junction of alveolar spaces with folded basal lamina suggestive of prior alveolar collapses. A dense accumulation of collagen fibrils (CF) is seen toward the center of the junction. (d) An interalveolar capillary with a folded basement membrane contains a small platelet clump together with red blood cells. (e) The alveolar space on the right of the picture, lined on its left border by alveolar type II cells, contains two desquamated large alveolar cells, which correspond to the type of cells seen on Fig. 4 c.

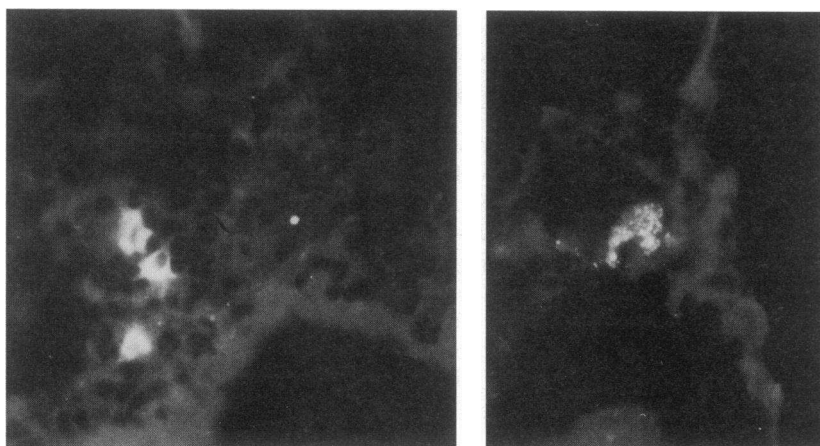


Figure 8. Immunofluorescent staining of diseased lung for TGF- β . On the left, three labeled cells, probably macrophages, are seen in a very thickened alveolar wall, $\times 80$; such a concentration of TGF- β -containing cells is not representative. On the right, an alveolar macrophage contains TGF- β , $\times 250$.

diseases (2–5, 43). In the SP-C-TNF- α transgenic mice, no significant increase in lung levels of TGF- β and PDGF-B mRNAs was observed at various stages of the lesions, and the only accumulation of TGF- β detected by immunochemistry was in isolated macrophages (Fig. 8); activated alveolar macrophages are known to synthesize TGF- α (44). It cannot be concluded, however, that these cytokines were not involved in pulmonary fibrosis. Clumps of blood platelets, a major source of both of these cytokines, were commonly detected by electron microscopy in altered alveolar capillaries, and enhanced platelet trapping in the lung was observed after transfer of labeled platelets. This may have resulted from a combination of endothelial alterations and enhanced expression of platelet adhesion molecules induced by the local presence of TNF- α (45, 46). Experimental evidence suggests that increased platelet trapping in the lung is correlated with the development of other forms of lung fibrosis in which TNF- α is involved (46). It must be emphasized that prolonged release of “latent” TGF- β in the lung is not necessarily harmful; we have generated several mouse SP-C-TGF- β transgenic lines in which the latent uncleaved form of TGF- β is released in the lung without generating lesions (Miyazaki, Y., J. Whitsett, P.-F. Piguet, and P. Vassalli, unpublished observations), suggesting that local additional production of proteolytic enzymes able to process this cytokine in its active form is essential for the induction of lesions.

The most striking conclusion resulting from the study of the SP-C-TNF- α transgenic mice is that of the resemblance of all steps of this progressive lung disease with those of idiopathic pulmonary fibrosis or “fibrosing alveolitis” in humans, a disease of unknown etiology and pathogenesis. It is thus of special interest to note that the presence of TNF- α mRNA and protein has been detected recently in alveolar epithelial cells, mainly type II pneumocytes, in this last disease (7, 8). While the pathogenic mechanisms responsible for TNF- α overexpression by alveolar epithelial cells in human pulmonary fibrosis are not understood, the present findings with mice similarly overexpressing TNF- α in this localization suggest that this functional disturbance may represent an initial event from which all subsequent lung pathology, including leukocytic infiltration and progressive fibrosis, might result. In this respect, the SP-C-TNF- α transgenic mice represent an excellent experimental model of pulmonary fibrosis, in particular to explore a variety of therapeutic approaches, directed at neutralizing the effects of TNF-

α or at decreasing its synthesis (47), or at preventing collagen accumulation.

Acknowledgments

We want to thank Ms. J. Ntah for secretarial work, Mr. J.-C. Rumbeli and Mr. E. Denking for photographic work, and Pedro Herrera for performing the immunofluorescent staining for TGF- β .

This work was supported by grants from the Swiss National Foundation (31–37516.93) and by the Cystic Fibrosis Foundation (HL 51838), Center for Gene Therapy.

References

- Colby, T. V., and A. C. Churg. 1986. Patterns of pulmonary fibrosis. *Pathol. Annu.* 21:277–309.
- Martinet, Y., W. N. Rom, G. R. Grotendorst, G. R. Martin, and R. G. Crystal. 1987. Exaggerated spontaneous release of platelet-derived growth factor by alveolar macrophages from patients with idiopathic pulmonary fibrosis. *N. Engl. J. Med.* 317:202–209.
- Antoniades, H. N., M. A. Bravo, R. E. Avila, T. Galanopoulos, J. Neville-Golden, M. Maxwell, and M. Selman. 1990. Platelet-derived growth factor in idiopathic pulmonary fibrosis. *J. Clin. Invest.* 86:1055–1064.
- Vignaud, J. M., M. Allam, N. Martinet, M. Pech, F. Plenat, and Y. Martinet. 1991. Presence of platelet-derived growth factor in normal and fibrotic lung is specifically associated with interstitial macrophages, while both interstitial macrophages and alveolar epithelial cells express the c-sis proto-oncogene. *Am. J. Respir. Cell Mol. Biol.* 5:531–538.
- Khalil, N., R. N. O'Connor, H. W. Unruh, P. W. Warren, K. C. Flanders, A. Kemp, O. H. Berezney, and A. H. Greenberg. 1991. Increased production and immunohistochemical localization of transforming growth factor- β in idiopathic pulmonary fibrosis. *Am. J. Respir. Cell Mol. Biol.* 5:155–162.
- Piguet, P. F., G. E. Grau, and P. Vassalli. 1990. Subcutaneous perfusion of tumor necrosis factor induces local proliferation of fibroblasts, capillaries, and epidermal cells, or massive tissue necrosis. *Am. J. Pathol.* 136:103–110.
- Piguet, P. F., C. Ribaux, V. Karpuz, G. E. Grau, and Y. Kapanci. 1993. Expression and localization of tumor necrosis factor- α and its mRNA in idiopathic pulmonary fibrosis. *Am. J. Pathol.* 143:651–655.
- Nash, J. R. G., P. J. McLaughlin, D. Butcher, and B. Corrin. 1993. Expression of tumour necrosis factor- α in cryptogenic fibrosing alveolitis. *Histopathology.* 22:343–347.
- Piguet, P. F., M. A. Collart, G. E. Grau, Y. Kapanci, and P. Vassalli. 1989. Tumor necrosis factor cachectin plays a key role in bleomycin-induced pneumopathy and fibrosis. *J. Exp. Med.* 170:655–663.
- Piguet, P. F., M. A. Collart, G. E. Grau, A. P. Sappino, and P. Vassalli. 1990. Requirement of tumor necrosis factor for development of silica-induced pulmonary fibrosis. *Nature (Lond.)* 344:245–247.
- Piguet, P. F., and C. Vesin. 1994. Treatment by human recombinant soluble TNF receptor of pulmonary fibrosis induced by bleomycin or silica in mice. *Eur. Respir. J.* 7:515–518.
- Nelson, S., G. J. Bagby, B. G. Bainton, L. A. Wilson, J. J. Thompson, and W. R. Summer. 1989. Compartmentalization of intraalveolar and systemic

- lipopolysaccharide-induced tumor necrosis factor and the pulmonary inflammatory response. *J. Infect. Dis.* 159:189–194.
13. Johansson, J., T. Curstedt, and B. Robertson. 1994. The proteins of the surfactant system. *Eur. Respir. J.* 7:372–391.
14. Korfhagen, T. R., S. W. Glasser, S. E. Wert, M. D. Bruno, C. C. Daugherty, J. D. McNeish, J. L. Stock, S. S. Potter, and J. A. Whitsett. 1990. Cis-acting sequences from a human surfactant protein gene confer pulmonary-specific gene expression in transgenic mice. *Proc. Natl. Acad. Sci. USA.* 87:6122–6126.
15. Glasser, S. W., T. R. Korfhagen, C. M. Perme, T. J. Pilot-Matias, S. E. Kister, and J. A. Whitsett. 1988. Two SP-C genes encoding human pulmonary surfactant proteolipid. *J. Biol. Chem.* 263:10326–10331.
16. Semon, D., E. Kawashima, C. V. Jongeneel, A. N. Shakhov, and S. A. Nedospasov. 1987. Nucleotide sequence of the murine TNF locus, including the TNF- α (tumor necrosis factor) and TNF- β (lymphotoxin) genes. *Nucleic Acids Res.* 15:9083–9084.
17. Niwa, H., K. I. Yamamura, and J. I. Miyazaki. 1991. Efficient selection for high-expression transfectants with a novel eukaryotic vector. *Gene (Amst.)* 108:193–200.
18. Collart, M. A., D. Belin, J. D. Vassalli, S. de Kossodo, and P. Vassalli. 1986. Gamma interferon enhances macrophage transcription of the tumor necrosis factor/cachectin, interleukin-1, and urokinase genes which are controlled by short lived repressor. *J. Exp. Med.* 163:2113–2118.
19. Thorens, B., J. J. Mermoud, and P. Vassalli. 1987. Phagocytosis and inflammatory stimuli induce GM-CSF mRNA in macrophages through posttranscriptional regulation. *Cell.* 48:671–679.
20. Wong-Staal, F., R. Dalla Favera, E. P. Gelmann, V. Manzari, S. Szala, S. F. Josephs, and R. C. Gallo. 1994. The v-sis transforming gene of simian sarcoma virus is a new oncogene of primate origin. *Nature (Lond.)* 294:273–275.
21. Derynck, R. 1986. Transforming growth factor- α : structure and biological activities. *J. Cell. Biochem.* 32:293–304.
22. Derynck, R., J. A. Jarrett, E. Y. Chen, and D. V. Goeddel. 1986. The murine transforming growth factor- β precursor. *J. Biol. Chem.* 261:4377–4379.
23. Becker-Andre, M., R. H. Van Huijsduijn, C. Losberger, J. Whelan, and J. F. DeLamarter. 1992. Murine endothelial leukocyte-adhesion molecule 1 is a close structural and functional homologue of the human protein. *Eur. J. Biochem.* 206:401–411.
24. Janssen, Y. M. W., B. Van Houten, P. J. A. Borm, and B. T. Mossman. 1993. Biology of disease. Cell and tissue responses to oxidative damage. *Lab. Invest.* 69:261–274.
25. Horley, K. J., C. Carpenito, B. Baker, and F. Takei. 1989. Molecular cloning of murine intercellular adhesion molecule (ICAM-1). *EMBO (Eur. Mol. Biol. Organ.) J.* 8:2889–2896.
26. Pardue, M. L. 1994. In situ hybridization. In *Nucleic Acid Hybridization: A Practical Approach*. B. D. Hames and S. J. Higgins, editors. IRL Press, Oxford. 179–202.
27. Sappino, A. P., J. Huarte, D. Belin, and J. D. Vassalli. 1989. Plasminogen activators in tissue remodeling and invasion. Messenger RNA localization in mouse ovaries and implanting embryos. *J. Cell Biol.* 109:2471–2479.
28. Thrall, R. S., J. R. McCormick, R. M. Jack, R. A. McReynolds, and P. A. Ward. 1979. Bleomycin-induced pulmonary fibrosis in the rat. *Am. J. Pathol.* 95:117–127.
29. Ganter, P., and G. Jollès. 1969. *Histochemie Normale et Pathologique*. Gauthier-Villars, Paris. 1632–1633.
30. Skalli, O., P. Ropraz, A. Trzeciak, G. Benzonana, D. Gillessen, and G. Gabbiani. 1986. A monoclonal antibody against α -smooth muscle actin. A new probe for smooth muscle differentiation. *J. Cell Biol.* 103:2787–2796.
31. Kapanci, Y., C. Ribaux, C. Chaponniere, and G. Gabbiani. 1992. Cytoskeletal features of alveolar myofibroblasts and pericytes in normal human and rat lungs. *J. Histochem. Cytochem.* 40:1955–1963.
32. Flanders, K. C., N. L. Thompson, D. S. Cissel, E. Van Obberghen-Schilling, C. C. Baker, M. E. Kass, L. R. Ellingsworth, A. B. Roberts, and M. B. Sporn. 1989. Transforming growth factor- β 1: histochemical localization with antibodies to different epitopes. *J. Cell Biol.* 108:653–660.
33. ICHS Panel. 1988. Recommended method for Indium-111 platelet survival. *J. Nucl. Med.* 29:564–566.
34. Araki, K., K. Akagi, J. Miyazaki, K. Matsubara, and K. Yamamura. 1990. Correlation of tissue-specific methylation with gene inactivity in hepatitis B virus transgenic mice. *Jpn. J. Cancer Res.* 81:1265–1271.
35. Vyalov, S. L., G. Gabbiani, and Y. Kapanci. 1993. Rat alveolar myofibroblasts acquire α -smooth muscle actin expression during bleomycin-induced pulmonary fibrosis. *Am. J. Pathol.* 143:1754–1765.
36. Bevilacqua, M. P. 1993. Endothelial-leukocyte adhesion molecules. *Annu. Rev. Immunol.* 11:767–804.
37. Keffer, J., L. Probert, H. Cazaris, S. Georgopoulos, E. Kaslaris, D. Kioussis, and G. Kollias. 1991. Transgenic mice expressing human tumor necrosis factor: a predictive genetic model of arthritis. *EMBO (Eur. Mol. Biol. Organ.) J.* 10:4025–4031.
38. Kruijs, V., K. Kemmer, A. Shakhov, V. Jongeneel, and B. Beutler. 1992. Constitutive activity of the tumor necrosis factor promoter is canceled by the 3' untranslated region in nonmacrophage cell lines; a trans-dominant factor overcomes this suppressive effect. *Proc. Natl. Acad. Sci. USA.* 89:673–677.
39. Higuchi, Y., P. Herrera, P. Muniesa, J. Huarte, D. Belin, P. Ohashi, P. Aichele, L. Orci, J. D. Vassalli, and P. Vassalli. 1992. Expression of a tumor necrosis factor α transgene in murine pancreatic β cells results in severe and permanent insulinitis without evolution towards diabetes. *J. Exp. Med.* 176:1719–1731.
40. Herrera, P. L., D. M. Harlan, L. Fossati, S. Izui, J. Huarte, L. Orci, J. D. Vassalli, and P. Vassalli. 1994. A CD8⁺ T-lymphocyte-mediated and CD4⁺ T-lymphocyte-independent autoimmune diabetes of early onset in transgenic mice. *Diabetologia.* 37:1277–1279.
41. Zhang, K., M. D. Reikter, D. Gordon, and S. H. Phan. 1994. Myofibroblasts and their role in lung collagen gene expression during pulmonary fibrosis. *Am. J. Pathol.* 145:114–125.
42. Sugarman, B. J., B. B. Aggarwal, P. E. Hass, I. S. Figari, M. A. Palladino, and M. H. Shepard. 1985. Recombinant human tumor necrosis factor- α : effects on proliferation of normal and transformed cells in vitro. *Science (Wash. DC)* 230:943–945.
43. Broekelmann, T., A. H. Limper, T. V. Colby, and J. A. McDonald. 1991. Transforming growth factor β 1 is present at sites of extracellular matrix gene expression in human pulmonary fibrosis. *Proc. Natl. Acad. Sci. USA.* 88:6642–6646.
44. Madtes, D. K., E. W. Raines, K. S. Sakariassen, R. K. Assoian, M. B. Sporn, G. I. Bell, and R. Ross. 1988. Induction of transforming growth factor- α in activated human alveolar macrophages. *Cell.* 53:285–293.
45. Piguet, P. F., C. Vesin, J. E. Ryser, G. Senaldi, G. E. Grau, and F. Tacchini-Cottier. 1993. An effector role for platelets in systemic and local lipopolysaccharide-induced toxicity in mice, mediated by a CD11a- and CD54-dependent interaction with endothelium. *Infect. Immun.* 61:4182–4187.
46. Piguet, P. F., and C. Vesin. 1994. Pulmonary platelet trapping induced by bleomycin: correlation with fibrosis and involvement of the β 2 integrins. *Int. J. Exp. Pathol.* 75:321–328.
47. Lee, J. C., J. T. Laydon, P. C. McDonnell, T. F. Gallagher, S. Kumar, D. Green, D. McNulty, M. J. Blumenthal, J. R. Heys, S. W. Landvatter, et al. 1994. A protein kinase involved in the regulation of inflammatory cytokine biosynthesis. *Nature (Lond.)* 372:739–746.