

Hepatitis C virus (HCV) genotype, tissue HCV antigens, hepatocellular expression of HLA-A,B,C, and intercellular adhesion-1 molecules. Clues to pathogenesis of hepatocellular damage and response to interferon treatment in patients with chronic hepatitis C.

G Ballardini, ... , A Alberti, F B Bianchi

J Clin Invest. 1995;**95**(5):2067-2075. <https://doi.org/10.1172/JCI117893>.

Research Article

To obtain information on the mechanisms of hepatocellular damage and the determinants of response to interferon, hepatitis C virus (HCV) genotype, tissue HCV antigens, hepatocellular expression of HLA-A,B,C and intercellular adhesion-1 molecules, and the number of lobular T lymphocytes were studied in 38 anti-HCV-positive patients. 14 patients did not show a primary response to interferon treatment. HCV genotype 1b was detected in 11 of them. They displayed higher scores of HCV-positive hepatocytes, HLA-A,B,C, and ICAM-1 molecules expression than with the responders. HCV-infected hepatocytes maintained the capacity to express HLA-A,B,C and ICAM-1 molecules. CD8-positive T cells in contact with infected hepatocytes and Councilman-like bodies were observed. A significant correlation was found between the number of lobular CD8-positive T cells and alanine amino transferase levels. No differences were observed in clinical, biochemical, and histological features between patients with high and low number of hepatocytes containing HCV antigens. These data suggest a prominent role of T cell-mediated cytotoxicity in the genesis of hepatocellular damage. The high expression of interferon-inducible antigens like HLA-A,B,C molecules suggests the presence of strong activation of the interferon system possibly related to high HCV replication in nonresponder patients infected with genotype 1b.

Find the latest version:

<https://jci.me/117893/pdf>



Hepatitis C Virus (HCV) Genotype, Tissue HCV Antigens, Hepatocellular Expression of HLA-A,B,C, and Intercellular Adhesion-1 Molecules

Clues to Pathogenesis of Hepatocellular Damage and Response to Interferon Treatment in Patients with Chronic Hepatitis C

Giorgio Ballardini, Paolo Groff, Patrizia Pontisso,* Fabrizio Giostra, Raffaella Francesconi, Marco Lenzi, Daniela Zauli, Alfredo Alberti,* and Francesco B. Bianchi

*Semeiotica Medica II, Policlinico S. Orsola, University of Bologna, 40138 Bologna; and *Clinica Medica II, University of Padova, 35100 Padova, Italy*

Abstract

To obtain information on the mechanisms of hepatocellular damage and the determinants of response to interferon, hepatitis C virus (HCV) genotype, tissue HCV antigens, hepatocellular expression of HLA-A,B,C and intercellular adhesion-1 molecules, and the number of lobular T lymphocytes were studied in 38 anti-HCV-positive patients. 14 patients did not show a primary response to interferon treatment. HCV genotype 1b was detected in 11 of them. They displayed higher scores of HCV-positive hepatocytes, HLA-A,B,C, and ICAM-1 molecules expression than with the responders. HCV-infected hepatocytes maintained the capacity to express HLA-A,B,C and ICAM-1 molecules. CD8-positive T cells in contact with infected hepatocytes and Councilman-like bodies were observed. A significant correlation was found between the number of lobular CD8-positive T cells and alanine amino transferase levels. No differences were observed in clinical, biochemical, and histological features between patients with high and low number of hepatocytes containing HCV antigens. These data suggest a prominent role of T cell-mediated cytotoxicity in the genesis of hepatocellular damage. The high expression of interferon-inducible antigens like HLA-A,B,C molecules suggests the presence of strong activation of the interferon system possibly related to high HCV replication in nonresponder patients infected with genotype 1b. (*J. Clin. Invest.* 1995. 95:2067–2075.) Key words: immunology • adhesion molecules • cytotoxicity immunologic • treatment outcome • viral antigens

Introduction

The mechanisms of hepatocellular damage and the biological determinants of response to interferon treatment in chronic liver

disease due to hepatitis C virus (HCV)¹ are still under investigation. Increasing evidence for T cell-mediated damage has been supplied by in vitro studies (1–3).

It is presently accepted that primary response to α -interferon (α -IFN) is achieved in approximately half the patients with HCV-related chronic hepatitis (4, 5). Young age, short disease duration, and absence of cirrhosis are said to increase the chances of a positive response (6, 7). Recent data suggest that the response to treatment is more frequent in patients infected by particular HCV genotypes (8–11), with a lower viremia (12–14), and a lower number of HCV-positive hepatocytes in liver tissue (15).

Recent observations from our group suggest that patients not responding to interferon display a greater amount of HLA-A,B,C molecules on hepatocytes than responder cases (16), possibly as a consequence of a higher activation of the endogenous interferon system, induced by viral infection and replication. In fact, it is known that this event induces interferon production which in turn stimulates the synthesis of a number of molecules, including MHC molecules (17–19).

Recognition and elimination of infected cells by cytotoxic T cells require the expression of relevant HCV antigens on the membrane of hepatocytes in the context of HLA-A,B,C antigens. Coexpression of adhesion molecules, such as intercellular adhesion-1 molecules (ICAM-1), is necessary to obtain firm hepatocyte–T cell contacts.

The aim of the present study was to obtain information on both the mechanisms of liver damage and the determinants of response to interferon.

For this purpose a study was planned combining the evaluation of virological (determination of HCV genotype and of the number of HCV-positive hepatocytes in liver tissue) with that of immunological aspects (expression and distribution of HLA-A,B,C and ICAM-1 molecules and counting of CD8 T cells).

Methods

38 consecutive α -IFN-treated patients, selected on the basis of pure HCV etiology, the availability of a frozen liver biopsy and of serum properly stored for HCV RNA detection and HCV genotype identification were studied. The schedule of treatment included the use of either recombinant or limphoblastoid α -interferon (6 MU three times a week for 3 mo, 3 MU three times a week for 3 mo respectively).

24 subjects displayed primary response, defined as normalization of transaminase levels and disappearance of serum HCV RNA within 3 mo of treatment. 12 of these relapsed after withdrawal of treatment, 11 have not completed the protocol of the study yet (6 mo treatment and 12 mo follow-up), and 1 has persistently normal alanine amino transferase (ALT) values 1 yr after withdrawal of treatment.

Clinical, biochemical, and histological data of responders (R) and nonresponders (NR) are reported in Table I. The presence of hepatitis

Address correspondence to Giorgio Ballardini, Clinica Medica II, Pol. S. Orsola, via Massarenti 9, 40138, Bologna, Italy. Phone: 39-51-392524; FAX: 39-51-340877.

Received for publication 30 June 1994 and in revised form 28 December 1994.

1. Abbreviations used in this paper: ALT, alanine amino transferase; HBV, hepatitis B virus; HCV, hepatitis C virus; ICAM-1 intercellular adhesion-1 molecule; α -IFN, α -interferon; NR, nonresponder; R, responder.

J. Clin. Invest.

© The American Society for Clinical Investigation, Inc.

0021-9738/95/05/2067/09 \$2.00

Volume 95, May 1995, 2067–2075

B virus (HBV) antigens and antibodies were excluded with the use of appropriate commercial RIAs. Alcohol abuse was excluded on the basis of clinical history. Wilson's disease, α 1-antitrypsin deficiency and hemochromatosis were ruled out by the quantification of serum ceruloplasmin, α 1-antitrypsin, and ferritin, respectively. Autoimmune hepatitis was excluded by the absence of autoantibodies to actin, homogeneously distributed nuclear antigens and LKM1, searched for by indirect immunofluorescence on rodent substrates and HEp-2 cells. Anti-HCV positivity was assessed by ELISA 2 (Ortho Diagnostics System, Inc., Raritan, NJ).

Serum HCV RNA was tested by nested PCR using primers derived from the 5'UTR as previously described (20). Blood samples were drawn under sterile conditions, the serum separated within 2 h, divided into aliquots, and stored at -70°C until tested. Serum RNA was extracted from $100\ \mu\text{l}$ by the guanidinium thiocyanate-phenol-chloroform procedure (21). Kwok and Higuchi's contamination avoidance measures (22) were strictly observed throughout the study. One negative control and three positive samples (dilutions 10^{-1} , 10^{-2} , and 10^{-3} of a positive serum in a negative one) were used for every 10 sera tested. Positive and negative results were systematically confirmed.

The HCV genotype was determined according to a recently described method (23). Briefly, 5'UTR-amplified products were spotted in triplicate on nylon filters and hybridized with ^{32}P -labeled probes specific for HCV-1, HCV-2, and HCV-3 (Simmonds classification) (24). After 2 h hybridization at 42°C , filters were washed in stringent conditions and exposed overnight with autoradiographic films. The sera from patients infected by genotype 1 were further tested by a commercially available kit (INNO-LIPA HCV; Innogenetics, Zwijndrecht, Belgium) for characterization of subtypes 1a and 1b (25).

Liver biopsy studies. All patients gave informed consent to liver biopsy, which was part of the diagnostic routine. Five normal surgical biopsies were selected among liver biopsies obtained from patients operated on for extrahepatic disorders and used as controls.

Biopsy specimens were obtained percutaneously with a 1.6-mm Hepafix needle. Samples (length 15–30 mm) were divided into 2 fragments: one was fixed in formalin and embedded in paraffin for histological examination, the other was immediately embedded in Tissue-Tek OCT compound (Miles Inc., Elkhart, IN), mounted on a piece of cork, snap frozen in *N*-methylbutane, precooled in liquid nitrogen, and kept at -70°C until examined.

5- μm serial cryostat sections were air dried overnight, fixed with acetone for 5 min, wrapped in aluminium foil, and stored at -20°C until used. Before immunostaining, sections were further fixed with chloroform for 5 min.

Immunostaining of HCV antigens. Tissue HCV antigens were searched for using fluorescein-conjugated human IgG. IgG were purified using protein G columns (Pharmacia LKB Biotechnology Inc., Uppsala, Sweden) from 20 high titer anti-HCV positive sera of patients affected by chronic active hepatitis and 5 anti-HCV negative sera. All were negative for serum autoantibodies. IgG were conjugated at a protein concentration of 1.5–2 mg/ml with FITC isomer I, (Sigma Chemical Co., St. Louis, MO) by the dialysis method (26).

FITC-conjugated IgG were adsorbed overnight with 10 mg/ml normal human liver acetone powder; 2 vol of commercial normal human Ig (protein concentration 33 mg/ml; Sandoz SA, Basel, Switzerland) were added. The FITC-conjugated sera were then tested on 12 frozen, acetone-chloroform-fixed liver biopsy sections from 10 anti-HCV positive patients and 2 normal livers.

In brief $50\ \mu\text{l}$ of reagent were incubated for 2 h at room temperature in a moist chamber, washed in PBS, mounted in PBS-glycerol, and observed using an Ortoplan microscope (E. Leitz Wetzlar GmbH, Wetzlar, Germany).

Two sera (named s47 and s46) were selected since they gave clear hepatocellular staining in 3 HCV-positive biopsies. The pattern of positivity corresponded to that previously described by Krawczynski (powder-like or granular staining of single hepatocytes) (27) (Fig. 1). The 2 sera stained the same cells on serial sections. The sera named s47 was chosen for the extensive study because of a more favorable staining to background ratio.

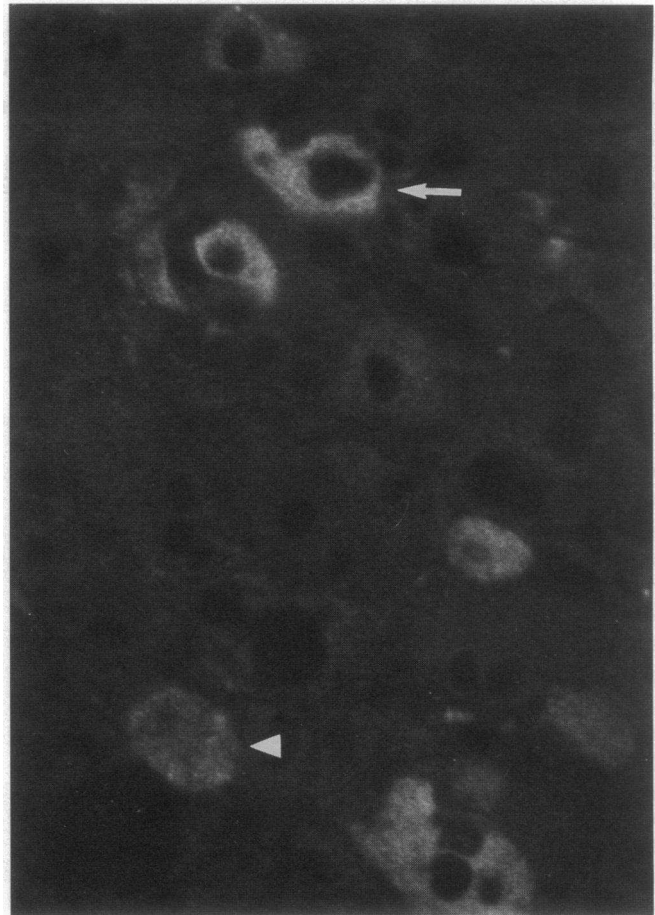


Figure 1. Direct immunofluorescence with anti-HCV IgG. A lobular area with numerous hepatocytes displaying strong (arrow) or faint (arrowhead) intensity of staining. $\times 600$.

The staining technique was optimized for light microscopy, using an amplified technique. The serum was further diluted 1:10 with PBS, sections were incubated overnight in a moist chamber at 6°C . After washing (PBS, 30 min), a monoclonal antibody to fluorescein (DAK-FITC4; Dako A/S, Glostrup, Denmark, diluted 1:50 in PBS) was applied, followed by peroxidase-conjugated rabbit anti-mouse Ig (Dako A/S, diluted 1:50 with PBS containing 5% normal group AB human serum), and peroxidase-conjugated swine anti-rabbit Ig (Dako A/S, diluted 1:100 with PBS containing 5% normal group AB human serum). Each of the three reagents was incubated for 30 min at room temperature, followed by a 15-min PBS wash. The reaction was developed with 0.5 mg/ml diaminobenzidine tetrahydrochloride (Sigma Chemical Co.) in 0.05 M Tris HCl buffer, pH 7.8, containing 0.003% H_2O_2 , for 7 min in the dark. Sections were dehydrated in alcohol, cleared in xylol, and mounted with Eukit (O. Kindler GmbH, Freiburg, Germany). Controls of specificity included the study of anti-HCV-negative cases, blocking experiments with 5 high titer anti-HCV-positive sera, and 5 anti-HCV-negative sera, and reproduction of the staining pattern by anti-HCV-specific immunoglobulins eluted by RIBA 2 strips (Ortho Diagnostic Systems Inc.).

Liver biopsies from 38 anti-HCV-positive cases, 20 anti-HCV-negative patients (the etiology in eight was hepatitis B virus, five primary biliary cirrhosis, four alcohol, three autoimmune), and five normal livers were studied. 31 (81.6%) of the anti-HCV-positive cases had detectable HCV antigens in the biopsy, while no reactivity was found in the 25 anti-HCV-negative cases.

Blocking experiments were performed diluting FITC-IgG in 2 vol of blocking sera instead of normal IgG. A complete block was observed

with four and a significant reduction of staining intensity in one of the anti-HCV-positive blocking sera. No effect was observed with the anti-HCV-negative sera.

Elution experiments were performed as follows: 20 RIBA 2 strips were incubated and washed according to the manufacturer's protocol with the serum named s47. The four antigen-containing bands were cut from the strips and placed into a tube. The nonantigen-containing portion of strips was similarly treated and served as control. After a further wash with PBS, immunoglobulins were acid eluted with 500 μ l 0.1 M glycine-HCl (pH 2.7) under continuous stirring for 1 min, immediately neutralized with 20 μ l 1 N NaOH and 125 μ l 0.1 M carbonate buffer pH 9.2. The eluate from the antigen-containing bands was able to reproduce the RIBA 2 pattern of positivity; control eluate was negative. After FITC conjugation immunohistochemistry was performed. The specific pattern was obtained at a dilution of 1:20. No staining was obtained with the control eluate.

Immunostaining: monoclonal antibodies. The following mAbs were tested on serial frozen sections: HLA-A,B,C molecules (clone W632; Dako A/S, diluted 1:150 in PBS), ICAM-1/CD54 molecules (clone 84H10; Immunotech, Marseille, France, diluted 1:30 in PBS), CD8 (clone DK25; Dako A/S) diluted 1:50. A three step peroxidase technique was used as described above, omitting the use of anti-fluorescein antibody.

Since anti-HCV IgG specifically stained hepatocytes, combined incubations with CD8 antibody were also performed. This allowed to better evaluate the relative distribution of viral antigens and lymphocytes and to relate them to histological lesions such as piecemeal necrosis, lobular necrosis, and apoptotic bodies.

A double immunofluorescence technique was applied in selected biopsies to evaluate the relative distribution of HCV antigens and HLA-A,B,C or ICAM-1 molecules. In brief, FITC-conjugated anti-HCV IgG were incubated 2 h as described above in a moist chamber; after washing, mAbs to HLA-A,B,C or ICAM-1 molecules were applied overnight as described above. Rhodamine-conjugated rabbit anti-mouse and swine anti-rabbit Ig were then applied for 30 min (Dako A/S, diluted 1:20 with PBS containing 5% normal group AB human serum) Each of the two reagents was incubated for 30 min at room temperature, followed by a 15-min PBS wash. Sections were then mounted with PBS-glycerol and observed at different wave lengths for FITC and rhodamine fluorochromes.

Control sections were stained omitting primary antibodies or using normal, FITC-conjugated, human IgG and an unrelated mAb.

The slides were evaluated blindly by two independent observers who scored the following parameters: (a) Histological activity, defined as mild (absent or occasional mild piecemeal necrosis), moderate (presence of piecemeal, but not bridging necrosis), or severe (presence of piecemeal and bridging necrosis). Presence of cirrhosis was also recorded. (b) CD8-positive T cells were evaluated as the number of foci of lobular necrosis and the number of sparse lobular T cells (not including focal necrosis) with a square grid (400 \times 400 μ m using a \times 25 objective and an \times 8 eyepiece). Foci were defined as groups of five or more intralobular CD8-positive lymphocytes with or without Councilman-like bodies. The whole biopsy was evaluated and the number of foci was related to the area (number/10 mm²). The number of lobular CD8 T cells (not including focal necrosis areas) was counted in five randomly chosen fields and related to the area (number/mm²). (c) Hepatocellular HLA-A,B,C and ICAM-1 positivity was evaluated observing the whole biopsy; the results were scored as follows: 0, no staining of hepatocellular membranes; 1, focal (< 10%) staining of hepatocellular membranes; 2, zonal (10–70% of the biopsy) or faint "honeycomb" pattern; and 3, diffuse (> 70% of the biopsy) and strong honeycomb pattern. (d) The presence of HCV-related antigens was scored according to Krawczynski et al. (27) considering the number of hepatocytes containing HCV antigens as: 0, no staining; 1, < 5%; 2, 5–20%; 3, > 20% positive hepatocytes.

Mean values of the different groups were compared by ANOVA; Chi square and Wilcoxon rank sum test were used when appropriate. Discriminant analysis and stepwise discriminant analysis were per-

formed to evaluate the capacity of the above parameters to discriminate between responder and nonresponder patients.

Results

Clinical, biochemical, histological, and virological data of the 38 patients at the time of liver biopsy are summarized and related to response to interferon, tissue HCV positivity, and HCV genotype in Table I.

HCV genotype. HCV genotype was found to be type 1b in 17 patients, type 1a in 4, type 2 in 8, and type 3 in 9. All the patients infected by type 3, three of the four patients infected by type 1a, and six of the eight patients infected by genotype 2 had a primary response to treatment. Only 6 out of the 17 infected by type 1b HCV responded to interferon (ANOVA, $P < 0.006$).

Tissue HCV antigens. HCV-related antigens were found in 31 of the 38 patients (81.6%). Of these 10 scored 1, 8 scored 2, and 13 scored 3. The staining pattern showed great variability in the number and intensity of positive cells, ranging from few faint cells to numerous strongly positive cells (Fig. 2, a–c). Weak and strong positive cells (Fig. 2 c) were usually contemporarily observed in the same biopsy, the distribution was often focal, with areas of numerous positive cells and areas without stained hepatocytes. No preferential lobular distribution was observed. No constant codistribution was noted with CD8-positive T cells in piecemeal necrosis or focal necrosis areas. Nevertheless, CD8-positive T cells were frequently seen in contact with HCV-containing hepatocytes (Fig. 2, a–c) and occasionally with HCV-containing apoptotic bodies (Fig. 3, a). This was observed for both single T cells and groups of T cells in piecemeal necrosis or focal necrosis areas (Fig. 3 b), more frequently in responder cases, with lower numbers of HCV-positive hepatocytes.

HCV antigens were detected in 13 of the 14 (93%) nonresponder cases and in 18 of the 24 (75%) responders (Table II). The number of positive cells was clearly higher in nonresponder cases, most of which were infected by genotype 1b HCV than in responder patients (mean scores 2.36 and 1.33 respectively, ANOVA: $P < 0.03$). Significantly higher scores of positivity were observed in genotype 1b than in genotype 3 patients (mean scores 2.24 vs 1.11, ANOVA: $P < 0.05$).

No significant correlation was found between HCV scores, liver histology, ALT levels, and number of CD8-positive T cells, when considering all the patients. Higher ALT (Wilcoxon rank sum test, $P < 0.001$), lobular T cell values (NS), and lower (NS) age were found in patients scored who 1 than in patients scored who 3 or 0 for tissue HCV. Limiting the observation to patients with detectable HCV antigens in liver biopsy, a negative correlation trend with HCV scores was observed for both ALT ($r = -0.311$, NS) and lobular T cells ($r = -0.412$, $P < 0.02$). The number of CD8 T cells (in particular lobular T cells) was significantly correlated with ALT levels ($P < 0.03$) (Table III).

Tissue HLA-A,B,C and ICAM-1 molecules. In normal liver, hepatocytes showed no or weak membrane staining for HLA-A,B,C molecules, usually confined to the basolateral portion of the hepatocellular membrane. Sinusoidal cells were clearly the most positive cells in the lobule. ICAM-1 molecules were detected in sinusoidal cells and vascular endothelium. Hepatocytes and bile duct cells were consistently negative.

In diseased liver the prominent feature was an increased intensity of staining of both molecules at the level of hepatocel-

Table 1. Clinical, Histological, and Biochemical Parameters of Study Population

		α -IFN response		Tissue HCV score				HCV genotype			
		NR	R	0	1	2	3	1b	1a	2	3
No. of patients	38	14	24	7	10	8	13	17	4	8	9
Age (median)	50	53	39	51	36	43	52	55	27	53	33
Sex male/female	23/15	8/6	15/9	4/3	7/3	4/4	8/5	9/8	4/0	3/5	7/2
CAH											
Mild	20	5	15	4	7	3	6	9	3	2	6
Moderate	10	5	5	1	1	4	4	3	1	3	3
Severe	6	3	3	1	2	1	2	4	0	2	0
Cirrhosis	2	1	1	1	0	0	1	1	0	1	0
ALT (median)	105	105	102	83	168	97	86	86	174	142	139

CAH, chronic active hepatitis; ALT, normal value, < 37 U/liter. Age is able to discriminate between NR and R patients (discriminant analysis, $P < 0.04$). Median age is higher in patients infected by genotype 1b with respect to patients infected by genotype 3 (Wilcoxon rank sum test, $P < 0.001$). Median ALT level is higher in patients with tissue HCV score 1 with respect to patients with tissue HCV score 3 (Wilcoxon rank sum test, $P < 0.001$).

lular membranes, which were often completely stained. The resulting pattern of positivity was a honeycomb appearance of the liver lobule. This pattern was frequently diffuse in the whole biopsy and the intensity of the reaction was similar to that of sinusoidal cells. The comparison of serial sections generally showed a codistribution of the two molecules. The staining pattern was slightly different. The staining of hepatocellular membranes was in general coarse, stronger, and more diffuse with the antibody to HLA molecules (Fig. 4) with respect to ICAM-1 staining (Fig. 5 a).

Codistribution was particularly evident in biopsies with low HLA-A,B,C expression (*pattern 1*) where a strong hepatocellular reaction was often observed in piecemeal necrosis and lobular focal necrosis areas for both molecules.

Hepatocellular expression of both HLA-A,B,C and ICAM-1 molecules was higher in NR than in R patients (ANOVA, $P < 0.0001$ and $P < 0.02$, respectively, Table IV). Limiting the evaluation to genotype 1b cases, the difference between NR and R patients was still significant ($P < 0.0003$ and $P < 0.02$, respectively).

Apart from a codistribution in piecemeal necrosis and lobular necrosis areas, where high expression of HLA-A,B,C and ICAM-1 molecules corresponded to a concentration of T cells (mainly CD8), no relationship was found between the overall number of lobular T cells and the amount of HLA-A,B,C and ICAM-1 molecules. Biopsies containing high numbers of HCV-positive hepatocytes, usually from patients infected by genotype 1b, also displayed strong positivity for HLA-A,B,C and ICAM-1 molecules. Double IFL clearly showed that hepatocytes containing HCV antigens (Fig. 5 b) were also positive for both ICAM-1 (Fig. 5 a) and HLA-A,B,C molecules (Fig. 4).

Determinants of response to treatment. By discriminant analysis, age ($P < 0.04$), HCV genotype ($P < 0.006$), tissue HCV antigens ($P < 0.006$), HLA-A,B,C ($P < 0.0001$), and ICAM-1 ($P < 0.03$) molecules turned out to be significantly different between responder and nonresponder cases. The age difference in the two groups was related to the different behavior of genotype 1b (median age 55) and genotype 3 (median age 33) (Wilcoxon rank sum test, $P < 0.001$), rather than to a correlation between age and response to interferon. In fact, in patients infected by genotype 1b no difference was found between the age of responder and nonresponder cases.

By stepwise discriminant analysis, tissue HLA-A,B,C, HCV

antigens, and HCV genotype resulted the main discriminant parameters, while the other parameters added little information. By combination of these three parameters 12 of the 14 nonresponder and 22 of the 24 responder patients were correctly classified (89.5%).

Discussion

The present results confirm previous observations of a lower chance of response to IFN in patients infected by genotype 1 HCV (8–11) and displaying high numbers of HCV-positive hepatocytes in liver biopsy (15). It details new information in that: (a) genotype 1b HCV infection is associated with the presence of a higher number of HCV, HLA-A,B,C, and ICAM-1-positive hepatocytes and of lower numbers of lobular CD8-positive cells; (b) CD8-positive cells have been observed in contact with HCV-containing hepatocytes or apoptotic bodies; (c) the number of lobular CD8-positive cells correlates with ALT levels; (d) the expression of HLA-A,B,C and ICAM-1 molecules before treatment is significantly higher in patients who will not respond to α -IFN treatment than in responders; and (e) HCV-infected hepatocytes are able to express both HLA-A,B,C and ICAM-1 molecules.

The last finding is at variance with the events described in chronic hepatitis B. Although it is known that synthesis and expression of HLA-A,B,C molecules can be induced by viruses through interferon production, in this condition a low hepatocellular expression of HLA-A,B,C molecules, due to HBV-specific inhibition of the endogenous interferon system, has been reported (17, 19, 28). This has been considered responsible for a deficient cytotoxic T cell (class I restricted) activity (28). It has been postulated that interferon treatment may restore HLA-A,B,C molecule expression. As a consequence cytotoxic T cell lysis of HBV-infected hepatocytes and HBV clearance occur. The temporary increase of ALT levels, which is known to precede HBeAg to anti-HBe seroconversion during interferon treatment, seems to support this hypothesis (17). On the basis of liver immunopathology, the mechanism of hepatocellular damage does not appear to be different in HBV- and HCV-related hepatitis. In both conditions hepatocellular immune lysis seems to be mediated by cytotoxic T cells (29). HCV-infected cells, however, are able to express HLA-A,B,C and ICAM-1 molecules and, in responder patients, interferon treatment is followed

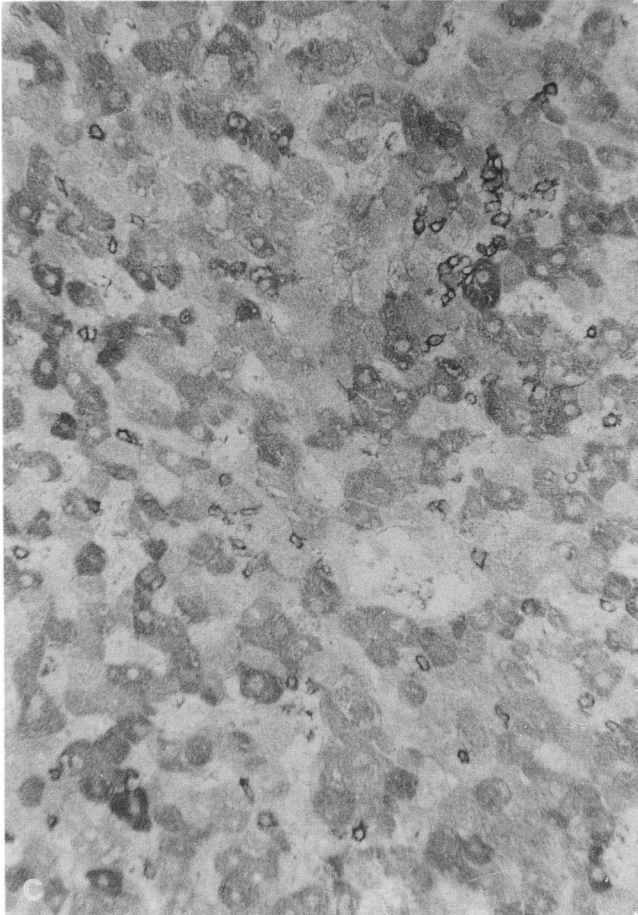
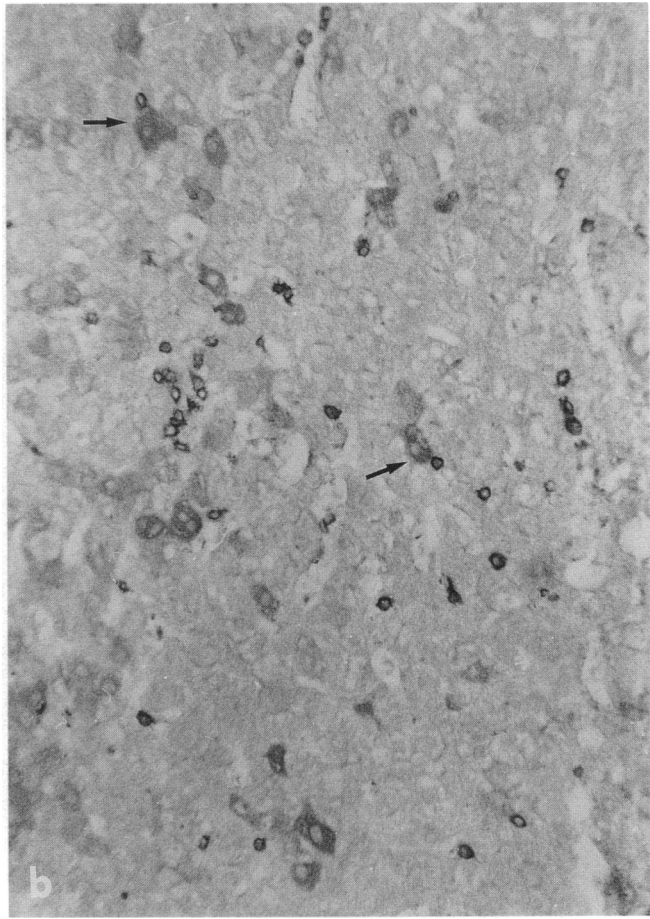
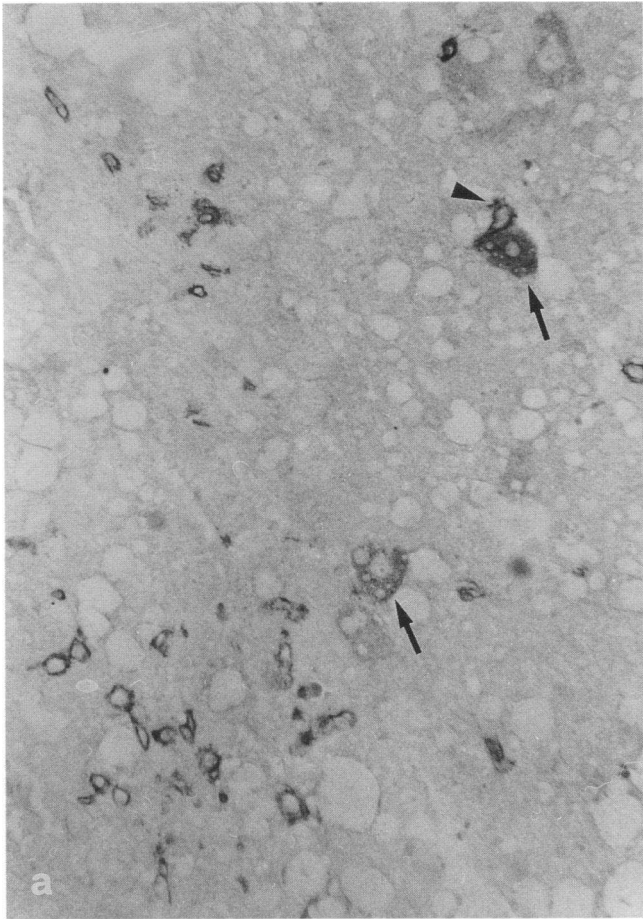


Figure 2. Lobular areas from different liver biopsies stained by immunoperoxidase for both HCV antigens and CD8 T cells. (a) Few HCV-positive cells (*arrows*). One CD8 T cell (*arrowhead*) in contact with one of these. $\times 300$. (b) Numerous HCV-positive cells. CD8 T cells occasionally in contact with HCV-containing hepatocytes (*arrows*). $\times 200$. (c) Most of the hepatocytes contain HCV antigens, with different intensity of staining. $\times 200$.

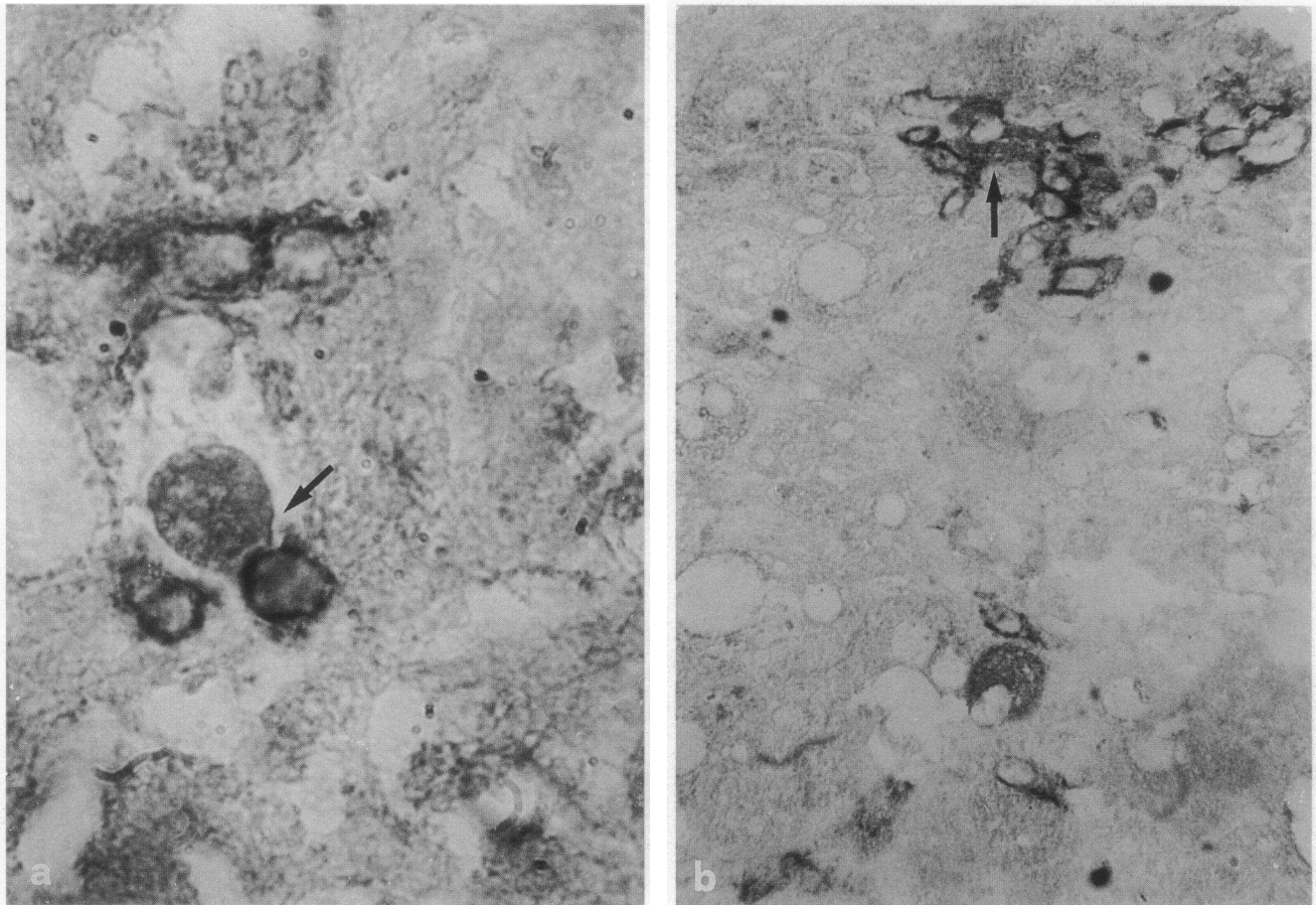


Figure 3. Lobular areas stained by immunoperoxidase for both HCV antigens and CD8 T cells. (a) One apoptotic body in contact with CD8 T cells (arrow). $\times 1200$. (b) One HCV-containing hepatocyte surrounded by CD8 T cells (arrow). $\times 600$.

by rapid disappearance of serum HCV-RNA (30) and by normalization of ALT levels. Thus, inhibition of HCV replication (30) and, possibly, of viral antigens expression (15) seems to be the main mechanism of response to the drug.

The present study supports the hypothesis that CD8 mediated cytotoxicity against HCV-infected hepatocytes does occur in vivo. Apoptotic bodies, positive for HCV antigens, have, in fact, been observed in lobular necrosis areas in contact with CD8-positive cells (Councilman-like bodies). The lack of clear

codistribution of CD8 lymphocytes with hepatocytes containing HCV antigens could possibly be due to the impossibility of immunohistochemistry to discriminate between nonspecific and HCV-specific T cells. Moreover the hypothesis has recently been made that resting T cells at sites of antigen-specific response might be stimulated (by cytokines produced by HCV-specific T cells and macrophages) to proliferate and to secrete other lymphokines, which could further amplify the response (31) and contribute to tissue damage.

Technical explanations for the absence of clear codistribution include the presence of hepatocytes containing low amounts of HCV antigens, not detectable by the present staining technique and the possibility that cells undergoing apoptosis might be quickly removed (32), thus lowering the probability to demonstrate codistribution with T cells.

The significant correlation between ALT levels and the number of lobular CD8 lymphocytes, previously reported in another study (29), as well as the lack of correlation between the number of hepatocytes positive for HCV antigens and the severity of histological disease or ALT levels further support the hypothesis of a prominent role of CD8 T cells in determining hepatocellular damage with respect to direct HCV-mediated cytopathic effect.

It is difficult to explain why the immune system has different capacities to control viral infection in individual patients.

Viral persistence is, almost by definition, associated with the development of mechanisms for avoiding viral recognition by host cytotoxic T cells (33).

Table II. Tissue HCV Antigens in Relation to α -IFN Response and HCV Genotype

		α -IFN response		HCV genotype				
		NR	R	1b	1a	2	3	
Tissue	0	7	1	6	2	1	2	2
HCV	1	10	1	9	1	1	3	5
Score	2	8	4	4	5	2	0	1
	3	13	8	5	9	0	3	1
	Means	2.36	1.33	2.24	1.25	1.5	1.11	

Tissue HCV score is able to discriminate between NR and R patients (discriminant analysis, $P < 0.006$). Mean tissue HCV score is higher in patients infected by genotype 1b HCV with respect to patients infected by genotype 3 HCV (ANOVA, $P < 0.05$).

Table III. CD8 T Cells in Relation to α -IFN Response, Tissue HCV Score, and HCV Genotype

	α -IFN response		Tissue HCV score				HCV genotype				
	NR	R	0	1	2	3	1b	1a	2	3	
CD8, foci/10 mm ²	8.2	6.8	8.5	8.0	11.8	10.0	6.3	7.2	12.4	8.7	9.0
CD8, lobular/mm ²	84	84	98	72	121	93	76	80	75	80	129
ALT	105	105	102	83	168	97	86	86	174	142	139

ALT, normal value, < 37 U/liter. The data are reported as median values. A significant correlation ($P < 0.03$) is found between ALT levels and the number of lobular CD8 T cells. Higher ALT levels (Wilcoxon rank sum test, $P < 0.001$) and higher numbers of lobular CD8 T cells (NS) were found in patients with tissue HCV score 1 vs 3. Higher numbers of lobular CD8 T cells (Wilcoxon rank sum test, $P < 0.05$) and higher ALT levels (NS) were found in patients infected by genotype 3 vs 1b.

Down-regulation of HLA-A,B,C and ICAM-1 molecules is a well-documented escape mechanism of hepatitic (19, 28) and nonhepatitic viruses (34–36). As already mentioned, HCV-containing hepatocytes are clearly able to express HLA-A,B,C and ICAM-1 molecules. The possibility of defective T cell recognition due to lack of membrane adhesion molecules can be therefore ruled out. It has been postulated that circulating soluble ICAM-1 molecules, which have been demonstrated to be highly increased in HCV patients not responding to interferon, may interfere with T cell activity and possibly display an anergizing effect (37).

In liver biopsies with high numbers of HCV-positive hepato-

cytes, frequently from patients infected by genotype 1b, low ALT levels and a low number of lobular T cells and of apoptotic bodies positive for HCV antigens are usually observed. This suggests the existence of lower T cytotoxic cell activity and more efficient viral strategies to escape from CD8 T cell recognition with respect to patients with a low number of infected hepatocytes.

In patients infected by 1a, 2, and, in particular, genotype 3 HCV, exogenous interferon is frequently able to inhibit viral replication and to induce both a primary and a long-term response (8). T cell response could be in a more favorable balance with viral strategies, thus allowing a more effective control of virus spreading and clearance of infected cells.

A further point to be discussed concerns patients with undetectable HCV antigens in liver tissue (score 0). All of them were positive for serum HCV-RNA. Absence of positive cells was thought to represent sampling errors in patients with very low amounts of tissue antigens and clinical and biochemical parameters were expected to be similar to those of patients who scored 1. On the contrary the age was higher, the median ALT level and the number of lobular CD8 T cells were lower and similar to that of patients who scored 3 for HCV antigens. These data might reflect a low stimulation of the immune system due to poor antigen expression in patients negative for tissue HCV antigens. The low number of cases does not allow to emphasize this hypothesis, but, interestingly, a similar ALT behavior was previously reported in a similar group of patients (15).

As to the mechanisms underlying the absence of response to interferon, the following hypothesis is proposed. It is based on the possibility that hepatocellular HLA-A,B,C molecules expression might be viewed as an indicator of the hepatocellular response to endogenous interferon system. Two considerations might support this possibility. It is known that viral replication induces interferon production, which in turn stimulates the synthesis of interferon-inducible molecules, including HLA-A,B,C molecules. It has been demonstrated in chimpanzees that acute HCV infection is associated with induction of two main genes, related to α -IFN and HLA-A,B,C molecules (38).

It is known that other agents or pathophysiological conditions, as cholestasis (39), can induce HLA-A,B,C molecules. We have previously shown (16) that their increase is less prominent in primary biliary cirrhosis stage 4 patients than in HCV-related chronic liver disease. In this study we show that, apart from the codistribution with lymphocytes in piecemeal necrosis and lobular necrosis areas, no relation has been found between the number of CD8-positive cells and the entity of HLA expression. In particular, the number of CD8 cells is lower, although not significantly, in nonresponder patients, who show a high

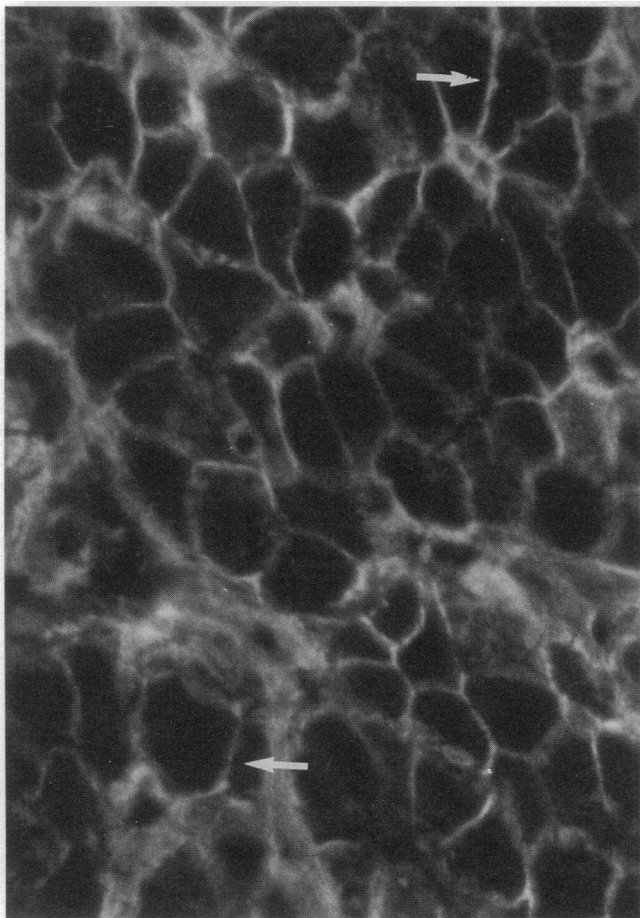


Figure 4. Lobular area. Immunofluorescence. Diffuse hepatocellular staining (arrow) for HLA-A,B,C molecules. $\times 600$.

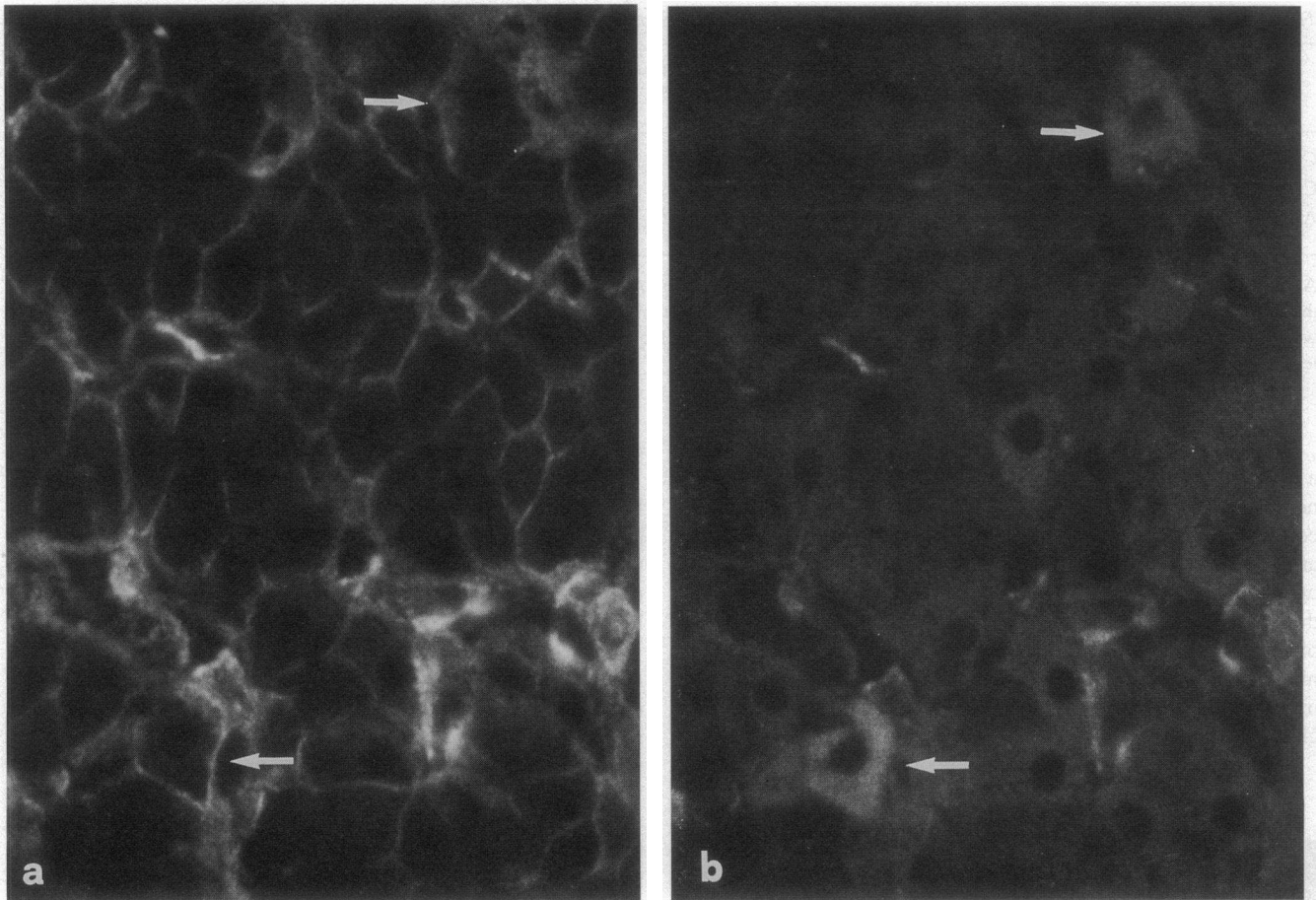


Figure 5. Serial section to Fig. 4, stained with double immunofluorescence for ICAM-1 molecules (a) and HCV antigens (b): HCV-containing hepatocytes (arrows) are clearly positive for ICAM-1 molecules (arrows). $\times 600$.

HLA score, with respect to responder patients. Therefore lymphokines do not seem to play a prominent role in determining the HLA-A,B,C pattern, which, in HCV-infected patients, might mainly reflect HCV-induced activation of the endogenous interferon system.

Based on this, our findings seem to reflect a different virus-

dependent stimulation of the endogenous interferon system in responder and nonresponder patients. The entity of accumulation of HCV antigens in tissue does not necessarily correspond to the entity of viral replication, but clearly the number of positive cells corresponds to the number of infected cells (40). A higher viremia has been demonstrated in nonresponder pa-

Table IV. HLA and ICAM Score in Relation to α -IFN Response and Tissue HCV Score

		α -IFN response		Tissue HCV score				HCV genotype				
		NR	R	0	1	2	3	1b	1a	2	3	
HLA-A,B,C Score	0	0	0	0	0	0	0	0	0	0	0	0
	1	12	1	11	3	3	2	4	4	2	4	2
	2	17	4	13	3	7	2	5	5	2	3	7
	3	9	9	0	1	0	4	4	8	0	1	0
	Means		2.57	1.54	1.71	1.70	2.25	2.0	2.24	1.5	1.63	1.78
ICAM-1 Score	0	7	2	5	3	2	0	2	1	2	0	3
	1	18	3	15	3	7	3	5	8	1	4	4
	2	8	6	2	1	1	2	5	5	1	3	0
	3	5	3	2	0	0	3	2	3	0	1	2
	Means		1.71	1.04	0.71	0.9	2.0	1.61	1.59	0.75	1.63	1.1

HLA-A,B,C and ICAM-1 scores are able to discriminate between NR and R patients (discriminant analysis $P < 0.0001$ and $P < 0.03$, respectively). Although statistical significance is not reached, higher mean HLA-A,B,C and ICAM-1 tissue score are observed in patients with tissue HCV score 2–3 vs 0–1 and in patients infected by genotype 1b vs genotype 3.

tients (12–14) and a correspondence between serum and tissue HCV RNA levels has been recently reported (41). Thus in our model a high number of infected cells, which is mainly found in nonresponder patients, should reflect high tissue viral replication. Massive, not further inducible, activation of the endogenous interferon system might explain the high expression of HLA-A,B,C molecules and the resistance to exogenous interferon. This condition appears to be associated with genotype 1b infection.

In patients with low activation of the endogenous interferon system, exogenous interferon might be successful in inhibiting viral replication thus moving the balance in favor of the immune system, and allowing the elimination of infected cells.

References

- Koziel, M. J., D. Dudley, J. T. Wong, J. Dienstag, M. Houghton, R. Ralston, and B. D. Walker. 1992. Intrahepatic cytotoxic T lymphocytes specific for hepatitis C virus in persons with chronic hepatitis. *J. Immunol.* 149:3339–3344.
- Bottarelli, P., P. Brunetto, M. A. Minutello, P. Calvo, D. Unutmaz, A. J. Weiner, Q. L. Choo, J. R. Shuster, J. R. Kuo, F. Bonino, et al. 1993. T-lymphocyte response to hepatitis C virus in different clinical courses of infection. *Gastroenterology.* 104:580–587.
- Ferrari, C., A. Valli, L. Galati, A. Penna, P. Scaccaglia, T. Giuberti, C. Schianchi, G. Missale, M. G. Marin, and F. Fiaccadori. 1994. T-cell response to structural and non-structural hepatitis C virus antigens in persistent and self-limited hepatitis C virus infections. *Hepatology.* 19:286–295.
- Davis, G. L., L. A. Balart, E. R. Schiff, K. Lindsay, H. C. Bodenheimer, R. P. Perrillo, W. Carey, I. M. Jacobson, J. Payne, J. L. Dienstag, et al. and the Hepatitis Interventional Therapy Group. 1989. Treatment of chronic hepatitis C with recombinant interferon alpha. A multicenter randomized, controlled trial. *N. Engl. J. Med.* 321:1501–1506.
- Di Bisceglie, A. M., P. Martin, C. Kassianides, M. Lisker-Melman, L. Murray, J. Waggoner, B. A. Zachary Goodman, S. M. Banks, and J. Hoofnagle. 1989. Recombinant interferon alpha therapy for chronic hepatitis C. Randomized, double blind, placebo-controlled trial. *N. Engl. J. Med.* 321:1506–1510.
- Battezzati, P. M., M. Podda, S. Bruno, M. Zuin, A. Crosignani, M. Camisasca, A. Chiesa, M. L. Petroni, A. Russo, P. Gallotti, et al. 1992. Factors predicting early response to treatment with recombinant interferon alpha 2-a in chronic non-A, non-B hepatitis. Preliminary report of a long-term trial. *Ital. J. Gastroenterol.* 24:481–484.
- Cammà, C., A. Craxi, F. Tinè, P. Almasio, V. Di Marco, O. Loiacono, R. Bruno, F. Fiorello, and L. Pagliaro. 1992. Predictors of response to alpha interferon (IFN) in chronic hepatitis C: a multivariate analysis on 361 treated patients. *Hepatology.* 16:348a. (Abstr.)
- Yoshioka, K., S. Kakumu, T. Wakita, T. Ishikawa, Y. Itoh, M. Takayanagi, Y. Higashi, M. Shibata, and T. Morishima. 1992. Detection of hepatitis C virus by polymerase chain reaction and response to interferon-alpha therapy: relation to genotypes of hepatitis C virus. *Hepatology.* 16:293–299.
- Takada, N., S. Takase, N. Enotomo, A. Tanaka, and T. Date. 1992. Clinical backgrounds of the patients having different types of hepatitis C virus genomes. *J. Hepatol.* 14:35–40.
- Chemello, L., A. Alberti, K. Rose, and P. Simmonds. 1994. Hepatitis C serotype and response to interferon therapy. *N. Engl. J. Med.* 330:143.
- Dusheiko, G., H. Schmilovitz-Weiss, D. Brown, F. McOmish, P. L. Yap, S. Sherlock, N. McIntyre, and P. Simmonds. 1994. Hepatitis C virus genotypes: an investigation of type-specific differences in geographic origin and disease. *Hepatology.* 19:13–18.
- Hagiwara, H., N. Hayashi, E. Mita, T. Takehara, A. Kasahara, H. Fusamoto, and T. Kamada. 1993. Quantitative analysis of hepatitis C virus RNA in serum during interferon alpha therapy. *Gastroenterology.* 104:877–883.
- Magrin, S., A. Craxi, F. Carmelo, R. G. Simonetti, G. Fiorentino, L. Marino, O. Diquattro, V. Di Marco, O. Loiacono, R. Volpe, et al. 1994. Hepatitis C viremia in chronic liver disease: relationship to interferon-alpha or corticosteroid treatment. *Hepatology.* 19:273–279.
- Lau, J. Y. N., G. L. Davis, J. Kniffen, K. P. Qian, M. S. Urdea, C. S. Chan, M. Mikozami, P. D. Newald, and J. C. Weiner. 1993. Significance of serum hepatitis C virus RNA levels in chronic hepatitis C. *Lancet.* 341:1501–1504.
- Di Bisceglie, A., J. H. Hoofnagle, and K. Krawczynski. 1993. Changes in hepatitis C virus antigen in liver with antiviral therapy. *Gastroenterology.* 105:858–862.
- Ballardini, G., P. Groff, F. Giostra, R. Francesconi, D. Zauli, G. P. Bianchi, M. Lenzi, F. Cassani, and F. B. Bianchi. 1994. Hepatocellular expression of HLA-A,B,C molecules predicts primary response to interferon in patients with chronic hepatitis C. *Am. J. Clin. Pathol.* 102:746–751.
- Pignatelli, M., J. Waters, D. Brown, A. M. L. Lever, S. Iwarson, Z. Schaff, R. Gerety, and H. C. Thomas. 1986. HLA Class I antigens on hepatocyte membrane during recovery from acute hepatitis B infection and during interferon therapy in chronic hepatitis B virus infection. *Hepatology.* 6:349–353.
- Franco, A., V. Barnaba, P. Natali, C. Balsano, A. Musca, and F. Balsano. 1988. Expression of Class I and Class II major histocompatibility complex antigens on human hepatocytes. *Hepatology.* 8:449–454.
- Takehara, T., N. Hayashi, K. Katayama, K. Ueda, T. Towata, A. Kasahara, H. Fusamoto, and T. Kamada. 1992. Enhanced expression of HLA class I by inhibited replication of hepatitis B virus. *J. Hepatol.* 14:232–236.
- Garson, J. A., M. Lenzi, C. Ring, F. Cassani, G. Ballardini, M. Briggs, R. S. Tedder, and F. B. Bianchi. 1991. Hepatitis C viraemia in adults with type 2 autoimmune hepatitis. *J. Med. Virol.* 34:223–226.
- Chomczynski, P., and N. Sacchi. 1987. Single-step method of RNA isolation by acid guanidinium thiocyanate-phenol-chloroform extraction. *Anal. Biochem.* 162:156–159.
- Kwok, S., and R. Higuchi. 1989. Avoiding false positives with PCR. *Nature (Lond.).* 339:237–238.
- Tisminetzky, S. G., M. Gerotto, P. Pontisso, L. Chemello, M. G. Bruvoletto, F. Baralle, and A. Alberti. 1994. Genotypes of hepatitis C virus in Italian patients with chronic hepatitis C. *Int. Hepatol. Commun.* 2:105–112.
- Simmonds, P., E. C. Holmes, T. A. Cha, and S. W. Chan. 1993. Classification of hepatitis C virus into six major genotypes and a series of subtypes by phylogenetic analysis of the NS-5 region. *J. Gen. Virol.* 74:2391–2399.
- Stuyver, L., R. Rossau, A. Wyseur, M. Duhamel, B. Vanderborght, H. Van Heuverswyn, and G. Maertens. 1993. Typing of hepatitis C virus isolates and characterization of new subtypes using a line probe assay. *J. Gen. Virol.* 74:1093–1102.
- Clark, H. F., and C. C. Shepard. 1963. A dialysis technique for preparing fluorescent antibody. *Virology.* 115:642–644.
- Krawczynski, K., M. J. Beach, D. W. Bradley, G. Kuo, A. Di Bisceglie, M. Houghton, G. R. Reyes, J. P. Kim, Q. L. Choo, and M. J. Alter. 1992. Hepatitis C virus antigen in hepatocytes: immunomorphological detection and identification. *Gastroenterology.* 103:622–629.
- Montano, L., G. C. Miescher, A. H. Goodall, K. H. Wiedemann, G. Janossy, and H. C. Thomas. 1982. Hepatitis B virus and HLA antigen display in the liver during chronic hepatitis B virus infection. *Hepatology.* 2:557–561.
- Hayata, T., Y. Nakano, K. Yoshizawa, T. Sodeyama, and K. Kiyosawa. 1991. Effects of interferon on intrahepatic human leukocyte antigens and lymphocyte subsets in patients with chronic hepatitis B and C. *Hepatology.* 13:1022–1028.
- Chayama, K., S. Saitoh, Y. Arase, K. Ikeda, T. Matsumoto, Y. Sakai, M. Kobayashi, M. Unakami, T. Morinaga, and H. Kumada. 1991. Effect of interferon administration on serum hepatitis C virus RNA in patients with chronic hepatitis C. *Hepatology.* 13:1040–1043.
- Unutmaz, D., P. Pileri, and S. Abrignani. 1994. Antigen-independent activation of naive and memory T cells by a cytokine combination. *J. Exp. Med.* 180:1159–1164.
- Bursch, W., S. Paffe, B. Putz, G. Barthel, and R. Schulte-Hermann. 1990. Determination of the length of the histological stages of apoptosis in normal liver and in altered hepatic foci of rats. *Carcinogenesis (Lond.).* 11:847–853.
- Koup, R. A. 1994. Virus escape from CTL recognition. *J. Exp. Med.* 180:779–782.
- Burgert, H., J. L. Maryanski, and S. Kvist. 1987. E3/19K protein of adenovirus type 2 inhibits lysis of cytolytic T lymphocytes by blocking cell-surface expression of histocompatibility class I antigens. *Proc. Natl. Acad. Sci. USA.* 84:1356–1360.
- Howcroft, T. K., K. Strelbel, M. A. Martin, and D. S. Singer. 1993. Repression of MHC class I gene promoter activity by two-exon tat of HIV. *Science (Wash. DC).* 260:1320–1322.
- Gregory, C. D., R. J. Murray, C. F. Edwards, and A. B. Rickinson. 1988. Downregulation of cell adhesion molecules LFA-3 and ICAM-1 in Epstein-Barr virus-positive Burkitt's lymphoma underlies tumor escape from virus-specific T cell surveillance. *J. Exp. Med.* 167:1811–1824.
- Sansonno, D., V. Cornacchiulo, P. Gatti, and F. Dammacco. 1992. Circulating levels and liver tissue distribution of intercellular adhesion molecule-1 during β -interferon therapy of hepatitis-C virus-associated chronic active liver disease. *Int. J. Clin. & Lab. Res.* 22:100–105.
- Kato, T., M. Esumi, S. Yamashita, K. Abe, and T. Shikata. 1992. Interferon inducible gene expression in chimpanzee liver infected with hepatitis C virus. *Virology.* 190:856–860.
- Calmus, Y., C. Arvieux, P. Gane, E. Boucher, B. Nordlinger, P. Rouger, and P. Poupon. 1992. Cholestasis induces major histocompatibility complex class I expression in hepatocytes. *Gastroenterology.* 102:1371–1377.
- Tsutsumi, M., S. Urashima, A. Takada, T. Date, and Y. Tanaka. 1994. Detection of antigens related to hepatitis C virus RNA encoding the NS5 region in the liver of patients with chronic type C hepatitis. *Hepatology.* 19:265–272.
- Idrovo, V., L. J. Jeffers, E. Coelho-Little, P. J. Dailey, L. Alvarez, M. S. Urdea, K. R. Reddy, T. Parker, and E. R. Schiff. 1993. HCV-RNA Quantitation in right and left lobes of the liver in patients with chronic hepatitis C. *Hepatology.* 18:80a. (Abstr.).