

## **Immunopathological mechanisms of human T cell lymphotropic virus type 1 (HTLV-I) uveitis. Detection of HTLV-I-infected T cells in the eye and their constitutive cytokine production.**

K Sagawa, ... , T Watanabe, K Itoh

*J Clin Invest.* 1995;**95**(2):852-858. <https://doi.org/10.1172/JCI117735>.

### **Research Article**

The immunopathology of human T cell lymphotropic virus type 1 (HTLV-I) uveitis was addressed by using T cell clones (TCC) established from the intraocular fluid of patients with HTLV-I uveitis. Proviral DNA of HTLV-I was identified in 55 out of 94 (59%) or 13 out of 36 (36%) TCC from the ocular fluid or the peripheral blood of these patients, respectively. Most of HTLV-I-infected TCC had a CD3+ CD4+ CD8- phenotype. HTLV-I infection on TCC was confirmed by analysis of the viral mRNA, nucleotide sequence, virus-associated proteins, and virus particles. HTLV-I-infected TCC, but not HTLV-I negative TCC, constitutively produced high amounts of IL-6 (1,336 +/- 1,050 pg/ml) and TNF-alpha (289 +/- 237 pg/ml) in the absence of any stimuli. HTLV-I-infected TCC from the ocular lesion also constitutively produced high amounts of IL-1 alpha (12,699 pg/ml), IL-2 (61 pg/ml), IL-3 (428 pg/ml), IL-8 (1,268 pg/ml), IL-10 (28 pg/ml), IFN-gamma (5,095 pg/ml), and GM-CSF (2,886 pg/ml). Hydrocortisone, a drug effective in vivo for the treatment of HTLV-I uveitis, severely depressed cytokine production in vitro in most cases. In summary, the results demonstrated direct evidence of HTLV-I infection of the eye and suggest that cytokines produced by HTLV-I-infected T cells are responsible for the intraocular inflammation in patients with HTLV-I uveitis.

**Find the latest version:**

<https://jci.me/117735/pdf>



# Immunopathological Mechanisms of Human T Cell Lymphotropic Virus Type 1 (HTLV-I) Uveitis

## Detection of HTLV-I-infected T Cells in the Eye and Their Constitutive Cytokine Production

Kimitaka Sagawa,\* Manabu Mochizuki,<sup>‡</sup> Kazuhiro Masuoka,\* Kazuko Katagiri,\* Takafumi Katayama,\* Tomoyuki Maeda,\* Akihide Tanimoto,<sup>§</sup> Sunao Sugita,<sup>‡</sup> Toshiki Watanabe,<sup>1</sup> and Kyogo Itoh\*

Departments of \*Immunology and <sup>‡</sup>Ophthalmology, Kurume University School of Medicine, Kurume, 830, Japan; <sup>§</sup>Department of Pathology, University of Occupational and Environmental Health School of Medicine, Kitakyushu, 807, Japan; and the <sup>1</sup>Department of Pathology, Institute of Medical Science, University of Tokyo, Tokyo, 108, Japan

### Abstract

The immunopathology of human T cell lymphotropic virus type 1 (HTLV-I) uveitis was addressed by using T cell clones (TCC) established from the intraocular fluid of patients with HTLV-I uveitis. Proviral DNA of HTLV-I was identified in 55 out of 94 (59%) or 13 out of 36 (36%) TCC from the ocular fluid or the peripheral blood of these patients, respectively. Most of HTLV-I-infected TCC had a CD3<sup>+</sup> CD4<sup>+</sup> CD8<sup>-</sup> phenotype. HTLV-I infection on TCC was confirmed by analysis of the viral mRNA, nucleotide sequence, virus-associated proteins, and virus particles. HTLV-I-infected TCC, but not HTLV-I negative TCC, constitutively produced high amounts of IL-6 (1,336±1,050 pg/ml) and TNF- $\alpha$  (289±237 pg/ml) in the absence of any stimuli. HTLV-I-infected TCC from the ocular lesion also constitutively produced high amounts of IL-1 $\alpha$  (12,699 pg/ml), IL-2 (61 pg/ml), IL-3 (428 pg/ml), IL-8 (1,268 pg/ml), IL-10 (28 pg/ml), IFN- $\gamma$  (5,095 pg/ml), and GM-CSF (2,886 pg/ml). Hydrocortisone, a drug effective in vivo for the treatment of HTLV-I uveitis, severely depressed cytokine production in vitro in most cases. In summary, the results demonstrated direct evidence of HTLV-I infection of the eye and suggest that cytokines produced by HTLV-I-infected T cells are responsible for the intraocular inflammation in patients with HTLV-I uveitis. (*J. Clin. Invest.* 1995. 95:852–858.) Key words: T cell clone • the ocular fluid • cytokine production • hydrocortisone

### Introduction

Human T cell lymphotropic virus type 1 (HTLV-I)<sup>1</sup> (1, 2) is a retrovirus endemic to some regions of the globe and causatively associated with adult T cell leukemia (3) and HTLV-I myelopathy (4, 5). We reported a new disease entity, HTLV-I uveitis, based on seroepidemiological, ophthalmological, and virologi-

cal studies in an HTLV-I endemic area in southwest Japan (6, 10). These studies demonstrated that: (a) the seroprevalence of HTLV-I in patients with idiopathic uveitis was significantly higher than that in patients with uveitis with defined etiology or that in patients with non-uveitic ocular diseases; (b) the ocular manifestations of HTLV-I uveitis were characterized by moderate to severe vitreous opacities with mild iritis and mild retinal vasculitis; and (c) the proviral DNA of HTLV-I was detected by PCR method in cells from the aqueous humor.

However, there have been no reports showing direct evidence that either HTLV-I associated proteins or HTLV-I viral particles are present in the T cells of inflammatory eye lesions of patients with HTLV-I uveitis, primarily due to the limited number of cells available from the eye. Subsequently, the immunopathology of HTLV-I uveitis is yet to be addressed. In this study, we have expanded T cells in vitro from the intraocular fluid of patients with HTLV-I uveitis and characterized HTLV-I infection and cytokine production by these T cells to understand the immunopathogenic mechanisms of the disease.

### Methods

#### Materials

The following is a brief clinical history of the three patients whose intraocular fluid (aqueous and/or vitreous humor) and PBMC were used in this study. Informed consent was given by these patients before the samples were obtained. The research followed the tenets of the Declaration of Helsinki.

*Patient 1 (HTLV-I uveitis).* A 45-yr-old female patient was referred to the Kurume University Hospital Eye Clinic on 14 January 1993, complaining of sudden onset of blurred vision and floaters in her left eye. Ocular examination disclosed moderate vitreous opacities with iritis and retinal vasculitis in the left eye. All routine diagnostic examinations were negative except for the positive serum antibody to HTLV-I (1:1,024). The patient had neither adult T cell leukemia nor HTLV-I myelopathy. Based on these ophthalmic and systemic examinations, this uveitis was diagnosed as HTLV-I uveitis. Aqueous humor (0.1 ml) and heparinized peripheral blood were taken on January 26 before the treatment.

*Patient 2 (HTLV-I uveitis).* A 24-yr-old male patient was referred to the Miyata Eye Hospital on 19 July 1991, complaining of sudden onset of foggy vision and floaters in the left eye. Ocular examination disclosed severe vitreous opacities with moderate iritis and retinal vasculitis in the left eye. All routine diagnostic investigations were negative, except for the positive serum antibody to HTLV-I (1:256). The uveitis was diagnosed as HTLV-I uveitis. An aliquot (0.05 ml) of the vitreous humor and heparinized peripheral blood were taken at the time of the fifth episode of uveitis on 14 January 1994 at Kurume University.

*Patient 3 (Behçet's disease).* A 43-yr-old male patient was referred to the Kurume University Hospital Eye Clinic on 2 October 1990, complaining of sudden onset of floaters and decreased vision in both eyes. Ocular examination disclosed intense retinal vasculitis with hemor-

Address correspondence to Kyogo Itoh, M.D., Department of Immunology, Kurume University School of Medicine, 67 Asahi-machi, Kurume, 830, Japan. Phone: 942-31-7551; FAX: 942-31-7699.

Received for publication 19 September 1994.

1. Abbreviations used in this paper: HTLV-I, human T cell lymphotropic virus type 1; TCC, T cell clones.

*J. Clin. Invest.*

© The American Society for Clinical Investigation, Inc.

0021-9738/95/02/0852/07 \$2.00

Volume 95, February 1995, 852–858

## T CELL CLONES

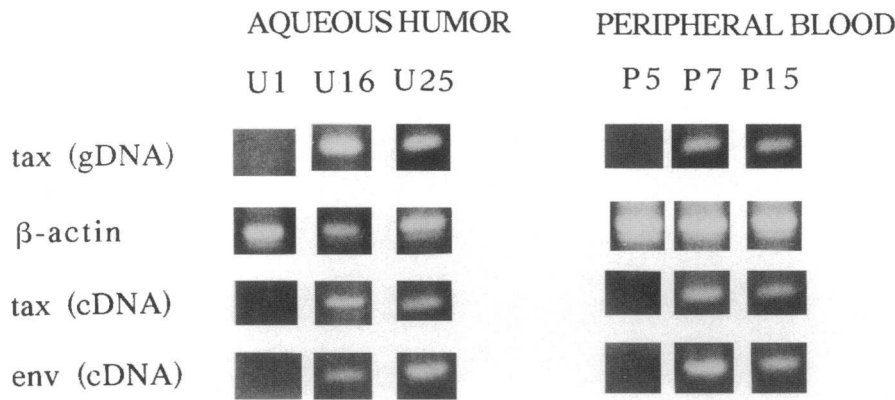


Figure 1. HTLV-I expression on the TCC from patient 1. HTLV-I *tax* and *env* gene expression on six (three from aqueous humor and three from PBMC) TCC were investigated at the proviral DNA (*gDNA*, genomic DNA) and mRNA (*cDNA*) levels by PCR and reverse transcription PCR methods, respectively. U16, U25, P7, and P15 TCC were positive for HTLV-I, whereas U1 and P5 TCC were negative.

rhages and white exudates in the peripheral retina with minimum vitreous opacities in either eye. The patient had episodes of recurrent uveitis, oral aphthous ulcers, and erythema nodosum-type skin lesions. Despite the fact that the patient was an HTLV-I carrier (the antibody titer, 1:2,048), the systemic and ocular symptoms of the patient met the diagnostic criteria for Behçet's disease established by the Japan Behçet's Disease Research Committee of the Japanese Ministry of Health and Welfare, Tokyo, Japan (11). The uveitis was diagnosed as uveitis associated with Behçet's disease. The aqueous humor (0.1 ml), the vitreous humor (0.2 ml), and the heparinized peripheral blood were collected during the surgery.

### Expansion of T cells and T cell markers

T cells were expanded by the limiting dilution method as reported previously (12). Briefly, cells from the ocular fluid or PBMC were plated at 1 cell per well in 96-well U-bottom tissue culture plates (Falcon Labware, Lincoln Park, NJ) in the presence of  $2 \times 10^5$  X-irradiated (50 Gy) allogeneic PBMC obtained from healthy volunteers (HTLV-I negative) as feeder cells, 100 U/ml human recombinant IL-2, 10  $\mu$ g/ml PHA-P (Difco Laboratories Inc., Detroit, MI) in RPMI 1640 medium (Gibco Laboratories, Grand Island, NY) supplemented with 100 U/ml penicillin G, 50  $\mu$ g/ml streptomycin, and 10% heat-inactivated FCS (Filtron, Brooklyn, Australia). The plated cells were incubated in humidified 5% CO<sub>2</sub> in air at 37°C. Then,  $2 \times 10^5$  X-irradiated allogeneic PBMC were added to each well along with 100 U/ml recombinant IL-2 every 7 d until an outgrowth of cells was observed.

Surface marker analysis of the proliferating cells was carried out by direct immunofluorescence method using FITC-conjugated mouse mAb, NU-T3 (CD3; Nichirei, Tokyo, Japan), NU-Th/i (CD4; Nichirei), NU-Ts/c (CD8; Nichirei), B4 (CD19; Coulter, Hialeah, FL), or anti-HLA-DR (Becton Dickinson, Mountain View, CA). Anti-Tac mAb (CD25) or Mik- $\beta$ 1 mAb (CD122; Nichirei) was used as the primary reagent in the indirect immunofluorescence method utilizing FITC-conjugated goat IgG against mouse IgG (Tago, Inc., Burlingame, CA) as the secondary reagent. The stained cells were analyzed by FACScan® flow cytometry (Becton Dickinson Immunocytometry Systems, San Jose, CA).

The cells showing a uniform T cell phenotype (i.e., a CD3<sup>+</sup> CD4<sup>+</sup> CD8<sup>-</sup> or a CD3<sup>+</sup> CD4<sup>-</sup> CD8<sup>+</sup> phenotype) were considered potential T cell clones (TCC) and were used in this study. The clonality of these potential TCC was investigated by sequencing T cell receptor  $\alpha$  and  $\beta$  genes, and the majority of them used a single T cell receptor as reported previously (13).

### Detection of proviral DNA of the HTLV-I *tax* gene

2  $\mu$ l of  $2 \times 10^6$  cells per ml cell suspension was added to 20  $\mu$ l of the lysing buffer (2% Triton X-100 buffer and 10 mM Tris-HCl, pH 9.3), and was vortexed for 30 s. Proviral DNA for the HTLV-I *tax* gene was

amplified using the PCR method and the following *tax* gene specific primers: 5'-CGGATACCCAGTCTACGTGT-3' (forward primer, nucleotide positions 7336-7355) and 5'-GAGCCGATAACGCGTCCA-TCG-3' (reverse primer, nucleotide position 7494-7474) (Takara Shuzo, Kyoto, Japan). The products were subjected to PCR in the presence of the primers (1 pmol), 200 mM deoxynucleotide triphosphates, and 2.5 U of *Taq* polymerase in a buffer containing 50 mM KCl and 1.5 mM MgCl<sub>2</sub>. Samples were subjected to 35 cycles of amplification consisting of denaturation for 1 min at 94°C, annealing for 1 min at 53°C, and polymerization for 1 min at 72°C. The PCR products were analyzed using agarose gel electrophoresis and ethidium bromide staining.

### Detection of HTLV-I gene expression at the mRNA level and nucleotide sequencing

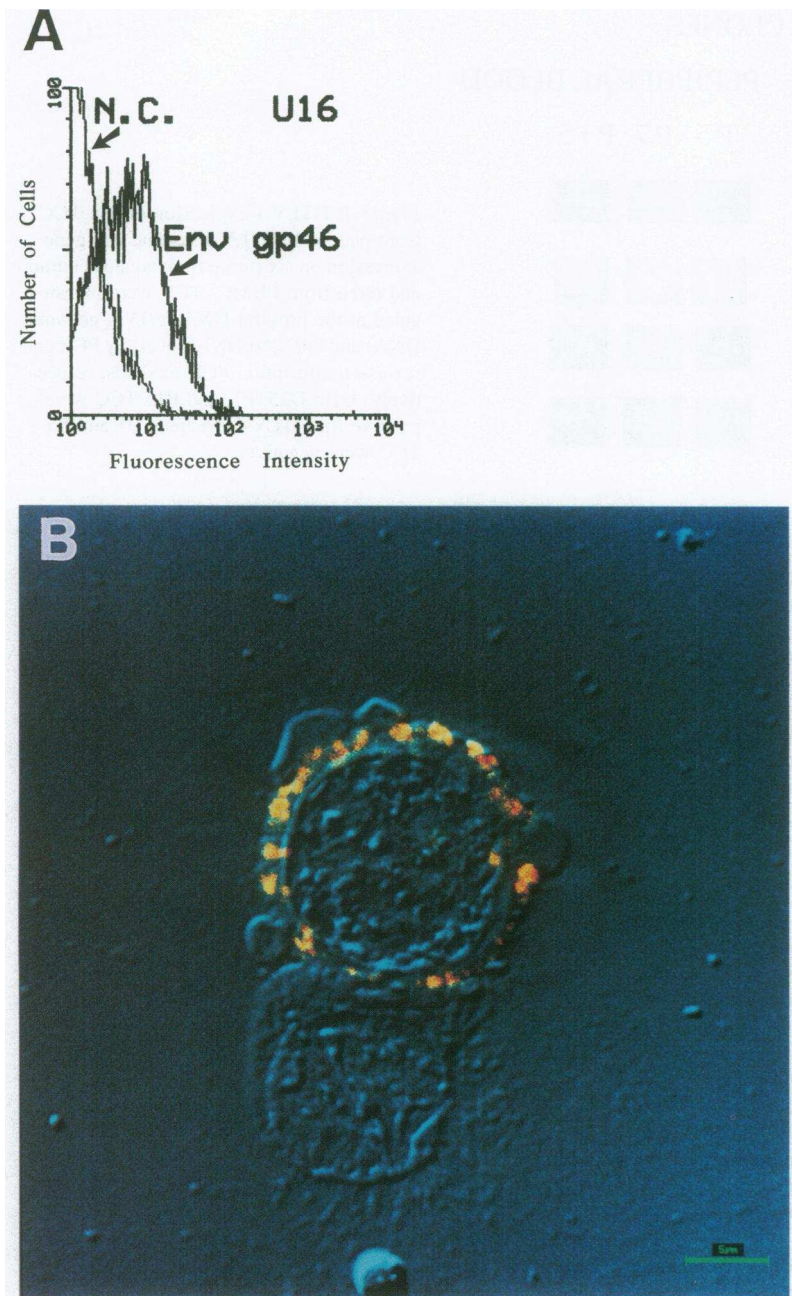
Total RNA was harvested by lysis of  $1 \times 10^7$  cells using RNAzol® B (Biotec Laboratories, Inc., Houston, TX) according to the manufacturer's instruction. 3 mg of total RNA was mixed with random hexamers (GIBCO BRL, Gaithersburg, MD) and SuperScript-reverse transcriptase™ (GIBCO BRL) and incubated at 37°C for 60 min to obtain cDNA. The cDNA was then subjected to PCR as described above in the presence of 1 pmol of *tax* gene primers (forward primer: 5'-CAGGAGGCTCTC-CAAGAAGCT-3', reverse primer: 5'-AAACACGTAGACTGGGTA-TCC-3') or *env* gene primers (forward primer: 5'-TGTGGTGCCTCC-TGAAGTGGC-3', reverse primer: 5'-CAGCAGCTGGGGCTGTAA-TCA-3'). The amplified product of the cDNA *tax* gene was also cloned using TA cloning system (Invitrogen, San Diego, CA) followed by cDNA sequencing with an Auto Read™ sequencing kit and auto DNA sequencer (Pharmacia AB, Uppsala, Sweden) according to the manufacturers' instructions.

### Detection of HTLV-I associated proteins

HTLV-I proteins were examined on the cells by immunofluorescence technique using MET-3 mAb (anti-env gp46) (14), TA21 mAb (anti-env gp21) (15), NOR-1 mAb (anti-gag p24) (16), GIN-14 mAb (anti-gag p19) (17), or Lt-4 mAb (anti-p40 tax) (18). Pictures of fluorescence-positive cells were taken by a confocal laser scanning microscope (LSM 310UV; Carl Zeiss, Oberkochen, Germany).

### Electron microscopic analysis

U16 HTLV-I-infected TCC were fixed with phosphate-buffered (0.1 M, pH 7.4) 2.5% glutaraldehyde for 2 h at 4°C. Immediately after postfixation in phosphate-buffered 1% osmium tetroxide, the cells were dehydrated and embedded in Epon 812 resin. Ultrathin sections of these samples were stained with uranyl acetate and lead acetate. Specimens were examined on an electron microscope (JEM-100S; Hitachi, Tokyo, Japan).



**Figure 2.** Detection of HTLV-I env protein on a TCC. (A) Expression of HTLV-I env gp46 on the cell surface of U16 clone was detected by immunofluorescence methods. *N.C.*, negative control (reactivity with an isotype-matched irrelevant mAb). (B) Expression of HTLV-I gag p19 in cytoplasm of U16 clone was detected by immunofluorescence methods. The picture was taken by integrating an interference microscopic picture and a confocal laser scanning microscopic image of fluorescence-positive U16 cells. An upper U16 cell was positive, while a lower U16 cell showed negative reaction.

#### Cytokine assay

TCC were washed twice with RPMI 1640 medium and then were cultivated at  $1 \times 10^6$ /ml in the medium with 10% FCS alone in 24-well tissue culture plates for 20 h. Cell-free culture supernatants were obtained by centrifugation of the cells and stored at  $-80^\circ\text{C}$  until use. The ELISA kits used to detect cytokines were: IL-6 kit (sensitivity  $> 5$  pg/ml; Immunotech, Marseilles, France), TNF- $\alpha$  kit ( $> 5$  pg/ml; Immunotech), IL-1 $\alpha$  kit ( $> 3$  pg/ml; Cayman Chemical Co., Inc., Ann Arbor, MI), IFN- $\gamma$  kit ( $> 5$  pg/ml; Endogen, Inc., Boston, MA), IL-2 ( $> 9$  pg/ml; Biosource International, Camarillo, CA), IL-10 ( $> 5$  pg/ml; Biosource International), GM-CSF ( $> 2$  pg/ml; R&D Systems, Inc., Minneapolis, MN), IL-3 ( $> 8$  pg/ml; R&D Systems, Inc.), and IL-4 ( $> 3$  pg/ml; Amersham Life Science, Tokyo, Japan). IL-8 was also measured by a kit kindly provided by Dr. N. Mukaida (Kanazawa University, Kanazawa, Japan) as reported previously (sensitivity  $> 16$  pg/ml) (19).

#### Statistical analysis

Statistical analysis was performed by an unpaired *t* test or a paired *t* test.

#### Results

**HTLV-I infection on T cells at the proviral DNA level.** Proviral DNA of HTLV-I *tax* gene was detected in 10 out of 34 (29%) or 12 out of 25 (48%) TCC, respectively, from the aqueous humor or peripheral blood of patient 1 with HTLV-I uveitis. Representative results of the gels are shown in Fig. 1. The proviral DNA was detected in 45 out of 60 (75%) or 1 out of 11 (9%) TCC from the vitreous humor or the peripheral blood

of patient 2 with HTLV-I uveitis. In contrast, the proviral DNA was not detected in any of 37 TCC from the intraocular fluid (14 from aqueous humor or 23 from vitreous humor) of patient 3 with Behçet's disease. It was detected in only 1 out of 32 TCC from PBMC of patient 3.

These TCC primarily displayed a CD3<sup>+</sup> CD4<sup>+</sup> CD8<sup>-</sup> phenotype, regardless of the presence or absence of HTLV-I proviral DNA. Namely, TCC from 12 out of 18 or 9 out of 15 TCC tested from the aqueous humor or the peripheral blood of patient 1 had a CD3<sup>+</sup> CD4<sup>+</sup> CD8<sup>-</sup> phenotype, respectively. Those from 58 out of 61 or 9 out of 11 TCC tested from the vitreous humor or the peripheral blood of patient 2 also had a CD3<sup>+</sup> CD4<sup>+</sup> CD8<sup>-</sup> phenotype, respectively. The other TCC had a CD3<sup>+</sup> CD4<sup>-</sup> CD8<sup>+</sup> phenotype. It is noteworthy that two TCC with a CD3<sup>+</sup> CD4<sup>-</sup> CD8<sup>+</sup> phenotype from PBMC of patient 1 were positive for HTLV-I proviral DNA (P7 in Fig. 1 and P16; data not shown). All of them expressed HLA-DR antigens except the CD19 B cell antigen. 5 of 11 TCC (4 HTLV-I provirus<sup>+</sup> and 1 HTLV-I provirus<sup>-</sup>) expressed CD25 (IL-2R $\alpha$ ) antigens, while none of them showed CD122 (IL-2R $\beta$ ) antigen. The majority of TCC from patient 3 with Behçet's disease also had a CD3<sup>+</sup> CD4<sup>+</sup> CD8<sup>-</sup> phenotype.

**HTLV-I infection at the mRNA and protein levels.** All HTLV-I provirus<sup>+</sup> TCC tested strongly expressed both *env* and *tax* genes at the mRNA level. Representative results are shown in the third and fourth lanes of Fig. 1. HTLV-I provirus<sup>-</sup> TCC failed to express these genes (Fig. 1). cDNA from a portion of the *tax* gene (from position 5029 to position 7357) was sequenced. The cDNA from two different HTLV-I-infected TCC (U16 and U33) was identical and possessed the HLA-A2 binding motif (data not shown) (20–22). There was one nucleotide-substitution (A→T) at the 5171 position of the HTLV-I gene as compared with the nucleotides reported by Seiki et al. (20).

The vast majority of HTLV-I provirus<sup>+</sup> TCC tested expressed all gag p19 (Table I), gag p24, env gp46, env gp21, and tax p40 proteins (data not shown), as determined using a relevant mAb and immunofluorescence technique. One representative histogram of env gp46 protein (Fig. 2 A) and a picture of a gag p19 positive TCC in cytoplasm taken by a confocal laser scanning microscope (Fig. 2 B) are shown. It is important to note that a CD3<sup>+</sup> CD4<sup>-</sup> CD8<sup>+</sup> TCC (P7) expressed gag p24, gag p19, and tax p40 but not env gp46 or env gp21 protein. In contrast, none of these proteins were observed in HTLV-I provirus<sup>-</sup> TCC (Table I).

**Detection of HTLV-I virus particles.** One HTLV-I-infected TCC (U16) was provided for electron microscopic analysis to detect HTLV-I virus particles. Virus particles characteristic of HTLV-I virus reported by Poesz et al. (1) and by Hinuma et al. (2) were observed on the cell surface of the U16 clones (Fig. 3). Multiple particles were observed on 2–3% of the U16 clones (Fig. 3 A). Several particles were observed on 10–15% of the U16 clones (Fig. 3 B). The average diameter of the 21 intact particles observed was 102.7 nm.

**Cytokine production.** IL-6 and TNF- $\alpha$  production was measured in the culture supernatants from 9 (5 HTLV-I<sup>+</sup> and 4 HTLV-I<sup>-</sup>, patient 1) or 24 (14 HTLV-I<sup>+</sup> and 10 HTLV-I<sup>-</sup>, patient 2) TCC (Table I). All HTLV-I-infected TCC produced greater amounts (235–4,002 pg/ml) of IL-6, and the mean $\pm$ SD ( $n = 19$ ) was 1,336 $\pm$ 1,050 pg/ml ( $P < 0.002$  versus that by HTLV-I negative TCC). In contrast, HTLV-I negative TCC produced either undetectable levels (< 5 pg/ml, 5 clones) or very low levels (5–68 pg/ml, 9 clones) of IL-6. HTLV-I-in-

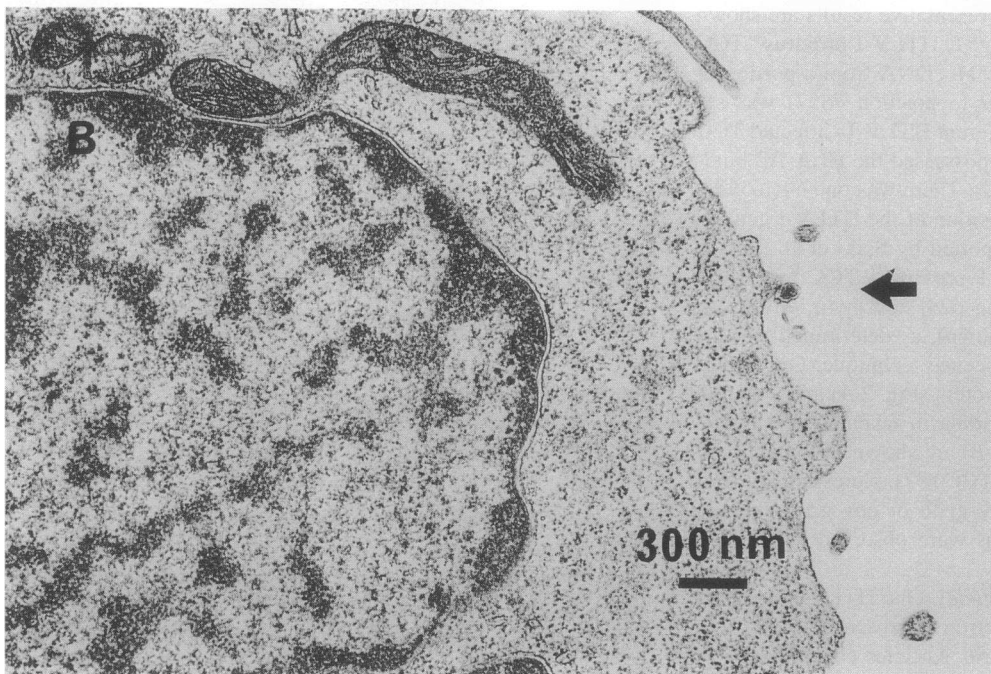
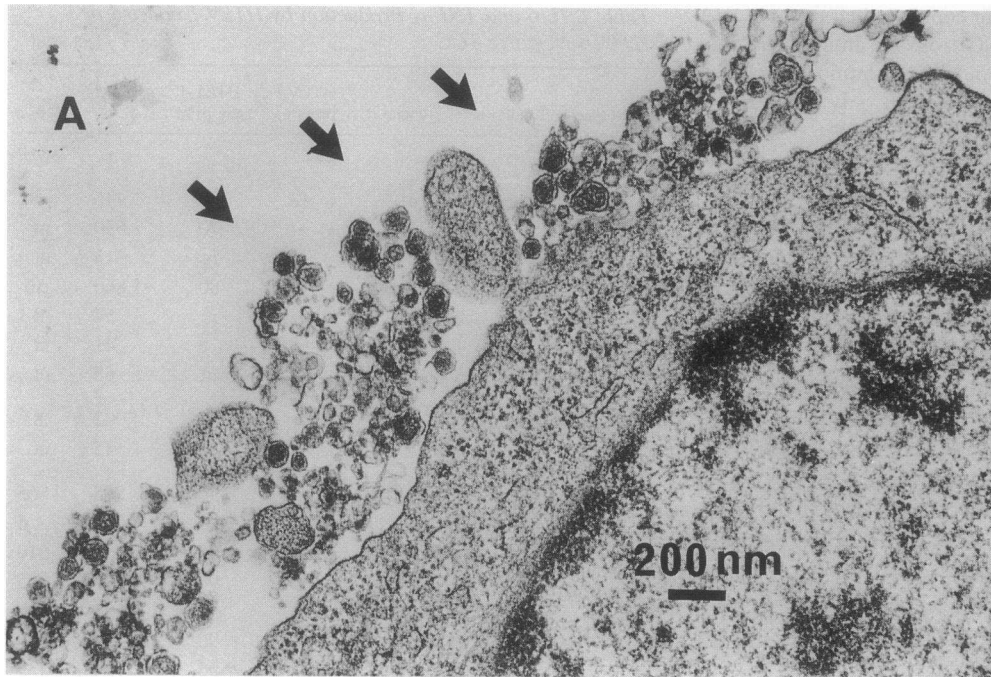
Table I. IL-6 and TNF- $\alpha$  Production by HTLV-I-infected or HTLV-I Negative TCC

Source of T cells	Clone	HTLV-I provirus	HTLV-I gag p19*	IL-6		TNF- $\alpha$	
				pg/ml	pg/ml	pg/ml	pg/ml
Aqueous humor of patient 1	U16	+	80	1,446	82		
	U25	+	70	2,030	nt <sup>†</sup>		
	U33	+	nt	313	nt		
	U64	+	80	1,860	56		
	U1	-	nt	57	nt		
	U10	-	0	41	nt		
	U68	-	nt	68	nt		
PBMC of patient 1	P7 <sup>§</sup>	+	80	4,002	8		
	P5	-	nt	45	nt		
Vitreous humor of patient 2	V230-20	+	90	865	565		
	V230-23	+	60	281	<5		
	V230-40	+	90	1,039	610		
	V230-43	+	90	447	175		
	V230-47	+	80	542	266		
	V230-49	+	90	394	279		
	V230-53	+	90	774	533		
	V230-55	+	90	3,273	107		
	V230-60	+	80	629	97		
	V230-66	+	80	235	186		
	V230-80	+	80	1,655	521		
	V230-81	+	80	2,311	773		
	V230-83	+	80	1,334	413		
	V230-5	-	0	<5	<5		
	V230-10	-	0	13	<5		
	V230-13	-	0	<5	<5		
V230-33	-	0	<5	<5			
V230-42	-	0	<5	40			
V230-75	-	0	7	<5			
V230-78	-	0	<5	<5			
PBMC of patient 2	P232-1	+	nt	1,958	240		
	P232-4	-	nt	5	<5		
	P232-5	-	nt	17	6		
	P232-12	-	nt	19	115		

HTLV-I provirus<sup>+</sup> ( $n = 19$ ) or provirus<sup>-</sup> TCC ( $n = 14$ ) established from aqueous or vitreous humor or PBMC were tested for their expression of gag p19 protein using anti-p19 mAb and immunofluorescent technique. These TCC ( $1 \times 10^6$  cells/ml) were incubated with RPMI 1640 medium plus 10% FCS alone for 20 h in the absence of any stimuli. Cell-free supernatants were measured for IL-6 and TNF- $\alpha$  activity using ELISA kits. The limits of sensitivity were 5 pg/ml. For the statistical analysis (an unpaired  $t$  test), the values <5 pg/ml were calculated as 5 pg/ml. \* Percentage of positive cells. <sup>†</sup> Not tested. <sup>§</sup> Surface marker of P7 clone was CD3<sup>+</sup> CD4<sup>-</sup> CD8<sup>+</sup>, while that of the other clones was CD3<sup>+</sup> CD4<sup>+</sup> CD8<sup>-</sup>.

ected TCC also produced TNF- $\alpha$ , ranging from 8 to 773 pg/ml, and the mean $\pm$ SD ( $n = 17$ ) was 282 $\pm$ 245 pg/ml ( $P < 0.02$  versus that by HTLV-I negative TCC) (Table I). In contrast, 7 out of the 10 HTLV-I negative TCC produced undetectable levels (< 5 pg/ml) of TNF- $\alpha$ , and the others produced lower levels (6, 40, and 115 pg/ml) of TNF- $\alpha$ .

HTLV-I-infected TCC established from the ocular fluid



**Figure 3.** HTLV-I virus particles on a TCC. HTLV-I virus particles on U16 clone were detected by electron microscopic analysis. Arrows indicate virus particles. (A) Multiple virus particles were observed on a U16 cell. (B) A single virus particle was observed on another U16 cell.

also produced significant amounts of various cytokines in the absence of any stimuli (Table II). The mean values of cytokines produced by 5 HTLV-I-infected TCC were as follows: 12,699 pg/ml IL-1 $\alpha$ , 61 pg/ml IL-2, 428 pg/ml IL-3, 8,358 pg/ml IL-6, 1,268 pg/ml IL-8, 28 pg/ml IL-10, 272 pg/ml TNF- $\alpha$ , 5,095 pg/ml IFN- $\gamma$ , and 2,886 pg/ml GM-CSF. In contrast, no TCC produced detectable levels ( $> 3$  pg/ml) of IL-4.

Hydrocortisone, a drug used for the treatment of HTLV-I uveitis, severely suppressed the constitutive production of IL-1 $\alpha$ , IL-3, IL-6 ( $P < 0.05$ ), IL-8, IL-10, TNF- $\alpha$ , and IFN- $\gamma$  ( $P < 0.02$ ) (Table II). It did not inhibit the production of GM-CSF, but slightly increased IL-2 production ( $P < 0.05$ ) instead.

## Discussion

This study focused primarily on detection of HTLV-I-infected T cells of the eye in patients with HTLV-I uveitis. HTLV-I proviral DNA was identified in 55 out of 94 (59%) TCC (10 out of 34 from aqueous humor and 45 out of 60 from vitreous humor of the 2 patients with HTLV-I uveitis). The majority of TCC had a CD3<sup>+</sup> CD4<sup>+</sup> CD8<sup>-</sup> phenotype, and each TCC used a single T cell receptor  $\alpha$  usage as reported elsewhere (13). Using these TCC, HTLV-I infection was demonstrated by analyzing gene expression at the mRNA level, nucleotide sequence, virus-associated proteins, and virus particles. Therefore, the

Table II. Suppression of Cytokine Production of HTLV-I-infected TCC by Hydrocortisone

Cytokine	Cytokine production (mean±1 SD, pg/ml) by HTLV-I-infected TCC (n = 5) in the presence of		P values
	Medium	Hydrocortisone (1 μM)	
IL-1α	12699±16549	7974±10176	NS
IL-2	61±8	95±24	<0.05
IL-3	428±57	128±25	NS
IL-4	0	0	
IL-6	8358±707	4713±4574	<0.05
IL-8	1268±544	926±602	NS
IL-10	28±28	6±8	NS
TNF-α	272±185	145±83	NS
IFN-γ	5095±2748	2019±1905	<0.02
GM-CSF	2886±641	2438±807	NS

Five HTLV-I-infected TCC established from ocular fluid (U16, U64, V230-80, -81, and -83) were incubated with RPMI 1640 medium plus 10% FCS alone or in the presence of 1 μM hydrocortisone for 20 h. Cell-free supernatants were tested for the cytokine production using ELISA kits. Values represent the mean±1 SD of five TCC. P values were analyzed using the paired t test. Up to 10 μM hydrocortisone did not affect the standard curve of each ELISA (data not shown).

present results provide direct evidence that significant numbers of HTLV-I-infected T cells infiltrate into the intraocular inflammation of HTLV-I uveitis. In contrast, there were no HTLV-I-infected TCC in the intraocular fluid from patient 3 with Behçet's uveitis who was seropositive to HTLV-I.

T cells were also expanded from PBMC of the same patients to better understand the immunopathology of HTLV-I uveitis. Substantial numbers of HTLV-I-infected T cells were observed in the circulation of patient 1, but not patient 2. We have observed that the percentages of HTLV-I-infected cells in PBMC in patients with HTLV-I uveitis (n = 28) ranged from 0.1 to 11% based upon a quantitative PCR study (Ono, A., M. Mochizuki, K. Yamaguchi, N. Miyata, and T. Watanabe, unpublished results). PBMC from 20 out of 28 patients with HTLV-I uveitis had > 1% of infected cells. These results suggest that a significant number of HTLV-I-infected T cells in the circulation is necessary for onset of HTLV-I uveitis in most cases.

There were no HTLV-I-infected T cells in the ocular fluid of a seropositive patient of the uveitis associated with Behçet's disease. These results suggest that uveitis does not precede the infiltration of HTLV-I-infected T cells into the eye in asymptomatic HTLV-I carriers. Instead, the infiltration of HTLV-I-infected T cells may precede HTLV-I uveitis. We have reported the polyclonal usage of T cell receptor α on these HTLV-I-infected TCC in the eye (13). These results suggest a possibility that large numbers of HTLV-I-infected T cells cross the blood ocular barrier, rather than a possibility that a single HTLV-I-infected T cell crosses the barrier and proliferates in the eye at the clonal level. However, the mechanisms by which HTLV-I-infected T cells accumulate in the eye are unknown and should be investigated in the future.

Secondly, this study focused on the involvement of cytokines produced by HTLV-I-infected T cells in intraocular inflammation. HTLV-I-infected TCC, but not HTLV-I negative

TCC, from the patients with HTLV-I uveitis constitutively produced IL-1α, IL-2, IL-3, IL-6, IL-8, IL-10, IFN-γ, TNF-α, and GM-CSF in the absence of any stimuli. They are potent cytokines capable of inducing immune reactions and inflammation at the tissue level (23–30). T cells transformed by HTLV-I have been reported to induce and secrete a variety of cytokines including IL-1, IL-2, IL-3, IL-6, TNF, and IFN-γ (31–34). In particular, IL-6 is a typical multifunctional cytokine with numerous biological activities, including hemopoiesis and acute phase responses (23, 26, 30). TNF-α appears to be responsible for the pathogenesis of vasculitis in addition to its numerous biological activities (24, 25, 28).

Hydrocortisone was effective in suppressing the production of all the cytokines produced by these HTLV-I-infected TCC except GM-CSF and IL-2. This finding was in agreement with our clinical experience reported previously (8, 9). Namely, systemic or topical administration of corticosteroids was markedly effective in treating intraocular inflammation of HTLV-I uveitis.

In summary, these studies detected HTLV-I proteins and virus particles in T cells from intraocular inflammatory lesion of patients with HTLV-I uveitis. Cytokines constitutively produced by HTLV-I-infected T cells are thought to be responsible for the pathogenesis of HTLV-I uveitis.

## Acknowledgments

We would like to express our deep appreciation to T. Yoshida of Shionogi Research Laboratories for providing recombinant IL-2; and to Dr. T. Uchiyama of Kyoto University, Dr. Y. Hinuma of Shionogi Institute for Medical Science, and Dr. Y. Takana of Kitasato University for their generous gifts of anti-Tac monoclonal antibody, GIN-14 monoclonal antibody, and anti-HTLV-I associated protein antibodies, respectively. We would also like to express our appreciation to Dr. T. Inokuchi of Kurume University for his technical assistance with the confocal laser scanning microscopic photography.

This study was supported in part by grants from the following organizations in Japan: a Grant-in-Aid for Scientific Research from the Ministry of Education, Science and Culture, a grant from the Ministry of Health and Welfare's Comprehensive 10-yr Strategy for Cancer Control, a Grant-in-Aid for Research by the Ishibashi Foundation, and grants from the Mitsubishi Foundation and the Fukuoka Cancer Society.

## References

- Poiesz, B. J., F. W. Ruscetti, A. F. Gazdar, P. A. Bunn, J. D. Minna, and R. C. Gallo. 1980. Detection and isolation of type C retrovirus particles from fresh and cultured lymphocytes of a patient with cutaneous T cell lymphoma. *Proc. Natl. Acad. Sci. USA.* 77:7415–7419.
- Hinuma, Y., K. Nagata, M. Hanaoka, M. Nakai, T. Matsumoto, K. I. Kinoshita, S. Shirakawa, and I. Miyoshi. 1981. Adult T cell leukemia: antigen in an ATL cell line and detection of antibodies to antigen in human sera. *Proc. Natl. Acad. Sci. USA.* 78:6476–6480.
- Uchiyama, T., J. Yodoi, K. Sagawa, K. Takatsuki, and H. Uchino. 1977. Adult T cell leukemia: clinical and hematologic features of 16 cases. *Blood.* 50:481–492.
- Gessain, A., F. Barin, J. C. Vernant, O. Gout, A. Calender, and G. de The. 1985. Antibodies to the human T-lymphotropic virus type-I in patients with tropical spastic paraparesis. *Lancet.* ii:407–410.
- Osame, M., K. Usuku, S. Izumo, N. Ijichi, A. Hiroyoko, A. Igata, M. Matsumoto, and M. Tara. 1986. HTLV-I associated myelopathy, a new clinical entity. *Lancet.* i:1031–1032.
- Mochizuki, M., K. Yamaguchi, K. Takatsuki, T. Watanabe, S. Mori, and K. Tajima. 1992. HTLV-I and uveitis. *Lancet.* 339:1110.
- Mochizuki, M., T. Watanabe, K. Yamaguchi, K. Takatsuki, K. Yoshimura, M. Shirao, S. Nakashima, S. Mori, S. Arai, and N. Miyata. 1992. HTLV-I uveitis: a distinct clinical entity caused by HTLV-I. *Jpn. J. Cancer Res.* 83: 236–239.
- Mochizuki, M., T. Watanabe, K. Yamaguchi, K. Yoshimura, S. Nakashima, M. Shirao, S. Araki, K. Takatsuki, S. Mori, and N. Miyata. 1992. Uveitis associ-

- ated with human T-cell lymphotropic virus type I. *Am. J. Ophthalmol.* 114:123-129.
9. Yoshimura, K., M. Mochizuki, S. Araki, N. Miyata, K. Yamaguchi, K. Tajima, and T. Watanabe. 1993. Clinical and immunological features of human T-cell lymphotropic virus type I uveitis. *Am. J. Ophthalmol.* 116:156-163.
10. Mochizuki, M., K. Tajima, T. Watanabe, and K. Yamaguchi. 1994. Human T lymphotropic virus type I uveitis. *Br. J. Ophthalmol.* 78:149-154.
11. Mizushima, Y., G. Inaba, Y. Miura, S. Ohno, and T. Matsuda. 1987. Diagnostic criteria for Behçet's disease. In Annual Report of Behçet's Disease Research Committee. The Ministry of Health and Welfare, Tokyo. 1987:8-29.
12. Itoh, K., C. D. Platsoucas, and C. M. Balch. 1988. Autologous tumor-specific cytotoxic T lymphocytes in the infiltrate of human metastatic melanomas. Activation by interleukin 2 and autologous tumor cells, and involvement of the T cell receptor. *J. Exp. Med.* 168:1419-1441.
13. Masuoka, K., K. Sagawa, M. Mochizuki, K. Oizumi, and K. Itoh. 1995. Polyclonal usage of T cell receptor (TCR)  $\alpha$  for human T-cell lymphotropic virus type 1 (HTLV-I) infected T cells in a patient with HTLV-I uveitis. *Invest. Ophthalmol. & Visual Sci.* In press.
14. Tanaka, Y., M. Yasumoto, H. Nyunoya, T. Ogura, M. Kikuchi, K. Shimotohno, H. Shiraki, N. Kuroda, H. Shida, and H. Tozawa. 1990. Generation and characterization of monoclonal antibodies against multiple epitopes of the C-terminal half of envelope gp46 of human T-cell leukemia virus type-I(HTLV-I). *Int. J. Cancer.* 46:675-681.
15. Sugamura, K., M. Fujii, S. Ueda, and Y. Hinuma. 1984. Identification of a glycoprotein, gp21, of adult T cell leukemia virus by monoclonal antibody. *J. Immunol.* 132:3180-3184.
16. Fujii, M., K. Sugamura, and Y. Hinuma. 1984. A monoclonal antibody that defines p24, a core protein of adult T-cell leukemia virus, and its precursor. *Gann.* 75:595-602.
17. Tanaka, Y., Y. Koyanagi, T. Chosa, N. Yamamoto, and Y. Hinuma. 1983. Monoclonal antibodies reactive with both p28 and p19 of adult T-cell leukemia virus-specific polypeptides. *Gann.* 74:327-330.
18. Lee, B., Y. Tanaka, and H. Tozawa. 1989. Monoclonal antibody defining tax 1 protein of human T-cell leukemia virus type-I. *Tohoku J. Exp. Med.* 157:1-11.
19. Ko, Y.-C., N. Mukaida, S. Ishiyama, A. Tokue, T. Kawai, K. Matsushima, and T. Kasahara. 1993. Elevated interleukin-8 levels in the urine of patients with urinary tract infections. *Infec. Immun.* 61:1307-1314.
20. Seiki, M., S. Hattori, Y. Hirayama, and M. Yoshida. 1983. Human adult T-cell leukemia virus: complete nucleotide sequence. *Natl. Acad. Sci. USA.* 80:3618-3622.
21. Seiki, M., A. Hikikoshi, T. Taniguchi, and M. Yoshida. 1985. Expression of the px gene of HTLV-I: general splicing mechanism in the HTLV-I family. *Science (Wash. DC).* 228:1532-1534.
22. Kannagi, M., S. Harada, I. Maruyama, H. Inoko, H. Igarashi, G. Kuwashima, S. Sato, M. Morita, M. Kidokoro, M. Sugimoto, et al. 1991. Predominant recognition of human T cell leukemia virus type I (HTLV-I) px gene products by human CD8<sup>+</sup> cytotoxic T cells directed against HTLV-I-infected cells. *Int. Immunol.* 3:761-767.
23. Gauldie, J., C. Richards, D. Harnish, P. Lansdorp, and H. Baumann. 1987. Interferon  $\beta$ 2/B-cell stimulatory factor type 2 shares identity with monocyte-derived hepatocyte-stimulating factor and regulates the major acute phase protein response in liver cells. *Proc. Natl. Acad. Sci. USA.* 84:7251-7255.
24. Pober, J. S., M. A. Gimbrone, Jr., L. A. Laperre, D. L. Mendrick, W. Fiers, R. Rothlein, and T. A. Springer. 1986. Overlapping patterns of activation of human endothelial cells by interleukin 1, tumor necrosis factor, and immune interferon. *J. Immunol.* 137:1893-1896.
25. Matsubara, T., S. Furukawa, and K. Yabuta. 1990. Serum levels of tumor necrosis factor, interleukin 2 receptor, and interferon- $\gamma$  in Kawasaki disease involved coronary-artery lesions. *Clin. Immunol. Immunopathol.* 56:29-36.
26. Rameshwar, P., D. Ganee, and P. Gascon. 1994. Introduction of IL-3 and granulocyte-macrophage colony-stimulating factor by substance P in bone marrow cells is partially mediated through the release of IL-1 and IL-6. *J. Immunol.* 152:4044-4054.
27. Katsikis, P. D., C. Chu, F. M. Brennan, R. N. Maini, and M. Feldmann. 1994. Immunoregulatory role of interleukin 10 in rheumatoid arthritis. *J. Exp. Med.* 179:1517-1527.
28. Pober, J. S., M. P. Bevilacqua, D. L. Mendrick, L. A. Lapiere, W. Fiers, and M. A. Gimbrone, Jr. 1986. Two distinct monokines, interleukin 1 and tumor necrosis factor, each independently induce biosynthesis and transient expression of the same antigen on the surface of cultured human vascular endothelial cells. *J. Immunol.* 136:1680-1687.
29. Paliard, X., R. de Waal Malefijt, H. Yssel, D. Blanchard, I. Chretien, J. Abrams, J. de Vries, and H. Spits. 1988. Simultaneous production of IL-2, IL-4, and IFN- $\gamma$  by activated human CD4<sup>+</sup> and CD8<sup>+</sup> T cell clones. *J. Immunol.* 141:849-855.
30. Mosmann, T. R., and R. L. Coffmann. 1987. Two types of mouse helper T-cell clone. *Immunol. Today.* 8:223-227.
31. Sugamura, K., M. Matsuyama, M. Fujii, M. Kannagi, and Y. Hinuma. 1983. Establishment of human cell lines constitutively producing immune interferon: transformation of normal T cells by a human retrovirus. *J. Immunol.* 131:1611-1612.
32. Salahuddin, S. Z., P. D. Markham, S. G. Lindner, J. Gootenberg, M. Popovic, H. Hemmi, P. S. Sarin, and R. C. Gallo. 1984. Lymphokine production by cultured human T cells transformed by human T-cell leukemia-lymphoma virus-I. *Science (Wash. DC).* 223:703-707.
33. Shimizu, K., T. Hirano, K. Ishibashi, N. Nakano, T. Taga, K. Sugamura, Y. Yamamura, and T. Kishimoto. 1985. Immortalization of BGDF(BCGF II)- and BCDF-producing T cells by human T cell leukemia virus (HTLV) and characterization of human BGDF(BCGF II). *J. Immunol.* 134:1728-1733.
34. Wano, Y., T. Hattori, M. Masuoka, K. Takatsuki, A. O. Chua, U. Gubler, and W. C. Green. 1987. Interleukin 1 gene expression in adult T cell leukemia. *J. Clin. Invest.* 80:911-916.