

**Immunohistochemical analysis of dystrophin-associated proteins in Becker/Duchenne muscular dystrophy with huge in-frame deletions in the NH2-terminal and rod domains of dystrophin.**

K Matsumura, ... , J C Kaplan, P Reinert

*J Clin Invest.* 1994;**93**(1):99-105. <https://doi.org/10.1172/JCI116989>.

Research Article

**Find the latest version:**

<https://jci.me/116989/pdf>



# Immunohistochemical Analysis of Dystrophin-associated Proteins in Becker/Duchenne Muscular Dystrophy with Huge In-frame Deletions in the NH<sub>2</sub>-Terminal and Rod Domains of Dystrophin

Kiichiro Matsumura,\* Arthur H. M. Burghes,† Marina Mora,‡ Fernando M. S. Tomé,|| Lucia Morandi,§ Ferdinando Cornello,§ France Leturcq,† Marc Jeanpierre,† Jean-Claude Kaplan,† Philippe Reinert,\*\* Michel Fardeau,|| Jerry R. Mendell,‡ and Kevin P. Campbell\*

\*Howard Hughes Medical Institute and Department of Physiology and Biophysics, University of Iowa College of Medicine, Iowa City, Iowa 52242; †Department of Neurology, Ohio State University, Columbus, Ohio 43210; ‡Divisione Malattie Neuromuscolari, Istituto Nazionale Neurologico "Carlo Besta," Milano 20133, Italy; ||Institut National de la Santé et de la Recherche Médicale, U.153, Paris 75005, France; †Institut National de la Santé et de la Recherche Médicale, U.129, Institut Cochin de Génétique Moléculaire, Paris 75014, France; and \*\*Service de Pédiatrie, Centre Hospitalier Intercommunal de Creteil, Creteil Cedex 94010, France

## Abstract

The absence of dystrophin causes the drastic reduction of the dystrophin-associated proteins (DAPs) in the sarcolemma and the loss of the linkage between the subsarcolemmal cytoskeleton and the extracellular matrix in Duchenne muscular dystrophy (DMD) skeletal muscle. Here, we report a mild reduction of the DAPs in the unique Becker muscular dystrophy patients with huge deletions in the rod domain of dystrophin and a moderate reduction of the DAPs in patients with huge deletions that involve both the NH<sub>2</sub>-terminal and rod domains of dystrophin. The phenotype of the latter patients was more severe than that of the former. In both cases, however, the reduction in the DAPs was milder than in typical DMD patients or DMD patients lacking the COOH-terminal domains of dystrophin. Our results suggest that (a) the NH<sub>2</sub>-terminal and rod domains of dystrophin may not be essential for the interaction with the sarcolemmal glycoprotein complex; and (b) defects in the actin binding activity of dystrophin may cause disruption of the anchorage of the dystrophin-glycoprotein complex to the subsarcolemmal cytoskeleton, which may render muscle fibers susceptible to degeneration. (*J. Clin. Invest.* 1994. 93:99–105.) **Key words:** Becker/Duchenne muscular dystrophy • dystrophin • dystrophin-glycoprotein complex • dystrophin-associated proteins • actin-cytoskeleton

## Introduction

Dystrophin, the protein product of the Duchenne muscular dystrophy (DMD)<sup>1</sup> gene (1, 2), is a cytoskeletal protein tightly

Address correspondence to Dr. Kevin P. Campbell, Howard Hughes Medical Institute, University of Iowa College of Medicine, 400 EMRB, Iowa City, IA 52242.

Received for publication 11 May 1993 and in revised form 18 August 1993.

1. *Abbreviations used in this paper:* BMD, Becker muscular dystrophy; 35DAG, 35-kD dystrophin-associated glycoprotein; 43DAG, 43-kD dystroglycan; 50DAG, 50-kD dystrophin-associated glycoprotein; 156DAG, 156-kD dystroglycan; DAP, dystrophin-associated protein; 59DAP, 59-kD DAP; DCG, dystrophin-glycoprotein complex; DMD, Duchenne muscular dystrophy.

*J. Clin. Invest.*

© The American Society for Clinical Investigation, Inc.

0021-9738/94/01/099/07 \$2.00

Volume 93, January 1994, 99–105

associated with a large oligomeric complex of sarcolemmal glycoproteins, including dystroglycan that binds laminin, a major protein component of the extracellular matrix (3–9). The NH<sub>2</sub>-terminal domain of dystrophin interacts with F-actin (10, 11). These findings indicate that the dystrophin-glycoprotein complex (DGC) spans the sarcolemma to link the subsarcolemmal actin-cytoskeleton to the extracellular matrix (6, 9, 12).

One of the goals for DMD research is the elucidation of the mechanism by which the absence of dystrophin leads to muscle fiber necrosis. Recently, we have demonstrated that the absence of dystrophin leads to a great reduction in all of the dystrophin-associated proteins (DAPs) in the sarcolemma of DMD patients (4, 9, 13, 14). The disruption of the linkage between the subsarcolemmal cytoskeleton and the extracellular matrix is presumed to cause severe sarcolemmal instability, which, in turn, may render muscle fibers susceptible to necrosis (12, 14).

These findings indicate the importance of elucidating the domains of dystrophin that interact with the DAPs or the actin-cytoskeleton. Skeletal muscle from particular patients with DMD/Becker muscular dystrophy (BMD) who have deletions that do not disrupt the open reading frame and produce truncated dystrophin provides an opportunity to study these domains. In the present study, we investigated the status of the components of the DGC in BMD/DMD patients who had huge deletions in the NH<sub>2</sub>-terminal and/or rod domains of dystrophin.

## Methods

*Patients.* Skeletal muscle biopsy specimens were obtained from eight BMD/DMD patients who had huge deletions in the NH<sub>2</sub>-terminal and/or rod domains of dystrophin (Table 1). Details of the data from each patient are described below:

*Patient 1.* This 2-yr-old boy started to walk at the age of 13 mo, but never walked properly. He had several episodes of pain in the lower extremities, which were induced by exercise and accompanied by myoglobinuria since the age of 21 mo. Serum creatine kinase (CK) level was elevated up to 250 times the normal upper limits. Multiplex PCR (15) and Southern blot analyses showed a deletion of exons 10–41 (not shown). Family history was negative.

*Patient 2.* This 7-yr-old boy was slow when walking alone and had muscle cramps after strenuous activity. On physical examination, he had calf hypertrophy, mild weakness of neck flexors, and tightness of heel tendons. Serum CK level was elevated to 40 times the normal upper limits. Multiplex PCR and Southern blot analyses revealed a deletion of exons 13–40 (not shown).

**Table 1. Summary of the BMD/DMD Patients Investigated in the Present Study**

Patient number	Age	Sex	Exons*	Classification <sup>†</sup>	Reduction of dystrophin/DAPs <sup>‡</sup>
yr					
Patients with deletions in the rod domain of dystrophin:					
1	2	M	10–41	Unclassified	Mild/mild
2	7	M	13–40	BMD	Mild/mild
3	7	M	13–41	BMD	Mild/mild
4 <sup>  </sup>	45	M	13–41	BMD	Mild/mild
5	8	M	13–44	BMD	Mild/mild
6	24	M	13–48	BMD	Mild/mild
Patients with deletions in the NH <sub>2</sub> -terminal and rod domains of dystrophin:					
7	5	M	3–42	Unclassified	Moderate/moderate
8	16	M	4–41 <sup>¶</sup>	DMD	Moderate/moderate

\* Deleted exons of the dystrophin gene, according to Koenig et al. (22). <sup>†</sup> Patients were classified as DMD or BMD based on the whole clinical picture. <sup>‡</sup> The overall status of dystrophin and the DAPs in the sarcolemma was scaled as the following, based on the immunostaining intensity and distribution compared with those in normal and DMD muscles: near normal, mild reduction, moderate reduction, and severe reduction (near-DMD level). <sup>||</sup> Maternal uncle of patient 3. <sup>¶</sup> Exons 3–41 were deleted at the mRNA level.

**Patient 3.** This 7-yr-old boy came to our attention because of high serum CK level (80 times of the normal upper limits). On physical examination, he had calf hypertrophy but no weakness. Multiplex PCR and Southern blot analyses showed a deletion of exons 13–41 (not shown) (16).

**Patient 4.** This 45-yr-old man is a maternal uncle of patient 3. He has had mild fatigability and muscle pain since childhood. On physical examination, he showed calf hypertrophy and mild weakness of pelvic girdle and thigh muscles. He showed waddling gait and climbed stairs with the aid of the handrail. Multiplex PCR and Southern blot analyses showed a deletion of exons 13–41 (not shown) (16).

**Patient 5.** This 8-yr-old boy came to our observation because of muscle pain at the age of 6 yr. At that time, he tended to walk on his toes and had rubbery consistency of calves. At the age of 8 yr, he had very mild weakness but could jump, climb stairs, and rise from the floor with only slight difficulty. Serum CK level was grossly elevated (80 times the normal upper limits). Multiplex PCR and Southern blot analyses revealed a deletion of exons 13–44 (not shown).

**Patient 6.** This 24-yr-old man had normal motor development but was notably slow in motor skills compared to his peers in early childhood. At age 5 yr, the calf muscles were obviously enlarged. Serum CK level was elevated 20 times the normal upper limits. During the next 19 yr, he has gradually lost ambulatory skills but continued to walk independently with a lordotic posture. He demonstrates Gowers' maneuver. Multiplex PCR and Southern blot analyses revealed a deletion of exons 13–48 (not shown) (17). Studies at the RNA level confirmed this deletion and joining of basepairs 1,690 to 7,307 (reference 17, patient 302). Family history was negative.

**Patient 7.** This 5-yr-old boy was normal at birth. He demonstrated delayed walking at the age of 16 mo. He never learned to run well and fell frequently. Examination revealed diffuse muscle weakness. He walked with a lordotic posture and exhibited a Gowers' maneuver. Serum CK level was elevated >20 times the normal upper limits. Multiplex PCR and Southern blot analyses revealed a deletion of exons 3–42 (not shown). Family history was negative.

**Patient 8.** This 16-yr-old boy was normal at birth and in the neonatal period. Motor developmental milestones were normal but he never learned to run well. Physical examination at the age of 7 yr showed a lordotic posture when walking and partial Gowers' maneuver. Serum CK level was elevated 50 times the normal upper limits. During the subsequent years, he has lost function progressively. He became confined to a wheelchair at the age of 12 yr. Multiplex PCR and Southern blot analyses revealed a deletion of exons 4–41 (not shown) (17). Studies at the mRNA level showed a deletion of exons 3–41 joining basepair 301 to 6,131 (reference 17, patient 113). Family history was negative.

**Antibodies.** Monoclonal antibody IVD3<sub>1</sub> against the 50-kD dystrophin-associated glycoprotein (50DAG) and VIA4<sub>2</sub> against dystrophin were characterized previously (4, 8). The epitope of VIA4<sub>2</sub> is confined to the cysteine-rich or COOH-terminal domain of dystrophin and thus is not involved in the exons deleted in the BMD/DMD patients reported here. Specific antibodies against the DGC were raised in sheep using DGC purified from rabbit skeletal muscle as the antigen (13, 14, 18–20). An antibody against the 156-kD dystroglycan (156DAG) was affinity purified from this sheep serum using Immobilon-P transfer membrane strip of the 156DAG fusion protein (FP-D) (9). Antibodies against the 59-kD dystrophin-associated protein (59DAP), 50DAG, 43 kD dystroglycan (43DAG), and 35 kD dystrophin-associated glycoprotein (35DAG) were affinity-purified from sheep serum using individual transfer membrane strips (Immobilon-P; Millipore Corp., Bedford, MA) of the components of the DGC as described (13, 14, 18–20). Affinity-purified rabbit antibodies against the first 15 amino acids of the NH<sub>2</sub>-terminus and the last 10 amino acids of the COOH-terminus of dystrophin were characterized previously (5, 7, 13, 20, 21).

**Immunohistochemistry.** Indirect immunofluorescence microscopy of 7- $\mu$ m thick cryosections from skeletal muscle biopsy specimens was performed as described below. Blocking was performed by incubation with 5% BSA in PBS (50 mM sodium phosphate, pH 7.4, 0.9% NaCl) for 30 min. Incubation with the primary antibodies was performed for 2 h with the following dilution conditions: IVD3<sub>1</sub>, 1:50; VIA4<sub>2</sub>, neat; anti-156DAG, neat; anti-59DAP, 1:20; anti-43DAG, 1:20; anti-35DAG, 1:20; anti-NH<sub>2</sub>-terminus of dystrophin, neat; anti-COOH-terminus of dystrophin, neat. In the case of mouse primary antibodies, cryosections were incubated with 1:200 diluted fluorescein-conjugated anti-mouse IgG (Boehringer-Mannheim Corp., Indianapolis, IN) for 1 hr. In the case of sheep or rabbit primary antibodies, cryosections were incubated with 1:500 diluted biotinylated anti-sheep IgG or anti-rabbit IgG (Vector Laboratories, Burlingame, CA) for 1 hr, followed by 30-min incubation with 1:1,000 diluted fluorescein-conjugated streptavidin (Jackson Immuno Research Labs, Inc., West Grove, PA). Each incubation was followed by rigorous washing with PBS.

For reliable comparison, cryosections from the BMD/DMD patients reported here, normal humans, DMD patients, and patients with non-DMD/BMD neuromuscular diseases were placed on the same microscopy slide and processed identically. In addition, photographs were taken under identical conditions with the same exposure time.

## Results and Discussion

In the five patients with huge deletions in the rod domain of dystrophin (patients 2–6), the immunostaining for the components of the DGC was slightly reduced, sometimes in a patchy fashion, when compared to normals or patients with non-DMD/BMD neuromuscular diseases (Table I, Figs. 1–3). In one patient with a deletion of exons 10–41 (patient 1), all components of the DGC were fairly well preserved in the majority of muscle fibers, but they seemed to be reduced in a cluster of small-caliber regenerating muscle fibers (Fig. 2). In the two patients with huge deletions that involve both the NH<sub>2</sub>-terminal and rod domains of dystrophin (patients 7 and 8), on the other hand, the reduction in the immunostaining for the components of the DGC in the sarcolemma was more severe than in patients 1–6 (Table I, Fig. 3). For the individual patients in

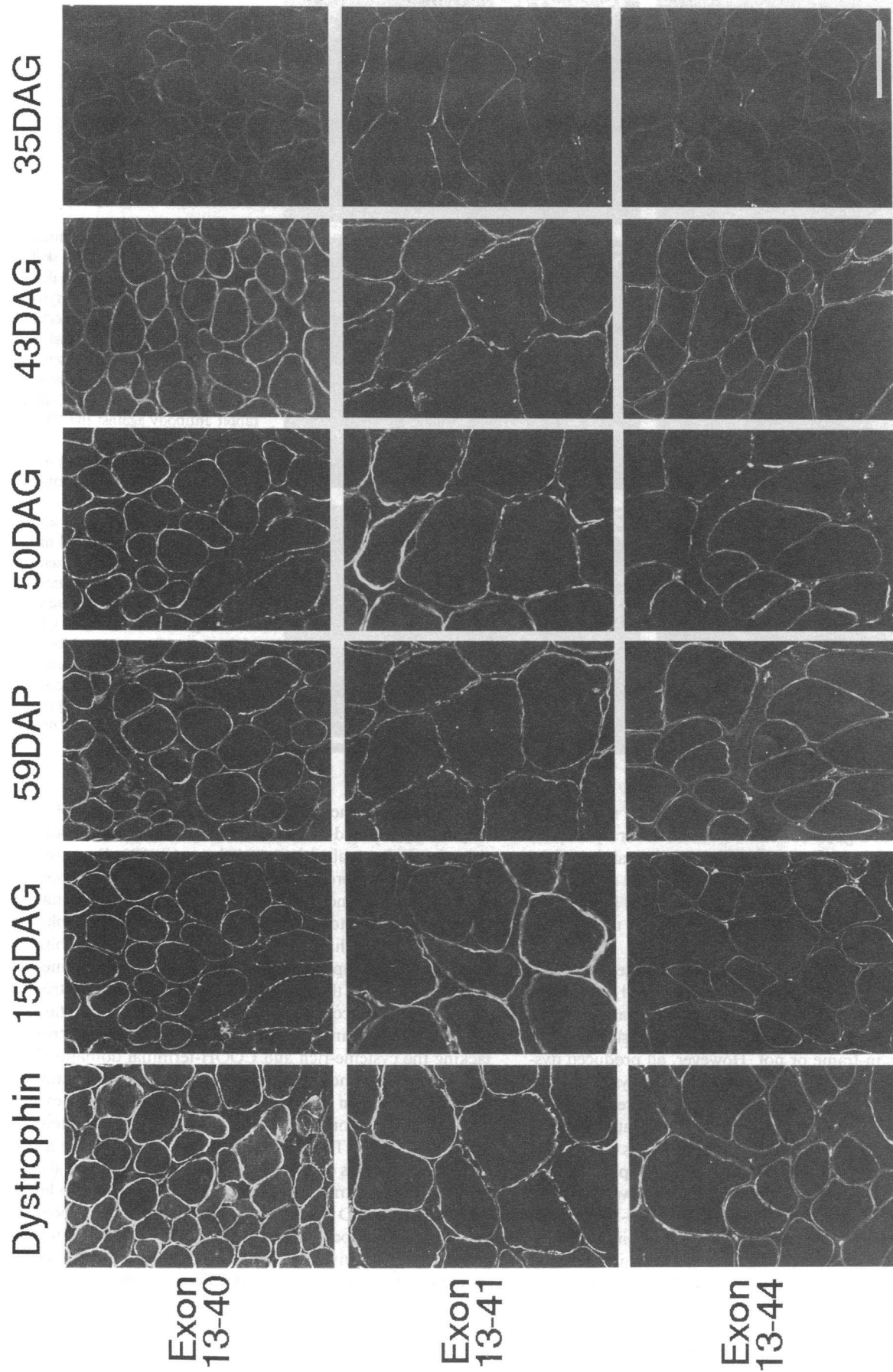
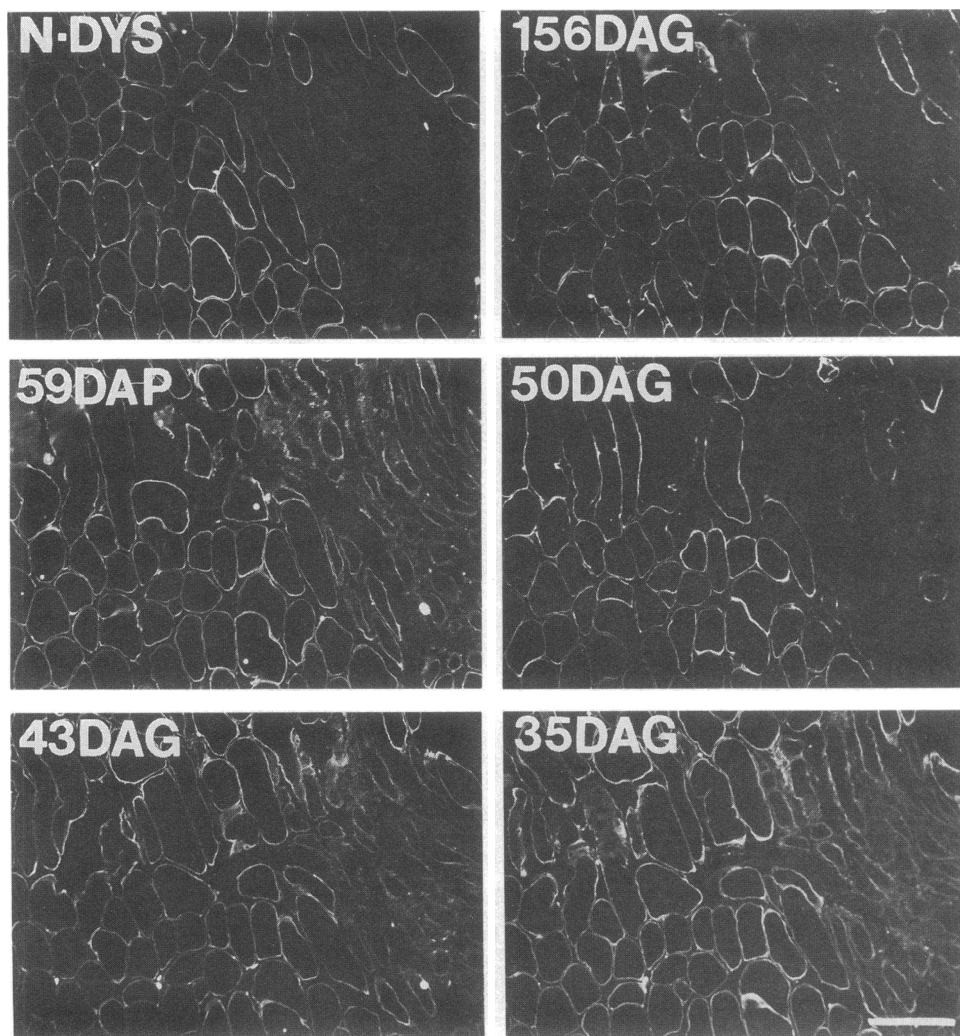


Figure 1. Immunohistochemical analysis of the DAPs in the skeletal muscle from BMD patients with deletions of exons 13-40, 13-41, and 13-44 of the dystrophin gene. Transverse cryosections (7  $\mu$ m) from biopsied skeletal muscle from BMD patients with deletions of exons 13-40 (patient 2), exons 13-41 (patient 4), and exons 13-44 (patient 5) of the dystrophin gene were immunostained with a monoclonal antibody VIA<sub>4</sub> against the cysteine-rich/COOH-terminal domains of dystrophin, a monoclonal antibody IVD<sub>3</sub> against the 50DAG, and affinity-purified sheep antibodies against the 156DAG, 59DAP, 43DAG, and 35DAG. Dystrophin and all of the DAPs were only slightly reduced in the sarcolemma of these patients. The results of patient 3 were similar to those of patient 4, his maternal uncle (not shown). *Bar*, 50  $\mu$ m.

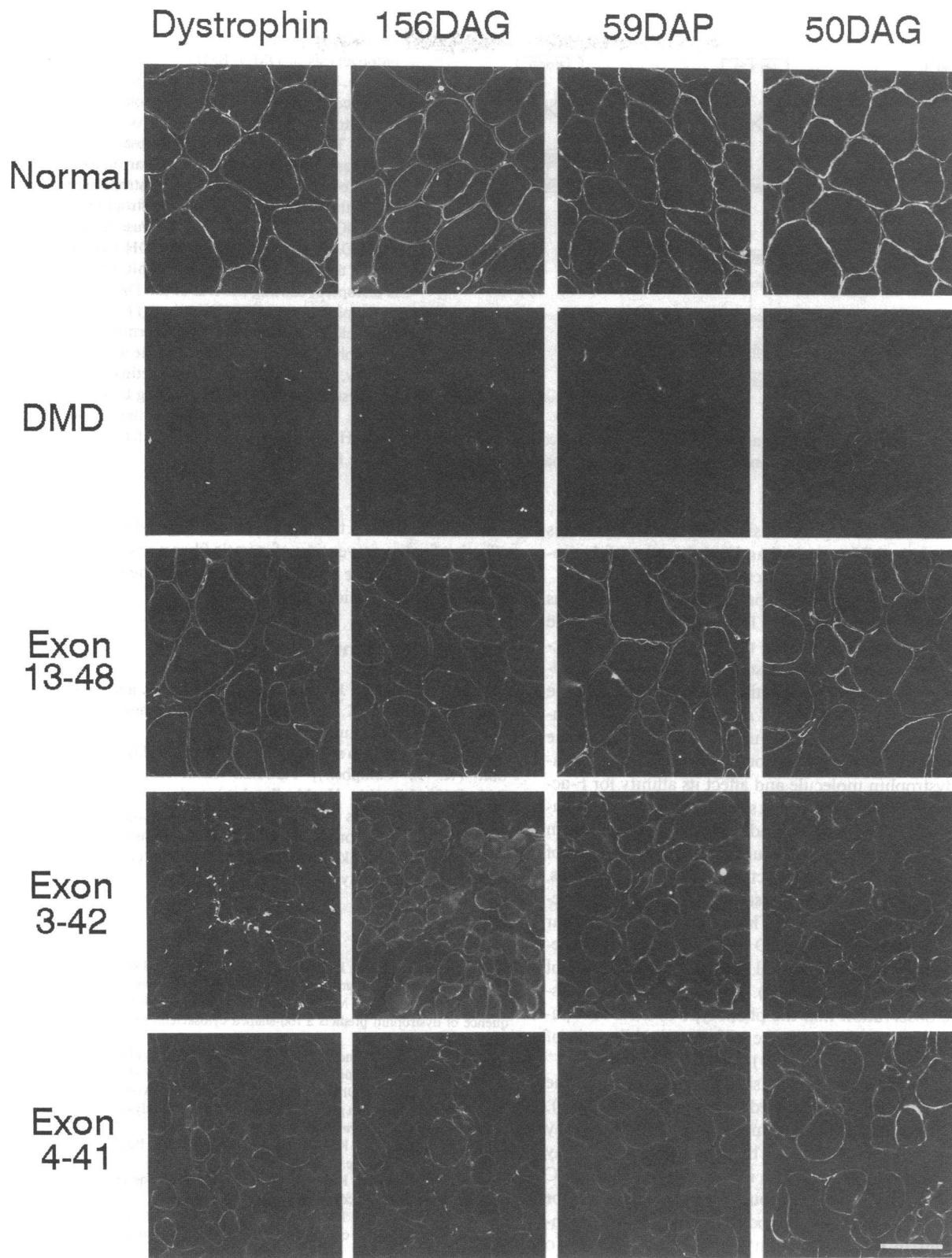


**Figure 2.** Immunohistochemical analysis of the DAPs in the skeletal muscle from a patient with a deletion of exons 10–41 of the dystrophin gene. Transverse cryosections (7  $\mu\text{m}$ ) from biopsied skeletal muscle from a patient with a deletion of exons 10–41 (patient 1) were immunostained with affinity-purified rabbit antibody against the NH<sub>2</sub>-terminus of dystrophin (*N-DYS*), a monoclonal antibody IVD3, against the 50DAG, and affinity-purified sheep antibodies against the 156DAG, 59DAP, 43DAG, and 35DAG. Dystrophin and all of the DAPs were relatively well preserved in the sarcolemma of this patient. In a cluster of regenerating muscle fibers (right half of the figure), all of these proteins appeared less abundant than in the surrounding fibers. This was also the case in the other clusters of regenerating muscle fibers found in this patient (not shown). Bar, 100  $\mu\text{m}$ .

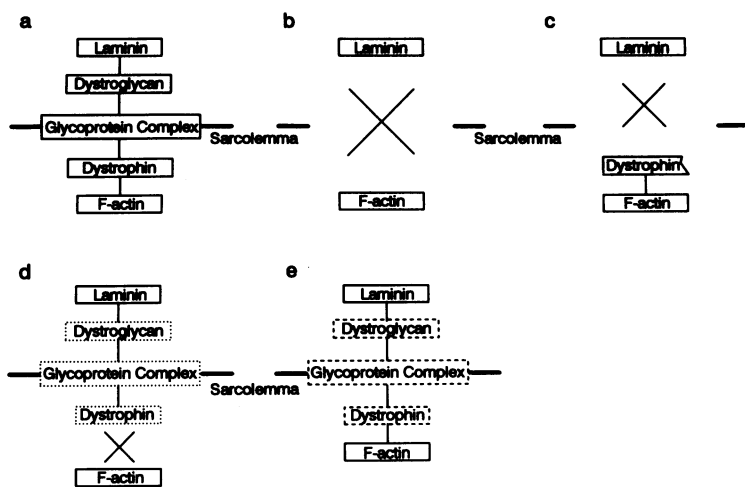
both groups, the reduction in the intensity of the staining for the DAPs showed a good correlation with that for dystrophin (Table I, Figs. 1–3). However, the reduction in staining of the DAPs in the patients reported here was in no case as severe as the loss observed in typical DMD patients (Table I, Fig. 3) or DMD patients who produce dystrophin but lack the COOH-terminal domains (19).

All of the eight BMD/DMD patients reported here had huge in-frame deletions in the NH<sub>2</sub>-terminal and/or rod domains of dystrophin at the DNA level, except for patients 6 and 8 (17); but it remains to be determined if the translated amino acid sequence is in-frame or not. However, all produced dystrophin that stained with antibodies against the cysteine-rich/COOH-terminal domains, implying that they are indeed in-frame mutations. Here we report a mild to moderate reduction of the DAPs in the sarcolemma of these patients. Consistent with the previous reports, the phenotype of the six patients with huge deletions that involve only the rod domain was mild and resembled that of typical BMD (patients 2–6) (22–26). On the other hand, the phenotype of the two patients with deletions that involve both the NH<sub>2</sub>-terminal and rod domains was relatively severe and resembled that of DMD, outlier or severe BMD (patients 7 and 8) (17, 22, 23, 27–30). Patient 1 with a deletion of exons 10–41 was too young to be classified as DMD, outlier, or BMD, but at least his phenotype is not that of a typical DMD.

According to the structural organization of the DGC, dystrophin is presumed to anchor the DAPs in the sarcolemma to the subsarcolemmal actin-cytoskeleton (9, 12). Recently, the calpain digestion products of dystrophin which correspond to the cysteine-rich and the first half of the COOH-terminal domains were shown to bind to wheat germ agglutinin–Sepharose beads, indicating that the binding site (or one of the binding sites) for the glycoprotein complex exists in the cysteine-rich and the first half of the COOH-terminal domains of dystrophin (31). This is also consistent with our findings on the status of the DAPs in the unique DMD patients who had dystrophin lacking the cysteine-rich and COOH-terminal domains (19). In these patients, the DAPs were reduced in the sarcolemma to the same level as in typical DMD patients, despite the expression and localization of truncated dystrophin to the sarcolemmal region (19). The deficiency of the DAPs in the sarcolemma and the loss of the linkage of the subsarcolemmal cytoskeleton to the extracellular matrix were considered to be the cause of the DMD phenotype despite the proper expression and intracellular localization of truncated dystrophin in these patients (19). In this paper we reported a series of BMD/DMD patients with huge in-frame deletions in the rod and/or NH<sub>2</sub>-terminal domains. In all these patients, dystrophin is presumed to retain the cysteine-rich and COOH-terminal domains and thus to bind the DAPs. The present data that demonstrate not only a slight but also a comparable reduction of dys-



**Figure 3.** Immunohistochemical analysis of the DAPs in the skeletal muscle from BMD/DMD patients with deletions of exons 13–48, 3–42, and 4–41 of the dystrophin gene. Transverse cryosections (7  $\mu$ m) from biopsied skeletal muscle from a human with no obvious pathological abnormality (*Normal*), a DMD patient, BMD/DMD patients with deletions of exons 13–48 (patient 6), exons 3–42 (patient 7) and exons 4–41 (3–41 at mRNA level) (patient 8) of the dystrophin gene were immunostained with a monoclonal antibody VIA<sub>4</sub> against the cysteine-rich/COOH-terminal domains of dystrophin, a monoclonal antibody IVD3<sub>1</sub> against the 50DAG, and affinity-purified sheep antibodies against the 156DAG and 59DAP. Dystrophin, the 156DAG, 59DAP, and 50DAG were only slightly reduced in the sarcolemma of patient 6, while they were moderately reduced in patients 7 and 8. The 43DAG and 35DAG showed a similar staining pattern as the 156DAG, 59DAP, and 50DAG (not shown). Bar, 100  $\mu$ m.



**Figure 4.** Hypothetical scheme on the molecular pathogenesis of DMD/BMD. (a) Normal skeletal muscle. The dystrophin-glycoprotein complex spans the sarcolemma to link the subsarcolemmal actin-cytoskeleton to the extracellular matrix. (b) Typical DMD. The linkage between the subsarcolemmal actin-cytoskeleton and the extracellular matrix is disrupted because of absence of dystrophin and the loss of the DAPs. (c) DMD with dystrophin lacking the COOH-terminal domains. Because of the absence of the DAPs binding site in the COOH-terminal domains, the linkage between dystrophin and the DAPs is disrupted, causing the loss of the DAPs and leading to the phenotype of DMD (16). (d) DMD/outlier with deletions involving the NH<sub>2</sub>-terminal domain of dystrophin. Due to the defects in the actin binding activity, the linkage between the actin-cytoskeleton and dystrophin is disrupted, leading to a severe phenotype. (e) BMD with deletions in the rod domain

of dystrophin. The linkage between the actin-cytoskeleton and extracellular matrix is preserved. However, dystrophin with defects in the rod domain may not serve a normal function or may be unstable, and may eventually lead to muscle fiber degeneration.

trophin and the DAPs are quite consistent with this hypothesis and suggest that the NH<sub>2</sub>-terminal and rod domains of dystrophin are not essential for the interaction with the DAPs.

Recently the NH<sub>2</sub>-terminal domain of dystrophin was shown to interact with F-actin (10, 11), as predicted from the amino acid sequence (2). Nuclear magnetic resonance spectroscopy of synthetic peptides suggests two putative actin-binding sites in the NH<sub>2</sub>-terminal domain, one in exon 2 and the other in exon 6 (32). In patients 7 and 8, the putative actin-binding site in exon 6 is deleted. Furthermore, defects in the vicinity of the actin-binding sites could change the conformation of the dystrophin molecule and affect its affinity for F-actin (28). From these observations, it seems reasonable to speculate that the defects in the actin binding activity of dystrophin in patients 7 and 8 caused the disruption of the anchorage of the DGC to the subsarcolemmal actin-cytoskeleton and thus, the loss of the linkage between the subsarcolemmal cytoskeleton and the extracellular matrix. This could lead to a similar sarcolemmal instability as in DMD and eventually to the severe phenotype, despite the normal DAPs-binding activity of dystrophin in these patients (Fig. 4). This hypothesis is consistent with the observation that the phenotype of the BMD patients with in-frame deletions in the NH<sub>2</sub>-terminal domain of dystrophin is severe (22, 23, 27–30).

On the other hand, the binding sites for both actin and the DAPs are presumed to be preserved in patients 1–6 (Fig. 4). However, dystrophin with an extremely short rod domain may not have normal function or may be unstable, and this may eventually lead to a mild reduction in the density of the DGC in the sarcolemma. Indeed, this could be the explanation for the observation that the phenotype of the patients with in-frame deletions in the rod domain is mild (16, 22–26). To understand the molecular pathogenesis of BMD caused by the deletions in the rod domain, more information about the function(s) of the rod domain and the effects that specific deletions in this domain have on the organization of the DGC and on the ability of dystrophin to dimerize needs to be obtained.

The findings reported here would have significant implications on the development of potential gene therapies for DMD (33). They help to define the minimal requirements for the dystrophin mini-genes and indicate that mini-dystrophin must

be able to bind both the actin-cytoskeleton and the DAPs to be effective for the prevention of muscle fiber necrosis in DMD. It probably will also be important to maintain the rod domain in a certain conformation.

## Acknowledgments

The authors thank C. J. Leveille, M. J. Mullinnix, and H. Collin for technical assistance. K. P. Campbell is an Investigator of the Howard Hughes Medical Institute.

This work was also supported by the Muscular Dystrophy Association (K. P. Campbell), National Institutes of Health grant R29AR40015-04 (A. H. M. Burghes) and Association Française Contre les Myopathies (F. M. S. Tomé and J.-C. Kaplan). The financial support of Telethon, Italy for the project "Pathogenesis of muscle degeneration in X-linked muscular dystrophies: role of dystrophin" (M. Mora) is gratefully acknowledged.

## References

- Hoffman, E. P., R. H. Brown, and L. M. Kunkel. 1987. Dystrophin: the protein product of the Duchenne muscular dystrophy locus. *Cell*. 51:919–928.
- Koenig, M., A. P. Monaco, and L. M. Kunkel. 1988. The complete sequence of dystrophin predicts a rod-shaped cytoskeletal protein. *Cell*. 53:219–228.
- Campbell, K. P., and S. D. Kahl. 1989. Association of dystrophin and an integral membrane glycoprotein. *Nature (Lond.)*. 338:259–262.
- Ervasti, J. M., K. Ohlendieck, S. D. Kahl, M. G. Gaver, and K. P. Campbell. 1990. Deficiency of a glycoprotein component of the dystrophin complex in dystrophic muscle. *Nature (Lond.)*. 345:315–319.
- Ervasti, J. M., S. D. Kahl, and K. P. Campbell. 1991. Purification of dystrophin from skeletal muscle. *J. Biol. Chem.* 266:9161–9165.
- Ervasti, J. M., and K. P. Campbell. 1991. Membrane organization of the dystrophin-glycoprotein complex. *Cell*. 66:1121–1131.
- Ohlendieck, K., J. M. Ervasti, J. B. Snook, and K. P. Campbell. 1991. Dystrophin-glycoprotein complex is highly enriched in isolated skeletal muscle sarcolemma. *J. Cell Biol.* 112:135–148.
- Ohlendieck, K., and K. P. Campbell. 1991. Dystrophin constitutes 5% of membrane cytoskeleton in skeletal muscle. *FEBS (Fed. Eur. Biochem. Soc.) Lett.* 283:230–234.
- Ibraghimov-Beskrovnaya, O., J. M. Ervasti, C. J. Leveille, C. A. Slaughter, S. W. Sernett, and K. P. Campbell. 1992. Primary structure of dystrophin-associated glycoproteins linking dystrophin to the extracellular matrix. *Nature (Lond.)*. 355:696–702.
- Hemmings, L., P. A. Kuhlmann, and D. R. Critchley. 1992. Analysis of the actin-binding domain of  $\alpha$ -actinin by mutagenesis and demonstration that dystrophin contains a functionally homologous domain. *J. Cell Biol.* 116:1369–1380.

11. Way, M., B. Pope, R. A. Cross, J. Kendrick-Jones, and A. G. Weeds. 1992. Expression of the NH<sub>2</sub>-terminal domain of dystrophin in *E. coli* and demonstration of binding to F-actin. *FEBS (Fed. Eur. Biochem. Soc.) Lett.* 301:243-245.
12. Matsumura, K., and K. P. Campbell. 1993. Deficiency of dystrophin-associated proteins: a common mechanism leading to muscle cell necrosis in severe childhood muscular dystrophies. *Neuromusc. Dis.* 3:109-118.
13. Ohlendieck, K., and K. P. Campbell. 1991. Dystrophin-associated proteins are greatly reduced in skeletal muscle from mdx mice. *J. Cell Biol.* 115:1685-1694.
14. Ohlendieck, K., K. Matsumura, V. V. Ionasescu, J. A. Towbin, E. P. Bosch, S. L. Weinstein, S. W. Sernett, and K. P. Campbell. 1993. Duchenne muscular dystrophy: deficiency of dystrophin-associated proteins in the sarcolemma. *Neurology.* 43:795-800.
15. Chamberlain, J. S., R. A. Gibbs, J. E. Ranier, P. N. Nguyen, and C. T. Caskey. 1988. Deletion screening of the Duchenne muscular dystrophy locus via multiplex DNA amplification. *Nucleic Acids Res.* 16:11141-11156.
16. Morandi, L., M. Mora, P. Bernasconi, R. Mantegazza, M. Gebbia, M. R. Balestrini, and F. Cornelio. 1993. Very small dystrophin molecule in a family with a mild form of Becker dystrophy. *Neuromusc. Dis.* 3:65-70.
17. Winnard, A. V., C. J. Klein, D. D. Coovert, T. Prior, A. Papp, P. Snyder, D. E. Bulman, P. N. Ray, P. McAndrew, W. King, et al. 1993. Characterization of translational frame exception patients in Duchenne/Becker muscular dystrophy. *Hum. Mol. Genet.* 2:737-744.
18. Matsumura, K., F. M. S. Tomé, H. Collin, K. Azibi, M. Chaouch, J.-C. Kaplan, M. Fardeau, and K. P. Campbell. 1992. Deficiency of the 50K dystrophin-associated glycoprotein in severe childhood autosomal recessive muscular dystrophy. *Nature (Lond.)*. 359:320-322.
19. Matsumura, K., F. M. S. Tomé, V. V. Ionasescu, J. M. Ervasti, R. D. Anderson, N. B. Romero, D. Simon, D. Recan, J.-C. Kaplan, M. Fardeau, and K. P. Campbell. 1993. Deficiency of dystrophin-associated proteins in Duchenne muscular dystrophy patients lacking C-terminal domains of dystrophin. *J. Clin. Invest.* 92:866-871.
20. Matsumura, K., J. M. Ervasti, K. Ohlendieck, S. D. Kahl, and K. P. Campbell. 1992. Association of dystrophin-related protein with dystrophin-associated proteins in mdx mouse muscle. *Nature (Lond.)*. 360:588-591.
21. Ohlendieck, K., J. M. Ervasti, K. Matsumura, S. D. Kahl, C. J. Leveille, and K. P. Campbell. 1991. Dystrophin-related protein is localized to neuromuscular junctions of adult skeletal muscle. *Neuron.* 7:499-508.
22. Koenig, M., A. H. Beggs, M. Moyer, S. Scherpf, K. Heindrich, T. Betcken, G. Meng, C. R. Muller, M. Lindrof, H. Kaariainen, et al. 1989. The molecular basis for Duchenne versus Becker muscular dystrophy: correlation of severity with type of deletion. *Am. J. Hum. Genet.* 45:498-506.
23. Beggs, A. H., E. P. Hoffman, J. R. Snyder, K. Arahata, L. Specht, F. Shapiro, C. Angelini, H. Sugita, and L. M. Kunkel. 1991. Exploring the molecular basis for variability among patients with Becker muscular dystrophy: dystrophin gene and protein studies. *Am. J. Hum. Genet.* 49:54-67.
24. England, S. B., L. V. B. Nicholson, M. A. Johnson, S. M. Forrest, D. R. Love, E. E. Zubrzycka-Gaarn, D. E. Bulman, J. B. Harris, and K. E. Davies. 1990. Very mild muscular dystrophy associated with the deletion of 46% of dystrophin. *Nature (Lond.)*. 343:180-182.
25. Love, D. R., T. J. Flint, S. A. Genet, H. R. Middleton-Price, and K. E. Davies. 1991. Becker muscular dystrophy patient with a large intragenic dystrophin deletion: implications for functional minigenes and gene therapy. *J. Med. Genet.* 28:860-864.
26. Ikeya, K., K. Saito, K. Hayashi, H. Tanaka, Y. Hagiwara, M. Yoshida, A. Yamauchi, Y. Fukuyama, T. Ishiguro, C. Eguchi, and E. Ozawa. 1992. Molecular genetic and immunological analysis of dystrophin of a young patient with X-linked muscular dystrophy. *Am. J. Med. Genet.* 43:580-587.
27. Malhotra, S. B., K. A. Hart, H. J. Klamut, N. S. T. Thomas, S. E. Bodrug, A. H. M. Burghes, M. Borrow, P. S. Harper, M. W. Thompson, P. N. Ray, and R. G. Worton. 1988. Frame-shift deletions in patients with Duchenne and Becker muscular dystrophy. *Science (Wash. DC)*. 242:755-759.
28. Matsumura, K., and N. Imoto. 1991. Two long-living brothers of dystrophin-related muscular dystrophy with an in-frame deletion of exon 3 of the dystrophin gene: clinical features and diagnosis. *Clin. Neurol. (Tokyo)*. 31:286-290.
29. Gangopadhyay, S. B., T. G. Sherratt, J. Z. Heckmatt, V. V. Dubovitz, G. Miller, M. Shokeir, P. N. Ray, P. N. Strong, and R. G. Worton. 1992. Dystrophin in frameshift deletion patients with Becker muscular dystrophy. *Am. J. Hum. Genet.* 51:562-570.
30. Vainzof, M., R. I. Takata, M. R. Passos-Bueno, R. C. M. Pavanello, and M. Zatz. 1992. Is the maintenance of the C-terminus domain of dystrophin enough to ensure a milder Becker muscular dystrophy phenotype? *Hum. Mol. Genet.* 2:39-42.
31. Suzuki, A., M. Yoshida, H. Yamamoto, and E. Ozawa. 1992. Glycoprotein-binding site of dystrophin is confined to the cysteine-rich domain and the first half of the carboxyl-terminal domain. *FEBS (Fed. Eur. Biochem. Soc.) Lett.* 308:154-160.
32. Levine, B. A., A. J. G. Moir, V. B. Patchell, and S. V. Perry. 1992. Binding sites involved in the interaction of actin with the NH<sub>2</sub>-terminal region of dystrophin. *FEBS (Fed. Eur. Biochem. Soc.) Lett.* 298:44-48.
33. Ragot, T., N. Vincent, P. Chafey, E. Vigne, H. Gilgenkrantz, D. Couton, J. Cartaud, P. Briand, J.-C. Kaplan, M. Perricaudet, and A. Kahn. 1993. Efficient adenovirus-mediated transfer of a human minidystrophin gene to skeletal muscle of mdx mice. *Nature (Lond.)*. 361:647-650.