

## **Plasticity of integrin expression by nerve-derived connective tissue cells. Human Schwann cells, perineurial cells, and fibroblasts express markedly different patterns of beta 1 integrins during nerve development, neoplasia, and in vitro.**

L L Hsiao, ... , H Gralnick, J Uitto

*J Clin Invest.* 1991;**87**(3):811-820. <https://doi.org/10.1172/JCI115084>.

### Research Article

Strikingly selective expression patterns of beta 1, alpha 2, alpha 3, and alpha 5 integrin subunits were revealed in endoneurium, perineurium, and epineurium of fetal and adult human peripheral nerve by immunostaining with specific antibodies. The alpha 2 subunit was expressed only on Schwann cells both in fetal and adult nerve, whereas the alpha 3 epitopes were expressed exclusively in the adult tissue and were primarily present on perineurial cells. The alpha 5 epitopes were expressed only on the innermost cell layer of perineurium of fetal and adult nerve. The tumor cells within schwannomas and cutaneous neurofibromas expressed both alpha 2 and alpha 3 subunits, indicating that Schwann cells have the potential to express also the alpha 3 subunit in vivo. Cell cultures established from human fetal nerve and neurofibromas revealed expression of the alpha 2 and alpha 5 epitopes on Schwann cells, perineurial cells, and fibroblasts, whereas only Schwann cells contained the alpha 3 epitopes which were occasionally concentrated on the adjacent Schwann cells at cell-cell contacts. Our findings emphasize that nerve connective tissue cells change their profiles for expression of extracellular matrix receptors under conditions which have different regulatory control signals exerted by, for example, axons, humoral factors, or the extracellular matrix of the peripheral nerve. This plasticity may play an important role during nerve development and in [...]

**Find the latest version:**

<https://jci.me/115084/pdf>



# Plasticity of Integrin Expression by Nerve-derived Connective Tissue Cells

## Human Schwann Cells, Perineurial Cells, and Fibroblasts Express Markedly Different Patterns of $\beta 1$ Integrins during Nerve Development, Neoplasia, and In Vitro

Li Li Hsiao, Juha Peltonen, Sirkku Jaakkola, Harvey Gralnick,\* and Jouni Uitto

Departments of Dermatology, and Biochemistry and Molecular Biology, Jefferson Medical College, and Section of Molecular Dermatology, Jefferson Institute of Molecular Medicine, Thomas Jefferson University, Philadelphia, Pennsylvania 19107; and

\*Clinical Pathology Department, Clinical Center, National Institutes of Health, Bethesda, Maryland 20892

### Abstract

Strikingly selective expression patterns of  $\beta 1$ ,  $\alpha 2$ ,  $\alpha 3$ , and  $\alpha 5$  integrin subunits were revealed in endoneurium, perineurium, and epineurium of fetal and adult human peripheral nerve by immunostaining with specific antibodies. The  $\alpha 2$  subunit was expressed only on Schwann cells both in fetal and adult nerve, whereas the  $\alpha 3$  epitopes were expressed exclusively in the adult tissue and were primarily present on perineurial cells. The  $\alpha 5$  epitopes were expressed only on the innermost cell layer of perineurium of fetal and adult nerve. The tumor cells within schwannomas and cutaneous neurofibromas expressed both  $\alpha 2$  and  $\alpha 3$  subunits, indicating that Schwann cells have the potential to express also the  $\alpha 3$  subunit in vivo. Cell cultures established from human fetal nerve and neurofibromas revealed expression of the  $\alpha 2$  and  $\alpha 5$  epitopes on Schwann cells, perineurial cells, and fibroblasts, whereas only Schwann cells contained the  $\alpha 3$  epitopes which were occasionally concentrated on the adjacent Schwann cells at cell-cell contacts. Our findings emphasize that nerve connective tissue cells change their profiles for expression of extracellular matrix receptors under conditions which have different regulatory control signals exerted by, for example, axons, humoral factors, or the extracellular matrix of the peripheral nerve. This plasticity may play an important role during nerve development and in neoplastic processes affecting the connective tissue compartments of peripheral nerve. (*J. Clin. Invest.* 1991; 87:811-820.) Key words: basement membranes • type IV collagen • fibronectin • neurofibroma • schwannoma • peripheral nerve

### Introduction

Cell-cell and cell-matrix interactions are mediated by cell surface molecules, such as integrins, which function as specific receptors for different ligands (1-4). All VLA integrins share the common  $\beta 1$  subunit whereas the specificity for ligand binding is determined, at least in part, by different  $\alpha$  subunits (2, 3, 5, 6). For example, the  $\alpha 2$  subunit mediates binding to various collagen types and laminin (7, 8-10), whereas the  $\alpha 5$  subunit is responsible for binding to fibronectin (6, 11, 12). The  $\alpha 3$  sub-

unit has a relatively broad specificity, and interacts with several ligands, including fibronectin, laminin, and different collagens (10). Furthermore, a recent study has shown that the integrin  $\alpha$  subunit ligand binding specificity may be modulated by cell-type specific factors (13). In addition to their role in cell-matrix interactions, the  $\beta 1$  integrins have been recently implicated in the maintenance of cell-cell contacts (14, 15). Thus integrins may play an important role in the complex regulatory interactions necessary for ordered embryogenesis, neural development, and tissue repair, as well as in development and growth of tumors (3, 7, 16-19).

Neural development during embryogenesis or as part of nerve repair is a complex process which apparently involves cell-cell and cell-matrix interactions (17, 20-24). At least three cell types of neural connective tissue, Schwann cells, perineurial cells, and fibroblasts, are involved in these processes (22, 23, 25). The Schwann cell-axon units and the endoneurial connective tissue of peripheral nerves are surrounded by the tubular perineurium (26-29), which isolates the endoneurium from the epineurial connective tissue. The perineurium constitutes the basis for the maintenance of endoneurial homeostasis (30, 31), which is essential for the proper function of normal peripheral nerves. This barrier function of perineurium is a result of the presence of an exceptionally thick basement membrane, which surrounds the perineurial cell layers on both sides, and tight junctions connecting adjacent cells within each layer of perineurium (26, 28, 32). The basement membrane is formed by type IV collagen which associates with noncollagenous glycoproteins, such as laminin, nidogen, and fibronectin (33, 34). Thus, it is conceivable that interactions of nerve connective tissue cells with the adjacent extracellular matrix may play an important role in neural development.

Cutaneous neurofibromas, the hallmark of neurofibromatosis 1, consist of heterogenous cell populations, including Schwann cells, perineurial cells, and fibroblasts, together with scattered mast cells and phagocytic cells (35). In contrast, benign schwannomas are more homogenous and consist almost exclusively of Schwann cells (36). The extracellular matrix of neurofibromas contains type I, III, IV, V, and VI collagens, as well as fibronectin and other noncollagenous components of the basement membrane zone, such as laminin and nidogen (35, 37-41). Previous studies examining other cutaneous tumors have shown altered and variable expression of integrins (18, 42). Specifically, squamous cell carcinomas with a high metastatic potential were shown to express low or undetectable levels of integrins, whereas more benign basal cell carcinomas showed clearly detectable levels of  $\beta 1$  integrins (18). Furthermore, the integrin receptor distribution in Rous sarcoma virus-induced tumors has been shown to be altered, but the levels were increased (42). Thus, a diversity of alterations in

Address correspondence to Jouni Uitto, M.D., Ph.D., Department of Dermatology, Thomas Jefferson University, 1020 Locust St., Room M-46 Jefferson Alumni Hall, Philadelphia, PA 19107.

Received for publication 29 June 1990 and in revised form 11 October 1990.

*J. Clin. Invest.*

© The American Society for Clinical Investigation, Inc.

0021-9738/91/03/0811/10 \$2.00

Volume 87, March 1991, 811-820

integrins can be found in different tumors. Consequently, it is of interest to study how the multiple cell types present in neurofibromas interact with the extracellular matrix in a manner contributing to the growth and development of these tumors.

In this study, we have examined the distribution of integrins in human fetal and adult peripheral nerve, as well as in cutaneous neurofibromas and in a benign schwannoma, using indirect immunofluorescence with antibodies recognizing the  $\beta 1$ ,  $\alpha 2$ ,  $\alpha 3$ , or  $\alpha 5$  subunits of  $\beta 1$  integrins. Furthermore, the integrin expression was examined in cell cultures established from human fetal nerves or from neurofibromas. The results indicate a selective and specific expression of different  $\beta 1$  integrins in vivo and in vitro, suggesting that they may play a role in the development and neoplasia of neural tissues.

## Methods

**Tissue specimens.** Normal human femoral nerve tissue was obtained from autopsy of a 31-yr-old apparently healthy male who had died in an accident. Fetal sciatic nerve tissue was excised from two apparently normal fetuses, 19 and 20 wk of gestational age. Cutaneous neurofibromas excised for cosmetic reasons were obtained from seven patients with classic features of type 1 neurofibromatosis (von Recklinghausen's disease), and a benign schwannoma was removed from an otherwise healthy individual.

**Cell cultures.** Human nerve cell cultures were established from fetal sciatic nerves by explantation method, and the cells were allowed to grow onto acetylated glass slides (43). The cultures were maintained in DMEM, which contained antibiotics (100 U/ml penicillin-G, and 50  $\mu$ g/ml streptomycin sulfate) and 10% FCS (Flow Laboratories, Inc., McLean, VA). Cell cultures were also established from neurofibroma specimens, as described previously (43). Cells were fixed for immunostaining in cold ( $-20^{\circ}\text{C}$ ) ethyl alcohol for 15 min.

**Indirect immunofluorescence.** For indirect immunofluorescence, 5- $\mu$ m-thick frozen sections were rinsed with Tris-buffered saline (TBS, pH 7.6), and preincubated for 15 min with TBS containing 1% BSA. The samples were then exposed to primary antibody in appropriate dilutions (in TBS-BSA) overnight at  $4^{\circ}\text{C}$ . The sections were washed in TBS for 60 min with five changes, and incubated either with FITC- or with tetramethyl-rhodamine isothiocyanate (TRITC)-conjugated secondary antibodies. After a 60-min incubation at room temperature, the sections were washed with TBS for 60 min, rinsed with distilled water, and examined with a fluorescence microscope (Nikon Optiphot), equipped with filters for detection of FITC and TRITC. Representative sections were photographed using Kodak Tri-X film. In control reactions, the primary antibody was omitted or replaced with sera from nonimmunized animals. Faint uniform background only was observed in all controls.

**Antibodies.** Characterization of antibodies 3847 and J143 recognizing the  $\alpha 5/\beta 1$  and  $\alpha 3$  epitopes, respectively, has been reported previously (44, 45), and properties of the other antibodies are briefly as follows. Antibody F17-6D7 is a mouse monoclonal antibody raised against human platelets that binds specifically to glycoprotein Ia/IIa (46), and recognizes the  $\alpha 2$  subunit epitopes. Antibodies 13 and 16 are both IgG<sub>2a</sub> of rat origin raised against purified human fibronectin receptor. Antibody 13 recognizes both the mature and precursor forms of  $\beta 1$  subunits according to immunoprecipitation and biological specificity criteria. Antibody 16 recognizes  $\alpha 5$  subunits according to immunoprecipitation criteria. Both antibodies 13 and 16 are described in detail elsewhere (1).

The monoclonal antibodies were used in a final IgG concentration of 50  $\mu$ g/ml. The polyclonal anti-human fibronectin receptor antiserum 3847 was used at a 1:100 dilution. Monoclonal antibodies to human type IV collagen were purchased from ICN Biochemicals (Lisle, IL) and monoclonal antibodies to neurofilament protein were from Biomakor (Rehovot, Israel).

## Results

### *Immunolocalization of $\beta 1$ integrins in adult peripheral nerve.*

To examine the expression of integrins in normal, fully developed human nerve, frozen sections were prepared from the femoral nerve obtained from a 31-yr-old apparently healthy male who died in an accident. The overall distribution of  $\beta 1$  integrins was first determined by immunostaining with monoclonal antibody 13 recognizing the extracellular domain of  $\beta 1$ . A prominent staining reaction was noted within all layers of perineurium and in endoneurium in association with Schwann cells (Fig. 1 *a*). The staining was, however, patchy and showed differences in the staining intensity between adjacent Schwann cells. Double immunofluorescence with antibodies to  $\alpha 5/\beta 1$  receptor and neurofilament protein, which allowed visualization of axons, revealed that Schwann cells surrounding small-diameter axons expressed the  $\beta 1$  epitopes at apparently higher levels than those associated with large-diameter axons (Fig. 2). The epineurium was largely negative for  $\beta 1$  expression, but blood vessel walls clearly demonstrated the presence of  $\beta 1$  epitopes.

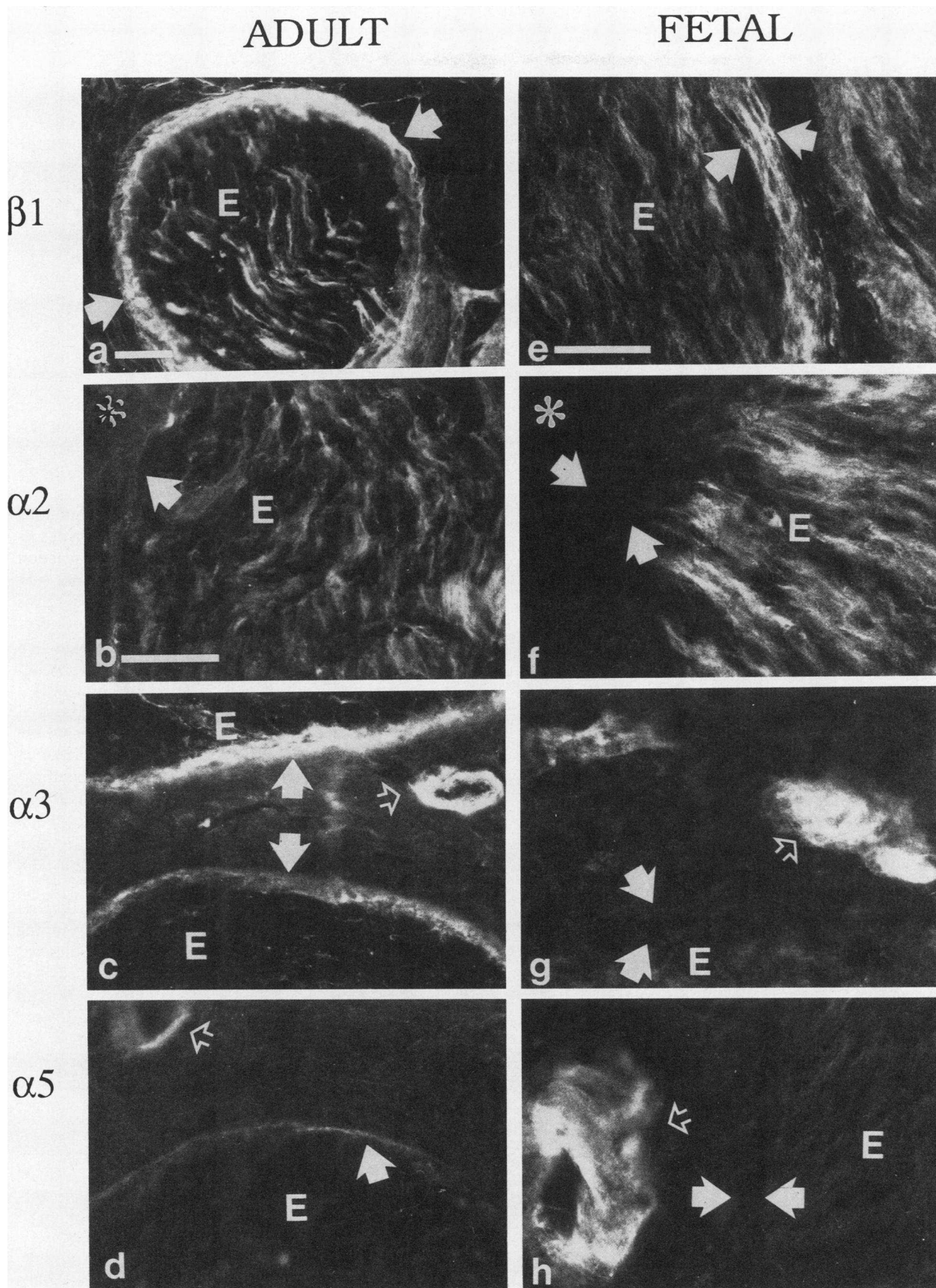
Monoclonal antibodies recognizing  $\alpha 2$ ,  $\alpha 3$ , or  $\alpha 5$  subunits were used in further studies to compare the distribution of specific  $\beta 1$  integrins within the nerve. Positive staining reaction with monoclonal antibody F17-6D7 recognizing the  $\alpha 2$  subunit was detected in association with Schwann cells, whereas the perineurium and epineurium were essentially devoid of staining reaction (Fig. 1 *b*). Staining of parallel sections with the J143 antibody against the  $\alpha 3$  subunit revealed a prominent staining of perineurial cells and blood vessel walls, but only a faint staining was observed within the endoneurium (Fig. 1 *c*).

Staining with monoclonal antibody 16 recognizing the extracellular domain of the  $\alpha 5$  subunit revealed a variable, often faint, and somewhat diffuse pattern associated with the innermost compartment of perineurium and with blood vessel walls (Fig. 1 *d*). Thus, the data, summarized in Table I, indicate that different structures within a mature, fully developed human nerve demonstrate selective expression of the  $\beta 1$  integrin subunits.

### *Immunolocalization of integrins in developing fetal nerve.*

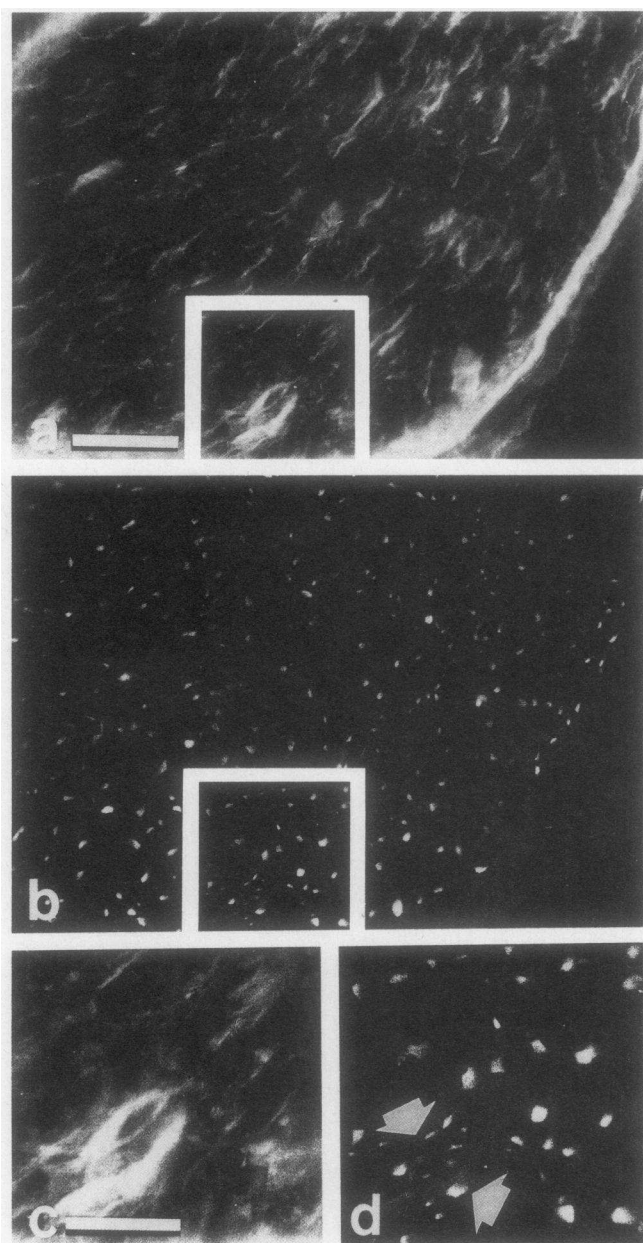
To examine the distribution of  $\beta 1$  integrins in developing nerve, immunostaining with the same panel of antibodies was performed on frozen sections of the sciatic nerve obtained from 19- and 20-wk-old fetuses. The overall staining pattern with polyclonal antibodies to  $\beta 1$  subunit was similar to that demonstrated in adult nerve (Fig. 1 *e*). However, the intensity of immunoreaction between different Schwann cells was more uniform than that in the adult nerve. The  $\alpha 2$  subunit epitopes could also be recognized on Schwann cells in a similar manner as in the adult nerve (Fig. 1 *f*).

The major difference between the staining patterns of fetal and adult nerves was the lack of  $\alpha 3$  subunit epitopes in fetal perineurium (Fig. 1 *g*). In the fetal nerve trunk, only the vessel walls showed intense positive staining (Fig. 1 *g*). The staining of fetal endoneurium with antibody to  $\alpha 3$  subunit was very weak, as was also noted in the adult nerve (see above). Similarly, staining with antibody to  $\alpha 5$  subunit revealed clearly detectable reaction only on the blood vessels, associated with the fetal nerve (Fig. 1 *h*). In few isolated fields, a faint staining with the antibody to the  $\alpha 5$  subunit was noted in perineurium (not shown). Thus, the integrin expression pattern in fetal nerve, as summarized in Table I, was different from that noted in ma-



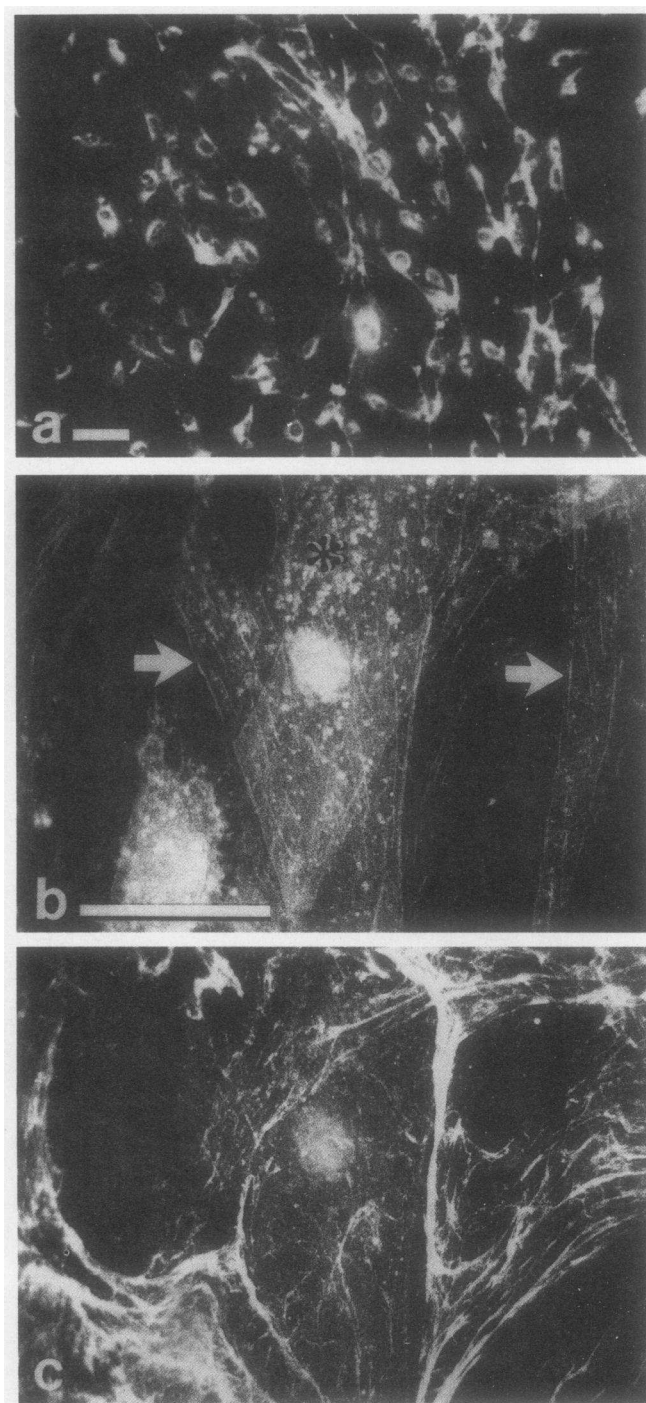
**Figure 1.** Immunostaining of adult (a–d) and fetal (e–h) nerve with monoclonal antibodies recognizing  $\beta 1$  (a, e),  $\alpha 2$  (b, f),  $\alpha 3$  (c, g), or  $\alpha 5$  (d, h) epitopes. Note the prominent staining for  $\beta 1$  and  $\alpha 3$  epitopes throughout the perineurium (arrows in a, c, e), and staining for  $\alpha 2$  epitopes on the outer aspects of Schwann cell tubes in the endoneurium (E in b, f). Also note that epineurium (asterisk) and perineurium (arrows) are devoid of  $\alpha 2$  integrin epitopes (b, f). Note the staining reaction on blood vessel walls (open arrow) (c, d, g, h). Frames b–d have the same magnification. Bars a and b, 100  $\mu\text{m}$ . Frames e–h have the same magnification. Bar, 50  $\mu\text{m}$ .





**Figure 2.** Double immunofluorescence staining with polyclonal antibodies to  $\beta 1/\alpha 5$  integrin receptor (*a, c*) and with antineurofilament protein antibodies (*b, d*). Frames *c* and *d* represent enlargements of the boxed areas outlined in *a* and *b*, respectively. Note a group of small diameter axons (*d, arrows*). Also note the prominent immunoreaction in the same location most likely in association with Schwann cell surfaces (*c*). The resolution of the indirect immunofluorescence technique used in this study did not allow definite conclusions as to whether  $\beta 1$  integrin epitopes were present also at the axon-Schwann cell contact sites. Bars, *a* and *b*, 100  $\mu\text{m}$ ; *c* and *d*, 50  $\mu\text{m}$ .

ture adult nerve, especially in the perineurium, suggesting that certain integrins are important for maintaining the homeostasis of a mature, fully developed nerve, whereas different adhesion mechanisms may be operative during fetal nerve development. The differences in the expression of  $\alpha 3$  and  $\alpha 5$  subunits may reflect the different composition of the extracellular matrix in fetal perineurium as compared to the adult perineurium.



**Figure 3.** Expression of  $\beta 1$  integrin receptors and type IV collagen epitopes on cultured fetal nerve connective tissue cells. The cultures were stained with polyclonal antibodies to  $\beta 1/\alpha 5$  integrin (*a*), or double stained with antibodies to type IV collagen and  $\beta 1/\alpha 5$  integrin complex (*b* and *c*). Essentially all cells in culture expressed the  $\beta 1$  integrins (*a*). Immunostaining of perineurial cells revealed granular (asterisk) and streaklike (arrows) distribution of  $\beta 1$  epitopes (*b*). Double immunofluorescence of the field shown in *b* with antibodies to type IV collagen (*c*) revealed no apparent colocalization of  $\beta 1$  and type IV collagen epitopes (*b* and *c*). Bar, *a*, 100  $\mu\text{m}$ ; *b* and *c*, 50  $\mu\text{m}$ .

Also, in developing nerve, the perineurial cells are not in contact with adjacent cells while in adult perineurium these cells overlap and form tight junctions (26, 47).

Table I. Expression of  $\alpha 2$ ,  $\alpha 3$ , and  $\alpha 5$  Subunits of  $\beta 1$  Integrins in Mature and Developing Human Nerves

Compartment	$\alpha$ Subunit epitopes of $\beta 1$ integrins		Potential ligand molecules in peripheral nerve compartments
	Adult nerve	Fetal nerve	
Endoneurium (Schwann cells)	$\alpha 2$	$\alpha 2$	Merosin, laminin, type IV collagen,* type I, III, V, and VI collagens <sup>‡</sup>
Perineurium (perineurial cells)	$\alpha 3$	none	S-Laminin, laminin, type IV collagen, <sup>§</sup> type I, III, V and VI collagens, fibronectin <sup>  </sup>
Epineurium (epitopes on blood vessel wall)	$\alpha 3$ , $\alpha 5$	$\alpha 3$ , $\alpha 5$	Laminin, type IV collagen, <sup>¶</sup> type I, III, and VI collagens, fibronectin**

\* In the Schwann cell basement membrane (24, 50). <sup>‡</sup> In the endoneurial connective tissue ensheathing the Schwann cell tubes (39, 57). <sup>§</sup> In perineurial basement membranes (24, 55). <sup>||</sup> Between perineurial cell layers in the endo- and epineurial connective tissue adjacent to perineurium (39, 57). <sup>¶</sup> In endothelial basement membranes (33, 34). \*\* In the epineurial connective tissue (39, 57).

*Expression of  $\beta 1$  integrins in cell cultures derived from fetal nerve.* To examine more precisely the individual cells that may express the  $\beta 1$  integrins, primary cell cultures composed of Schwann cells, perineurial cells, and fibroblasts, were established from fetal nerve tissue, as described previously (43, 48, 49). All these three cell types expressed the  $\beta 1$  integrins in culture (Fig. 3, *a* and *b*). A diffuse perinuclear staining was noted within most cells apparently representing newly synthesized intracellular pool of  $\beta 1$  subunit epitopes. A diffuse, spotty, or streaklike staining was also present at the periphery of most cells, possibly identifying epitopes on focal adhesion sites on the cell surface (12).

To examine the expression of different  $\alpha$  subunits in further detail, the same monoclonal antibodies employed for immunostaining of tissue sections were used on cultured cells. Staining with antibody recognizing the  $\alpha 2$  subunit revealed a punctate distribution on all three cell types studied (Fig. 4, *a–c*, Table II). We have previously shown that laminin on cultured perineurial cells also shows a similar punctate distribution (49), suggesting that  $\alpha 2/\beta 1$  complex may function as a collagen/laminin receptor (8) on these cells.

Staining with a monoclonal antibody recognizing the  $\alpha 5$  subunit revealed rather diffuse, yet uniform staining throughout the individual Schwann cells (Fig. 4 *d*). Interestingly, Schwann cells do not have fibronectin epitopes on their surface, which implies that the  $\alpha 5/\beta 1$  receptor is nonfunctional as a "classical" fibronectin receptor in these cells, or  $\alpha 5/\beta 1$  complex may mediate binding to other ligands. In contrast, immunofluorescence stainings of perineurial cells for the  $\alpha 5$  subunit recognized the presence of epitopes in a linear streaklike pattern, suggesting that  $\alpha 5/\beta 1$  integrin complex may function as a fibronectin receptor in these cells (15, 49). The fibroblastic cells demonstrated a somewhat variable and diffuse staining pattern (Fig. 4 *f*). Some cells showed evidence of a streaklike arrangement of the  $\alpha 5$  epitopes, whereas in other cells a perinuclear distribution was apparent. Thus, Schwann cells, perineurial cells, and fibroblasts can express the  $\alpha 2$  and  $\alpha 5$  subunits in culture (Table II), although the staining pattern on different cells is variable, and  $\alpha 2/\beta 1$  and  $\alpha 5/\beta 1$  receptors may have different ligand specificities in these three cell types.

Interestingly, the staining pattern with a monoclonal antibody recognizing  $\alpha 3$  epitopes was entirely different. Cultured perineurial cells and fibroblasts were apparently devoid of  $\alpha 3$  epitopes (Fig. 5, *a* and *c*), whereas a perinuclear and diffuse

staining was recognized in Schwann cells. These cells were identified as Schwann cells also on the basis of apparent lack of fibronectin epitopes on the cell surface (Fig. 5 *b*). In addition, an intense immunoreaction for  $\alpha 3$  epitopes was seen between adjacent Schwann cells suggesting that  $\alpha 3/\beta 1$  integrin complex may mediate cell–cell interactions of cultured Schwann cells in a manner described for other human cell types in vitro (14, 15). The negative immunostaining of perineurial cells and fibroblasts is unlikely to be due to epitope masking, because Schwann cells in the same cultures stained with this antibody, and the  $\alpha 2$ ,  $\alpha 5$ , and  $\beta 1$  subunits were readily detectable on these cell types in the same culture (Table II). Thus, it appears that perineurial cells and fibroblasts in cultures established from fetal nerve do not express the  $\alpha 3$  subunit and that these cells do not use  $\alpha 3/\beta 1$  integrin complex as a collagen, laminin, or fibronectin receptor. It should also be noted that double stainings utilizing a monoclonal antibody to type IV collagen and polyclonal antibodies to the  $\beta 1$  integrin subunit did not demonstrate any apparent colocalization of these epitopes suggesting that the interaction of type IV collagen and nerve-derived connective tissue cells are not mediated through  $\beta 1$  integrins.

*Integrin expression in cutaneous neurofibromas and a benign schwannoma.* Previous studies have suggested that integrin expression is altered in neoplastic lesions and in virally transformed cells (18, 42). Neurofibromas are benign neural tumors composing of a heterogenous cell population of

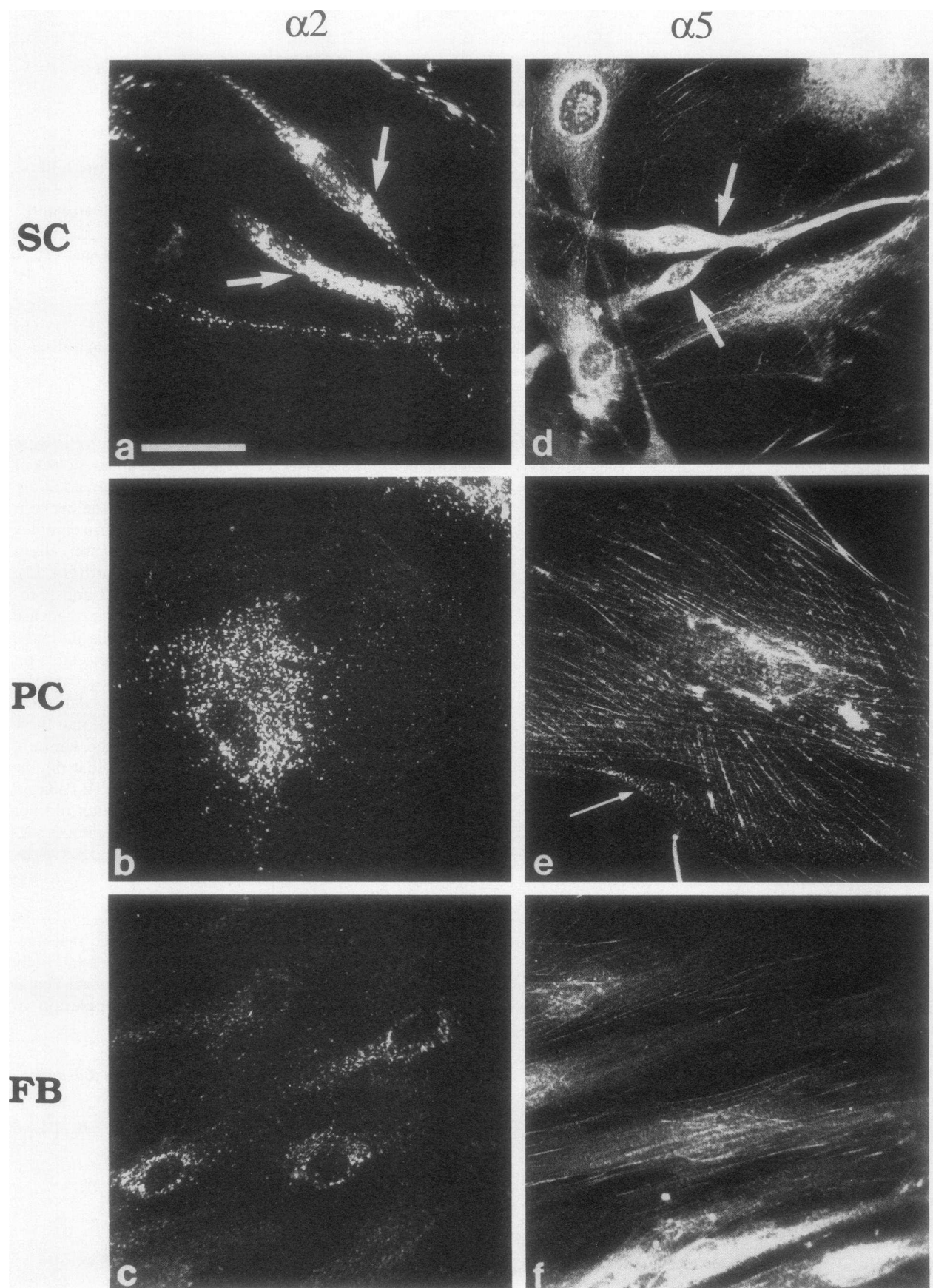
Table II. Comparison of the Expression Profiles of  $\alpha$  Subunits of VLA Integrins by Neural Connective Tissue Cells In Vivo and In Vitro

Cell type	$\alpha$ Subunit epitopes	
	In vivo	In vitro*
Schwann cell	$\alpha 2$	$\alpha 2$ , $\alpha 3$ , $\alpha 5$
Perineurial cell	$\alpha 3$ <sup>‡</sup>	$\alpha 2$ , $\alpha 5$
Fibroblast	None <sup>§</sup>	$\alpha 2$ , $\alpha 5$

\* In cultures established from human fetal nerve and cutaneous neurofibromas.

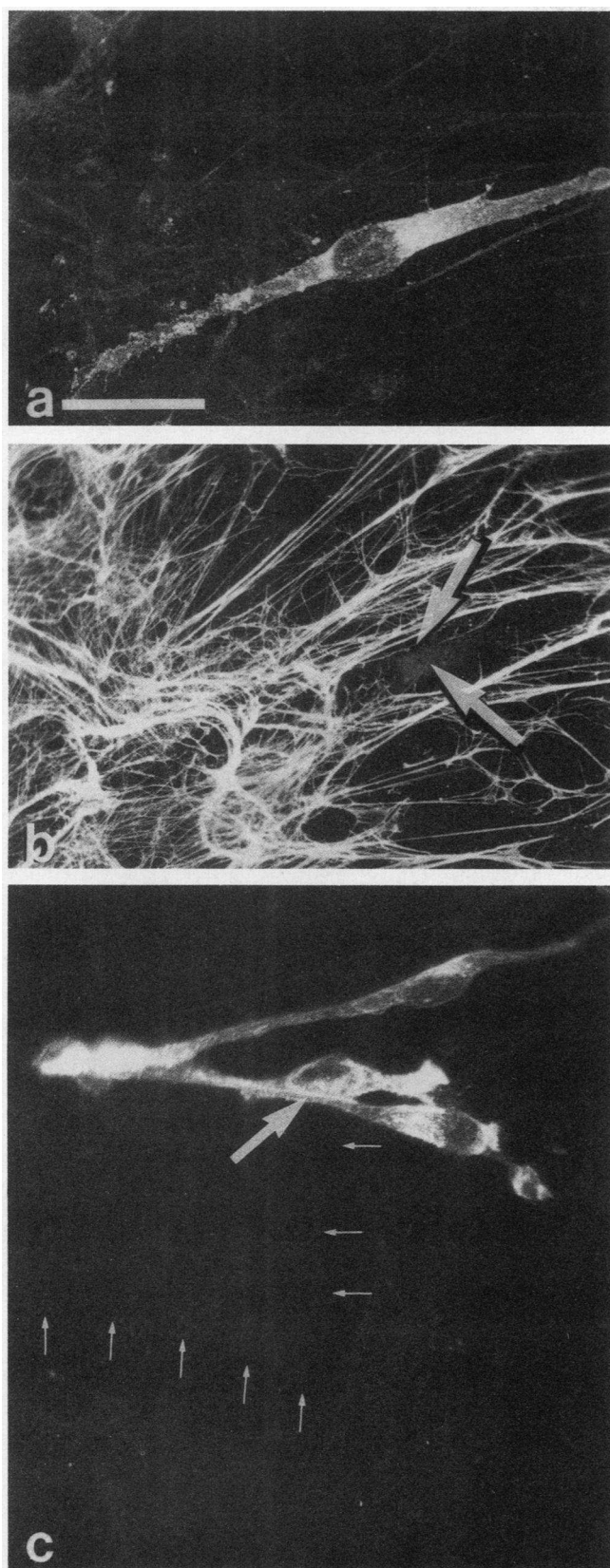
<sup>‡</sup> Expressed in adult but not in fetal nerve perineurium.

<sup>§</sup> In the epineurium.



**Figure 4.** Immunostaining of Schwann cells (SC) (*a* and *d*, arrows), perineurial cells (PC) (*b*, *e*), and fibroblasts (FB) (*c*, *f*) in cultures established from a fetal nerve. The cultures were stained with monoclonal antibodies recognizing either the  $\alpha 2$  (*a*–*c*) or  $\alpha 5$  (*d*–*f*) epitopes. Note the presence of two different staining patterns for  $\alpha 5$  integrin epitopes, either linear streaklike or punctate (arrow), on a perineurial cell in *e*. All frames have the same magnification. Bar, 50  $\mu\text{m}$ .





**Figure 5.** Immunofluorescence staining of cell cultures established from a fetal sciatic nerve with a monoclonal antibody recognizing the  $\alpha 3$  integrin epitopes (c) or double stained with polyclonal antibody for fibronectin epitopes (b) and  $\alpha 3$  integrin epitopes (a). Note that positive staining for  $\alpha 3$  epitopes is observed only on Schwann cells

Schwann cells, perineurial cells, and fibroblasts (35, 36). It was of interest, therefore, to examine the integrin expression in these tumors. The presence of  $\beta 1$  integrins was demonstrated in association with most cells, and prominent staining was also noted on blood vessel walls and epithelial structures embedded within neurofibromas (Fig. 6 a).

Staining with antibodies specific to  $\alpha 2$  and  $\alpha 3$  subunits revealed that most of the stromal cells were similarly positive for these epitopes (Fig. 6, b and c). Thus, on a statistical basis it seems likely that Schwann cells, perineurial cells, and fibroblasts express both  $\alpha 2$  and  $\alpha 3$  integrin subunits in neurofibromas. The antibody to  $\alpha 3$  subunit also stained the vascular structures within neurofibromas, while the antibodies to  $\alpha 2$  subunit did not yield a positive staining reaction on the blood vessels. In contrast, staining with the antibody to the  $\alpha 5$  subunit yielded negative staining on the tumor stroma, but the vascular structures were clearly positive for these epitopes (Fig. 6 d). Thus, different structures within cutaneous neurofibromas have selective expression of the  $\alpha$  subunits of  $\beta 1$  integrins.

To examine the integrin expression specifically on Schwann cells, sections of a benign schwannoma, tumor consisting of Schwann cells (36), were also stained with the same panel of specific antibodies. The results in general were the same as those noted with neurofibromas, i.e., the  $\beta 1$ ,  $\alpha 2$ , and  $\alpha 3$  epitopes were readily detected within the stroma of the tumor, whereas the staining for  $\alpha 5$  epitopes was essentially negative (results not shown).

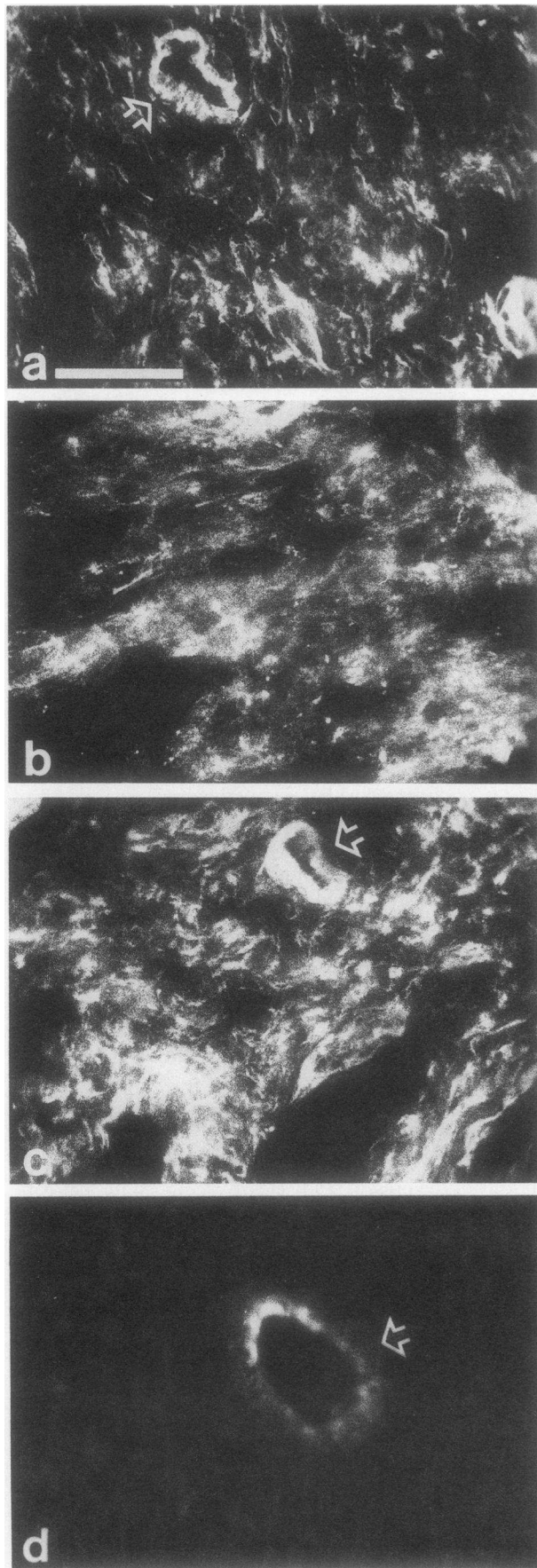
To explore the integrin expression on individual cells that can be readily identified under cell culture conditions, primary cultures were established from cutaneous neurofibromas. As reported previously, Schwann cells, perineurial cells, and fibroblasts can be identified within these cultures by morphologic and immunocytochemical criteria (43, 49). Staining with antibodies to different integrin subunits revealed a general staining pattern similar to that noted in cell cultures established from developing fetal human nerve. However, staining with antibodies to  $\alpha 3$  subunit was not limited to Schwann cells, but perineurial cells and fibroblasts also exhibited a faint yet clearly detectable staining reaction. The differences in the expression of  $\alpha 3$  subunit epitopes may reflect the degree of differentiation between the fetal nerve-derived cells and those derived from cutaneous neurofibromas.

## Discussion

The results of the present study clearly demonstrate that connective tissue cells of human peripheral nerve, i.e., Schwann cells, perineurial cells, and fibroblasts, express markedly different patterns of  $\beta 1$  integrin receptors and that each cell type expresses different receptor profiles under in vivo and in vitro conditions. Furthermore, the results indicate that the expression of these integrin receptors in a developing fetal nerve is different from that detected in a mature nerve.

and in contact sites between adjacent cells (large arrow, c), whereas perineurial cells (small arrows) and several fibroblasts present in the same field are clearly negative for immunostaining (a, c). Double immunofluorescence staining of the same culture as shown in panel a with antifibronectin antibodies (b) reveals that the Schwann cell (large arrows) does not contain fibronectin epitopes on its surface. Bars, 50  $\mu$ m.





**Expression of  $\beta 1$  integrins by Schwann cells.** Immunostaining experiments showed that  $\beta 1$  subunit was expressed in fetal nerve on virtually all Schwann cells on the outer surface facing the endoneurial connective tissue matrix. In the adult nerve, however, there were marked differences in the intensity of the staining reaction leading to a patchy staining pattern in the endoneurium. Double immunofluorescence staining utilizing antibodies to neurofilament protein, together with antibodies to  $\beta 1$  subunit revealed that those Schwann cells which showed an intense staining reaction on their surface apparently ensheathed a group of small-diameter axons in adult nerve. Because fetal nerve contained only small-diameter axons, the intense staining reaction on all Schwann cells suggested that the expression of integrin receptors by these cells may be regulated, in part, by the axonal contacts. The resolution of the indirect immunofluorescence technique used in this study did not allow, however, definite conclusions as to whether  $\beta 1$  integrin epitopes were present also at the axon-Schwann cell contact sites.

Immunostainings of adult and fetal nerve utilizing monoclonal antibodies to  $\alpha 2$ ,  $\alpha 3$ , and  $\alpha 5$  subunits revealed that only  $\alpha 2$  epitopes were present on Schwann cell surfaces. The  $\alpha 2/\beta 1$  integrin receptor complex is thus likely to have a major role in mediating the interactions between Schwann cells and endoneurial connective tissue. Schwann cells are surrounded by a basement membrane composed of laminin, merosin, and type IV collagen (24, 50, 51). All these components are potential candidate ligand molecules for Schwann cell matrix interaction because the  $\alpha 2/\beta 1$  complex has been shown to function both as collagen and as laminin receptor (8). Schwann cells are also capable of expressing a variety of other extracellular matrix components, including collagen types I, III, IV, and VI, but not fibronectin (39, 43). The  $\alpha 2(\text{VI})$  and  $\alpha 3(\text{VI})$  collagen chains have been shown to contain functional RGD sequences (52). In addition, type VI collagen epitopes are intimately associated with Schwann cell tubes of peripheral nerves (39). Thus, the  $\alpha 2/\beta 1$  integrin, which mediates binding to various collagen types and laminin, could be postulated to have a multifunctional role in the mediating contacts between Schwann cells and the endoneurial matrix in human adult and fetal nerve.

In contrast to  $\alpha 2$ , the  $\alpha 3$  epitopes were not found on Schwann cells in normal fetal or adult nerve. However, neoplastic Schwann cells in benign schwannomas and cutaneous neurofibromas, as well as cultured Schwann cells readily expressed the  $\alpha 3$  integrin epitopes, indicating that Schwann cells have the potential to express this subunit. The absence of  $\alpha 3$  subunit on Schwann cells *in vivo* suggests that the expression of this subunit may be downregulated in the presence of mature, large-diameter axons. Several studies have shown that the differentiation of Schwann cells is regulated by axonal contact and that this contact also regulates the expression of extracellular matrix components by Schwann cells (53). Similar mechanisms may be operative in the expression of extracellular matrix receptors as well. In support of the latter interpretation is

**Figure 6.** Expression of  $\beta 1$  integrins in neurofibroma tissue, as detected by immunofluorescence staining with antibodies to  $\beta 1$  (a),  $\alpha 2$  (b),  $\alpha 3$  (c), or  $\alpha 5$  (d) subunit epitopes. Open arrows denote positive staining reaction on blood vessel walls. All frames have the same magnification. Bar, 50  $\mu\text{m}$ .

also the observation that under the cell culture conditions utilized, where Schwann cells are devoid of axonal contact, the expression of  $\alpha 3$  subunit is readily observed. Interestingly,  $\alpha 3$  epitopes were located also between cultured Schwann cells suggesting a possible role for  $\alpha 3/\beta 1$  integrin receptor complex in Schwann cell-Schwann cell interactions in vitro. Our recent studies have shown that human epidermal keratinocytes, both in vivo and under culture conditions, use  $\beta 1$  integrins for cell-cell interactions (15).

It was of special interest to note that cultured Schwann cells readily expressed the  $\alpha 5$  epitopes, yet no fibronectin, the putative ligand for the  $\alpha 5/\beta 1$  integrins, could be detected by indirect immunofluorescence. The  $\alpha 5/\beta 1$  receptor complex on Schwann cell surfaces may not be a functional fibronectin receptor or it may have different, yet unknown ligands.

**Expression of  $\beta 1$  integrins by perineurial cells.** Mature perineurium showed an intense staining reaction with an antibody to the  $\alpha 3$  integrin subunit, whereas the expression in fetal nerve was undetectable. In contrast to Schwann cells, perineurial cells in fetal and adult nerve were apparently devoid of  $\alpha 2$  epitopes. These observations may correlate with differences in the distribution of potential ligand molecules. Specifically, the basement membrane on Schwann cells contains merosin, a molecule with homology to the A chain of laminin (50, 54). Also, Schwann cell cultures synthesize a form of laminin which apparently lacks A chain or synthesize a shortened A chain (21). A recently described basement membrane component, S-laminin is clearly present in the perineurial basement membranes (55), whereas merosin could not be detected in perineurium (50). Thus, further characterization of ligand binding specificity of the  $\alpha$ -subunits, with respect to S-laminin and merosin, is required to elucidate their functional role in further detail. It is of interest, however, that recent cloning and sequence analyses of cDNAs encoding human laminin A chain have also disclosed the presence of an Arg-Gly-Asp (RGD) sequence, a potential cell binding site interacting with integrins on the cell surface (54, 56). In addition to its cell binding activity, other biological functions attributed to laminin include binding to basement membrane collagen type IV or to polyanionic heparin and heparan sulfate proteoglycan (34).

Perineurium has an essential role in maintaining the proper structure and homeostasis of the peripheral nerve by forming a selective diffusion barrier between the epineurium and the endoneurium, the innermost compartment of the nerve (30). The perineurium of the fetal nerve differs structurally from the mature perineurium, suggesting that its diffusion barrier function is largely undeveloped (47). Consequently, the differences noted in  $\alpha 3$  subunit expression between adult and fetal perineurial cells in vivo may be related to the developmental stage, especially to the presence or absence of basement membranes in this structure. The absence of the expression of  $\alpha 3$  subunit, which mediates the binding of a variety of extracellular matrix ligands, including fibronectin, laminin, and various collagen types, may have functional consequences in terms of altered perineurial cell-cell and cell-matrix interactions. With maturation of the perineurium, the expression of  $\alpha 3$  subunit may contribute to the functional role this structure plays in nerve physiology. At the same time, neurofibromas which consist of perineurial cells, together with Schwann cells and fibroblasts, express the  $\alpha 3$  subunit. Thus, the low level of expression of  $\alpha 3$  subunit in fetal perineurium and corresponding cell cultures

may relate, in part, to the early stage of fetal development of these cells.

Essentially no expression of the  $\alpha 5$  subunit epitopes was detected in fetal and adult peripheral nerve, with the exception of faint immunoreaction on the blood vessel walls and occasionally associated with the innermost cell layer of the perineurium.

Comparison of the expression of different  $\alpha$  subunits in cell cultures established from human fetal nerve revealed that the  $\alpha$  subunits were expressed in a differential manner in vivo and in vitro (Table II). Specifically, the expression of  $\alpha 2$  subunit which was absent in perineurium and epineurium in vivo was observed on perineurial cells and fibroblasts in culture. Also, the  $\alpha 5$  epitopes were readily detectable on cultured Schwann cells, perineurial cells, and fibroblasts. Thus, different regulatory signals apparently control the expression of  $\alpha 2$  and  $\alpha 5$  subunits in vitro and in vivo.

The data of the present study suggest that the  $\alpha 3/\beta 1$  integrin complex is particularly sensitive to regulatory factors and it may play an important role during the development of peripheral nerve, as well as in the development and growth of tumors affecting neural connective tissue compartments. These observations also emphasize the regulatory role of cell-cell and cell-matrix interactions within the nerve tissue, and further attest to the plasticity of gene expression by nerve-derived connective tissue cells.

## Acknowledgments

The skillful technical assistance of Mary Lou Gregory and Leslie Jubbinski Wright is gratefully acknowledged. Charlene D. Aranda assisted in the preparation of this manuscript. The authors thank Drs. Kenneth M. Yamada, Steven K. Akiyama, and Susan S. Yamada for providing antibodies.

Supported in part by United States Public Health Service, National Institutes of Health grants AR-38923, AR-35297, and T32 AR-7561, by the general and Päijät-Häme Divisions of the Finnish Cultural Fund, The Maunula Foundation, and the Finnish Academy of Sciences.

## References

1. Ruoslahti, E. 1991. Integrins. *J. Clin. Invest.* 87:1-5.
2. Buck, C. A., and A. F. Horwitz. 1987. Cell surface receptors for extracellular matrix molecules. *Annu. Rev. Cell Biol.* 3:179-205.
3. Hynes, R. O. 1987. Integrins: a family of cell surface receptors. *Cell.* 48:549-554.
4. Ruoslahti, E., and M. D. Pierschbacher. 1987. New perspectives in cell adhesion: RGD and integrins. *Science (Wash. DC)*. 238:491-497.
5. Hemler, M. E., C. Huang, and L. Schwarz. 1987. The VLA protein family: characterization of five distinct cell surface heterodimers each with a common 130,000 M subunit. *J. Biol. Chem.* 262:3300-3309.
6. Yamada, K. M. 1988. Fibronectin domains and receptors. In *Fibronectin*. D. F. Mosher, editor. Academic Press, Inc., New York. 47-121.
7. Juliano, R. L. 1987. Membrane receptors for extracellular matrix macromolecules: relationships to cell adhesion and tumor metastasis. *Biochim. Biophys. Acta.* 907:261-278.
8. Elices, M. J., and M. E. Hemler. 1989. The human integrin VLA-2 is a collagen receptor on some cells and a collagen/laminin receptor on others. *Proc. Natl. Acad. Sci. USA.* 86:9906-9910.
9. Kunicki, T. J., D. J. Nugent, S. J. Staats, R. P. Orchekowski, E. A. Wayner, and W. G. Carter. 1988. The human fibroblast class II extracellular matrix receptor mediated platelet adhesion to collagen and is identical to the platelet glycoprotein Ia-IIa complex. *J. Biol. Chem.* 263:4516-4519.
10. Takada, Y., E. A. Wayner, W. G. Carter, and M. E. Hemler. 1988. Extracellular matrix receptors, ECMRII and ECMRI, for collagen and fibronectin

- correspond to VLA-2 and VLA-3 in the VLA family of heterodimers. *J. Cell. Biochem.* 37:385-393.
11. Pytela, R., M. D. Pierschbacher, and E. Ruoslahti. 1985. Identification and isolation of a 140 kd cell surface glycoprotein with properties expected of a fibronectin receptor. *Cell* 40:191-198.
12. Wayner, E. A., W. G. Carter, R. Piotrowicz, and T. J. Kunicki. 1989. The function of multiple extracellular matrix receptors in mediating cell adhesion to extracellular matrix: preparation of monoclonal antibodies to the fibronectin receptor that specifically inhibit cell adhesion to fibronectin and react with platelet glycoproteins Ic/Ila. *J. Cell Biol.* 107:1881-1891.
13. Kirchhofer, D., L. R. Languine, E. Ruoslahti, and M. D. Pierschbacher. 1990.  $\alpha 2 \beta 1$  integrins from different cell types show different binding specificities. *J. Biol. Chem.* 265:615-618.
14. Kaufmann, R., D. Frösch, C. Westphal, L. Weber, and C. E. Klein. 1989. Integrin VLA-3: ultrastructural localization at cell-cell contact sites of human cell cultures. *J. Cell Biol.* 109:1807-1815.
15. Larjava, H., J. Peltonen, S. K. Akiyama, S. S. Yamada, H. R. Gralnick, J. Uitto, and K. M. Yamada. 1990. Novel function for  $\beta$ -1 integrins in keratinocyte cell-cell interactions. *J. Cell Biol.* 110:803-815.
16. Donaldson, D. J., and J. T. Mahan. 1988. Keratinocyte migration and the extracellular matrix. *J. Invest. Dermatol.* 90:623-628.
17. Edelman, G. M. 1985. Cell adhesion and the molecular process of morphogenesis. *Annu. Rev. Biochem.* 54:135-169.
18. Peltonen, J., H. Larjava, S. Jaakkola, H. Gralnick, S. K. Akiyama, S. S. Yamada, K. M. Yamada, and J. Uitto. 1989. Localization of integrin receptors for fibronectin, collagen and laminin in human skin: variable expression in basal and squamous cell carcinomas. *J. Clin. Invest.* 84:1916-1923.
19. Takada, Y., J. L. Strominger, and M. E. Hemler. 1987. The very late antigen family of heterodimers is part of a superfamily of molecules involved in adhesion and embryogenesis. *Proc. Natl. Acad. Sci. USA* 84:3239-3243.
20. Edgar, D., R. Timpl, and H. Thoenen. 1984. The heparin-binding domain of laminin is responsible for its effects on neurite outgrowth and neuronal survival. *EMBO (Eur. Mol. Biol. Organ.) J.* 3:1463-1468.
21. Edgar, D., R. Timpl, and H. Thoenen. 1988. Structural requirements for the stimulation of neurite outgrowth by two variants of laminin and their inhibition by antibodies. *J. Cell Biol.* 106:1299-1306.
22. Ohara, S., H. Takahashi, and F. Ikuta. 1986. Ultrastructural alterations of perineurial cells in the early state of Wallerian degeneration. *Lab. Invest.* 54:213-221.
23. Røytty, M., V. Salonen, and J. Peltonen. 1987. Reversible endoneurial changes after nerve injury. *Acta Neuropathol. (Berl.)* 73:323-329.
24. Salonen, V., J. Peltonen, M. Røytty, and I. Virtanen. 1987. Laminin in traumatized peripheral nerve. Basement membrane remodelling during degeneration and regeneration. *J. Neurocytol.* 16:713-720.
25. Salonen, V., H. Aho, M. Røytty, and J. Peltonen. 1988. Quantitation of Schwann cells and endoneurial fibroblast-like cells after experimental nerve trauma. *Acta Neuropathol. (Berl.)* 75:331-336.
26. Gamble, H. J. 1964. Comparative electron-microscopic observations on the connective tissue of a peripheral nerve and a spinal nerve root in the rat. *J. Anat.* 98:17-25.
27. Gamble, H. J., and R. A. Eames. 1964. An electron microscopy study of the connective tissues of human peripheral nerve. *J. Anat.* 98:655-663.
28. Thomas, P. K. 1963. The connective tissue of peripheral nerve: an electron microscopic study. *J. Anat.* 97:35-44.
29. Thomas, P. K., and Y. Olsson. 1984. Microscopic anatomy and function of the connective tissue components of peripheral nerve. In *Peripheral Neuropathy*. V. J. Dyck, P. K. Thomas, E. H. Lambert, and R. P. Bunge, editors. W. B. Saunders Co., Philadelphia.
30. Klemm, H. 1970. Das perineurium als diffusionsbarriere gegenüber peroxidase bei epi- und endoneuraler application. *Z. Zellforsch. Mikrosk. Anat.* 108:431-445.
31. Oldfors, A. 1981. Permeability of the perineurium of small nerve fascicles: an ultrastructural study using ferritin in rats. *Neuropathol. Appl. Neurobiol.* 7:183-194.
32. Farquhar, M. G. 1981. The glomerular basement membrane: a selective macromolecular filter. In *Cell Biology of the Extracellular Matrix*. E. Hay, editor. Plenum Publishing Co., New York. 335-378.
33. Martinez-Hernandez, A., and P. S. Amenta. 1983. The basement membrane in pathology. *Lab. Invest.* 48:656-677.
34. Timpl, R. 1989. Structure and biological activity of basement membrane proteins. *Eur. J. Biochem.* 180:487-502.
35. Peltonen, J., S. Jaakkola, M. Lebowitz, S. Renvall, L. Risteli, I. Virtanen, and J. Uitto. 1988. Cellular differentiation and expression of matrix genes in type 1 neurofibromatosis. *Lab. Invest.* 59:760-771.
36. Harkin, J. C. 1986. Pathology of nerve sheath tumors. *Ann. NY Acad. Sci.* 486:147-154.
37. Dziadek, M., D. Edgar, M. Paulsson, R. Timpl, and R. Fleischmajer. 1986. Basement membrane proteins produced by Schwann cells and in neurofibromatosis. *Ann. NY Acad. Sci.* 486:248-259.
38. Peltonen, J., J.-M. Foidart, and H. Aho. 1984. Type IV and V collagens in von Recklinghausen's neurofibromas. An immunohistochemical and electrophoretic study. *Virchows. Arch. B Cell. Pathol.* 47:291-301.
39. Peltonen, J., S. Jaakkola, L. L. Hsiao, R. Timpl, M.-L. Chu, and J. Uitto. 1990. Type VI collagen: *in situ* hybridizations and immunohistochemistry reveal abundant mRNA and protein levels in human neurofibroma, schwannoma and normal peripheral nerve tissues. *Lab. Invest.* 62:487-492.
40. Peltonen, J., R. Penttinen, H. Larjava, and H. Aho. 1986. Collagens in neurofibromas and neurofibroma cell cultures. *Ann. NY Acad. Sci.* 486:260-270.
41. Uitto, J., L. Y. Matsuoka, M.-L. Chu, T. Pihlajaniemi, and D. J. Prockop. 1986. Connective tissue biochemistry of neurofibromas. *Ann. NY Acad. Sci.* 486:271-286.
42. Saga, S., W.-T. Chen, and K. M. Yamada. 1988. Enhanced fibronectin receptor expression in Rous sarcoma virus-induced tumors. *Cancer Res.* 48:5510-5513.
43. Jaakkola, S., J. Peltonen, V. Riccardi, M. L. Chu, and J. Uitto. 1989. Type 1 neurofibromatosis: selective expression of extracellular matrix genes by Schwann cells, perineurial cells and fibroblasts in mixed cultures. *J. Clin. Invest.* 84:253-261.
44. Roberts, C. J., T. M. Birkenmeier, J. J. McQuillan, S. K. Akiyama, S. S. Yamada, W.-T. Chen, K. M. Yamada, and J. A. McDonald. 1988. Transforming growth factor  $\beta$  stimulates the expression of fibronectin and both subunits of the human fibronectin receptor by cultured human lung fibroblasts. *J. Biol. Chem.* 263:4586-4592.
45. Rettig, W. J., V. V. S. Murty, M. J. Mattes, R. S. K. Chaganti, and L. J. Old. 1986. Extracellular matrix-modulated expression of human cell surface glycoproteins A42 and J143: intrinsic and extrinsic signals determine antigenic phenotype. *J. Exp. Med.* 164:1581-1599.
46. Gralnick, H. R., L. P. McKeown, S. S. Williams, J. L. Lawrence, B. C. Schafer, W. S. Kramer, K. E. Hansmann, W. L. Vail, and L. E. Magruder. 1988. A murine monoclonal antibody that identifies a 157/130 kDa platelet-collagen receptor. *Circulation* 78(Suppl.):308. (Abstr.)
47. Gamble, H. J., and A. S. Breathnach. 1965. An electron-microscope study of human foetal peripheral nerves. *J. Anat.* 99:573-584.
48. Jaakkola, S., J. Peltonen, and J. Uitto. 1989. Perineurial cells co-express genes encoding interstitial collagens and basement membrane zone components. *J. Cell Biol.* 108:1157-1163.
49. Peltonen, J., S. Jaakkola, I. Virtanen, and L. Pelliniemi. 1987. Perineurial cells in culture. An immunocytochemical and electron microscopic study. *Lab. Invest.* 57:480-488.
50. Engvall, E., K. Ehrig, and I. Leivo. 1989. Merosin and laminin: molecular relationship and function on nerve-muscle development. *Ann. NY Acad. Sci.* 580:276-280.
51. Martin, G. R., and R. Timpl. 1987. Laminin and other basement membrane components. *Annu. Rev. Cell Biol.* 3:57-85.
52. Aumailley, M., K. Mann, K. von der Mark, and R. Timpl. 1989. Cell attachment properties of collagen type VI and Arg-Gly-Asp dependent binding to its  $\alpha 2(VI)$  and  $\alpha 3(VI)$  chains. *Exp. Cell Res.* 181:463-474.
53. Bunge, M. B., A. K. Williams, P. M. Wood, J. Uitto, and J. J. Jeffrey. 1980. Comparison of nerve cell and nerve cell plus Schwann cell cultures, with particular emphasis on basal lamina and collagen formation. *J. Cell Biol.* 84:184-202.
54. Olsen, D. R., T. Nagayoshi, M. Fazio, J. Peltonen, S. Jaakkola, D. Sanborn, T. Sasaki, H. Kuivaniemi, M.-L. Chu, R. Deutzmann, R. Timpl, and J. Uitto. 1989. Human laminin: cloning and sequence analysis of cDNAs encoding A, B1 and B2 chains, and the expression of corresponding genes in human skin and cultured cells. *Lab. Invest.* 60:772-782.
55. Hunter, D. D., V. Shah, J. P. Merlie, and J. R. Sanes. 1989. A laminin-like adhesive protein concentrated in the synaptic cleft of the neuromuscular junction. *Nature (Lond.)* 338:229-234.
56. Pierschbacher, M. D., E. Ruoslahti, J. Sundelin, P. Lind, and P. A. Peterson. 1982. The cell attachment domain of fibronectin. Determination of the primary structure. *J. Biol. Chem.* 257:9593-9597.
57. Salonen, V., M. Lehto, A. Vaheri, H. Aro, and J. Peltonen. 1985. Endoneurial fibrosis following nerve transection. An immunohistological study of collagen types and fibronectin in the rat. *Acta Neuropathol. (Berl.)* 67:315-321.