

Pathogenic effects of bullous pemphigoid autoantibodies on rabbit corneal epithelium.

G J Anhalt, ... , A Sugar, L A Diaz

J Clin Invest. 1981;68(4):1097-1101. <https://doi.org/10.1172/JCI110333>.

Research Article

Bullous pemphigoid (BP) is associated with circulating autoantibodies reactive with an antigen(s) of the basement membrane zone (BMZ) of skin and mucosae. The pathogenicity of these autoantibodies, although suspected, is unconfirmed. We have investigated the effects of BP autoantibodies on a closely related tissue, the corneal epithelium of the rabbit. IgG fractions from the sera of seven patients with BP were purified by (a) ammonium sulfate precipitation, (b) ion exchange chromatography, or (c) gel filtration. Control IgG was prepared by ion exchange chromatography of pooled normal human gamma globulins. 32 rabbits received corneal intrastromal injections of BP IgG fractions (50 microliter, 0.95-2.05 mg total dose) in one eye, and control IgG (50 microliter, 1.8 mg) in the contralateral cornea. 28 of 32 BP IgG injections produced corneal inflammatory lesions, 10 of which developed visible blisters. Histologically, lesions showed polymorphonuclear cells clustering along the BMZ, and subepithelial blister formation. Immunofluorescence showed in vivo bound IgG and C3 at the BMZ. The intensity of inflammation was dose dependent and correlated often with in vitro complement fixation titers of the fractions. None of 32 corneas injected with control IgG became inflamed. BP IgG fractions injected intradermally into the ear skin of rabbits failed to produce inflammation. This may be due to slow clearance of IgG in the cornea, and optimal binding by the [...]

Find the latest version:

<https://jci.me/110333/pdf>



Pathogenic Effects of Bullous Pemphigoid Autoantibodies on Rabbit Corneal Epithelium

GRANT J. ANHALT, CHARLES F. BAHN, RAMZY S. LABIB, JOHN J. VOORHEES, ALAN SUGAR, and LUIS A. DIAZ, *Immunodermatology Unit, Departments of Dermatology and Ophthalmology, University of Michigan, Ann Arbor, Michigan 48109; Veterans Administration Medical Center, Ann Arbor, Michigan 48105*

ABSTRACT Bullous pemphigoid (BP) is associated with circulating autoantibodies reactive with an antigen(s) of the basement membrane zone (BMZ) of skin and mucosae. The pathogenicity of these autoantibodies, although suspected, is unconfirmed. We have investigated the effects of BP autoantibodies on a closely related tissue, the corneal epithelium of the rabbit. IgG fractions from the sera of seven patients with BP were purified by (a) ammonium sulfate precipitation, (b) ion exchange chromatography, or (c) gel filtration. Control IgG was prepared by ion exchange chromatography of pooled normal human gamma globulins. 32 rabbits received corneal intrastromal injections of BP IgG fractions (50 μ l, 0.95–2.05 mg total dose) in one eye, and control IgG (50 μ l, 1.8 mg) in the contralateral cornea. 28 of 32 BP IgG injections produced corneal inflammatory lesions, 10 of which developed visible blisters. Histologically, lesions showed polymorphonuclear cells clustering along the BMZ, and subepithelial blister formation. Immunofluorescence showed *in vivo* bound IgG and C3 at the BMZ. The intensity of inflammation was dose dependent and correlated often with *in vitro* complement fixation titers of the fractions. None of 32 corneas injected with control IgG became inflamed. BP IgG fractions injected intradermally into the ear skin of rabbits failed to produce inflammation. This may be due to slow clearance of IgG in the cornea, and optimal binding by the corneal epithelium. The intracorneal injections of BP IgG reproduce the clinical, histological, and immunological features of BP. This study provides evidence that BP autoantibodies are pathogenic.

INTRODUCTION

In 1967 Jordon et al. (1) reported the presence of circulating antibodies in the serum of patients with

bullous pemphigoid (BP).¹ These autoantibodies are bound along the basement membrane zone (BMZ) of perilesional skin (2) and are reactive with an antigen(s) located in the lamina lucida of the BMZ of a variety of vertebrate squamous epithelia including skin and mucosae (3).

There is evidence that the circulating BP autoantibodies may be pathogenic *in vitro*. Recently, Gammon et al. (4) have shown that sections of normal human skin will fix BP autoantibodies, and when treated with a source of complement will produce attachment of peripheral blood leukocytes along the BMZ. However, systemic passive transfer of human BP plasma into animals had produced discouraging results (5). In these studies it was possible to detect *in vivo* binding of BP antibodies at the BMZ, but neither bullae nor inflammation was produced.

We studied the effects of BP autoantibodies on the corneal epithelium of the rabbit when injected locally into the stroma of the cornea. Intrastromal corneal injection of BP IgG produces lesions that reproduce the clinical, histological, and immunological features of BP.

METHODS

Experimental animals. New Zealand White rabbits (1.5–2.5 kg) were obtained from Langshaw Breeding Labs (Kalamazoo, Mich.).

Preparation of BP and control IgG fractions. Serum was obtained from seven patients with clinical, histological, and immunological features of BP. The IgG fractions from BP sera were prepared by three methods: (a) 40% ammonium sulfate precipitation (crude fraction), (b) DEAE-cellulose chromatography (DEAE fraction), and (c) Ultragel Ac-34 gel filtration chromatography (gel filtration fraction), following described methods (4). A commercial lot of Cohn fraction II (lot 11F-0149, Sigma Chemical Co., St. Louis, Mo.) prepared from pooled human sera of >1,000 normal donors was further purified by DEAE-cellulose chromatography and used as a control IgG fraction. Additional control IgG fractions were prepared from pooled normal human serum (four donors) by (a) 40% ammonium sulfate precipitation and (b) DEAE-cellulose chromatography. All fractions were extensively

Received for publication 11 June 1981 and in revised form 14 July 1981.

Abbreviations used in this paper: BMZ, basement membrane zone; BP, bullous pemphigoid.

dialyzed against phosphate-buffered saline, pH 7.2 and concentrated by ultrafiltration (Amicon Corp., Lexington, Mass., YM-10). The gel filtration fraction was free of IgA or IgM contaminants by double immunodiffusion using mono-specific antisera (Bio-Rad Laboratories, Richmond, Calif.). The BP IgG and control IgG fractions were sterilized by Millex filtration (Millipore Corp., Bedford, Mass., pore size 0.22 μm) or with a microfilter apparatus (Bioanalytical Systems, Inc. West Lafayette, Ind., pore size 0.2 μm) and incubated at 56°C for 30 min. These fractions were also tested for protease activity (6) using benzoyl arginine ethyl ester as substrate.

Intracorneal injection technique. After topical anesthesia with 0.5% proparacaine (Alcaine, Alcon Laboratories, Fort Worth, Tex.), 50 μl of control or experimental IgG solution was injected through a 30-gauge needle into the anterior corneal stroma, producing a small central bleb, ~3 mm in diameter. The corneal injections were coded, and performed by a single surgeon (Dr. Bahn) using an operating microscope. Each rabbit received the BP IgG injection in one eye and a corresponding control IgG injection in the other eye.

Animal evaluation. Animals were examined daily after injection by means of the slit lamp. Examinations were performed by a single experienced observer (Dr. Bahn).

Immunofluorescent (IF) technique. Direct and indirect IF techniques were performed by following standard methods (1–3). Complement fixation properties of IgG were also assayed by indirect IF (2) using complement-sufficient human serum. Fresh cornea from killed animals, human skin, and rat tongue were used as tissue substrates. Fluorescein isothiocyanate-conjugated goat antihuman IgG, (fluorescein/protein ratio: 3.39 $\mu\text{g}/\text{mg}$, total protein: 20 mg/ml), and fluorescein isothiocyanate-conjugated goat antirabbit C3 (fluorescein/protein ratio: 2.30 $\mu\text{g}/\text{mg}$, total protein: 29.0 mg/ml) were obtained commercially (N. L. Cappel Laboratories, Inc., Cochranville, Pa.).

Additional studies. To determine if the corneal inflammatory response induced by BP IgG was dose dependent, dilutions of the BP IgG fraction from patient 1 were made. Doses tested were (a) 1.9 mg, (b) 1.65 mg, (c) 0.5 mg, (d) 0.05 mg, with each injected in 50- μl volume. Each dose was tested in three rabbits, with corresponding doses of control IgG.

To determine if the immunoglobulin fractions would produce inflammation when injected intradermally, three rabbits received intracorneal injections of BP IgG in one eye and contralateral control IgG injections. These rabbits received simultaneous injections of 100 μl of the BP IgG fraction intradermally into the ear skin.

RESULTS

Clinical evaluation. Immediately following injection, control and experimental eyes appeared identical. Inadvertent penetration of the anterior chamber occurred in six eyes and produced no differences when compared with uncomplicated injections. 48 h after injection, control corneas appeared unchanged except for slight scarring along the needle tract (Fig. 1b). No clinically detectable inflammation occurred in any of 32 corneas injected with control IgG prepared from Cohn Fraction II, or from additional control IgG fractions prepared from serum (IgG concentration 34 mg/ml, 6 injections). 28 of 32 corneas injected with BP IgG fractions showed an inflammatory reaction (Table I). The intensity of the inflammation could be characterized as minimal, moderate, or severe. Minimal reactions consisted of epithelial thickening and anterior stromal edema persisting from 24 to 72 h post injection (7 of 28 positive reactions). Moderate inflammatory responses were characterized by intense epithelial and anterior stromal edema, with numerous microscopic lucent areas at the epithelial-stromal interface, (11, 28). Severe reactions were characterized by clinically obvious blister formation, with separation of the epithelium from the stroma (10, 28). These corneas also developed a circular opaque ring at the margin of the injection that had the appearance of a “Wessely ring” (Fig. 1c) (7), and iritis with a ciliary flush and aqueous cell and flare.

Severe reactions occurred only with BP IgG fractions from patients 1, 2, and 3. Injections that failed to produce detectable inflammation were prepared from patients 4 and 5. The intensity of inflammation correlated with the *in vitro* complement fixation titers in these fractions (Table I).

The inflammatory response of injected corneas was dose dependent. Injection of 1.9 mg of BP IgG from patient 1 produced severe inflammation, 1.65 mg produced moderate inflammation, 0.5 mg produced only

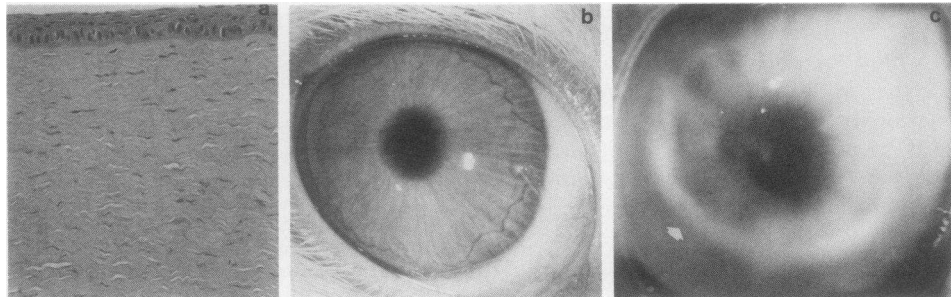


FIGURE 1 (a) Histological section of rabbit cornea 48 h after injection with control human IgG (50 μl , 1.8 mg). No significant inflammation is seen (hematoxylin and eosin, $\times 160$). (b) Rabbit cornea 48 h after injection with control human IgG. (c) Rabbit cornea 48 h after injection with BP IgG fraction from patient 1 (50 μl , 1.9 mg). Cornea shows a marked inflammatory reaction. Arrow demonstrates a white band resembling a “Wessely ring”.

TABLE I
Characteristics of IgG Fractions

Patients	IgG concentration	BP antibody titer	Complement fixation titer	Induced-corneal inflammation
	<i>mg/ml</i>			
1	38	1:400	1:100	a† 14/14§ c 3/3
2	20	1:3,200	1:200	b 4/4
3	28	1:1,600	1:200	a 2/2
4	34	1:3,200	*	b 1/2
5	41	1:400	*	b 0/3
6	21	1:40	1:100	a 1/1
7	19	—	—	a 3/3
				TOTAL: 28/32
Cohn fraction II (control IgG)	36	—	—	b 0/32

* Equivocal reading.

† Letters a, b, and c signify methods of preparation of IgG fractions: (a) crude fraction (40% ammonium sulfate precipitate); (b) DEAE-cellulose purified fraction; and (c) Ultrigel Ac-34 purified fraction.

§ Numerator denotes number of rabbits developing corneal lesions; denominator denotes total number of rabbits receiving intracorneal injections with each fraction.

minimal inflammation, and 0.05 mg produced no detectable inflammation.

Histological studies. The inflammatory changes in the BP IgG-injected corneas consisted of engorgement of the limbal vessels with eosinophils and neutrophils. Polymorphonuclear leukocytes infiltrated the stroma in the area injected, and eosinophils and neutrophils clustered at the epithelial-stromal interface (Figs. 2a and 2b). Some corneas showed areas of subepithelial separation with inflammatory cells clustering to the epithelium and forming the roof of a blister cavity (Figs. 2c and 2d). Control corneas injected with normal human IgG showed only a minimal accumulation of inflammatory cells in the area of the limbus and no significant stromal infiltration (Fig. 1a).

Immunofluorescence studies. Direct IF of BP-injected corneas 24 h postinjection showed linear deposition of IgG and C3 along the epithelial stromal junction (Fig. 2e). This was not seen in control IgG-injected corneas.

Additional studies. Of the three rabbits that received simultaneous intradermal and intracorneal injections, all three developed characteristic and intense corneal inflammatory changes. None of these rabbits developed any clinically detectable inflammation in the area of the ear skin injected, there was no IgG or C3 deposition at the BMZ, and no significant inflammation histologically. Both BP and control IgG fractions were found to be free of detectable protease activity.

DISCUSSION

The injection of BP IgG-class autoantibodies produced an inflammatory reaction in the cornea localizing at the epithelial-stromal junction. IgG and C3 were bound along the BMZ, and there was attachment of polymorphonuclear cells at the BMZ, with subepithelial blister formation. Control IgG fractions injected in a similar volume and dose did not produce any detectable inflammation clinically or histologically, and did not show IgG or C3 binding at the BMZ.

We found that the intensity of inflammatory changes induced by BP IgG fractions frequently correlated with the in vitro complement fixation titers. Those IgG fractions which had high in vitro complement fixation titers gave reproducibly intense inflammatory responses. Conversely, the only BP IgG fractions that failed to produce inflammatory lesions after injection showed equivocal or weakly positive complement fixation titers. There was a notable exception to this generality: the BP IgG fraction from patient 7. This fraction had undetectable BP antibody and complement fixation titers, yet gave unequivocally positive inflammatory changes in vivo. It is known that BP antibody titers in the sera of patients with BP, as shown by in vitro IF techniques, do not correlate well with clinical disease activity (2). It seems that current techniques for demonstrating the presence of the pathogenic antibodies may be inaccurate. A better detection system for circulating pathogenic BP antibodies must be developed.

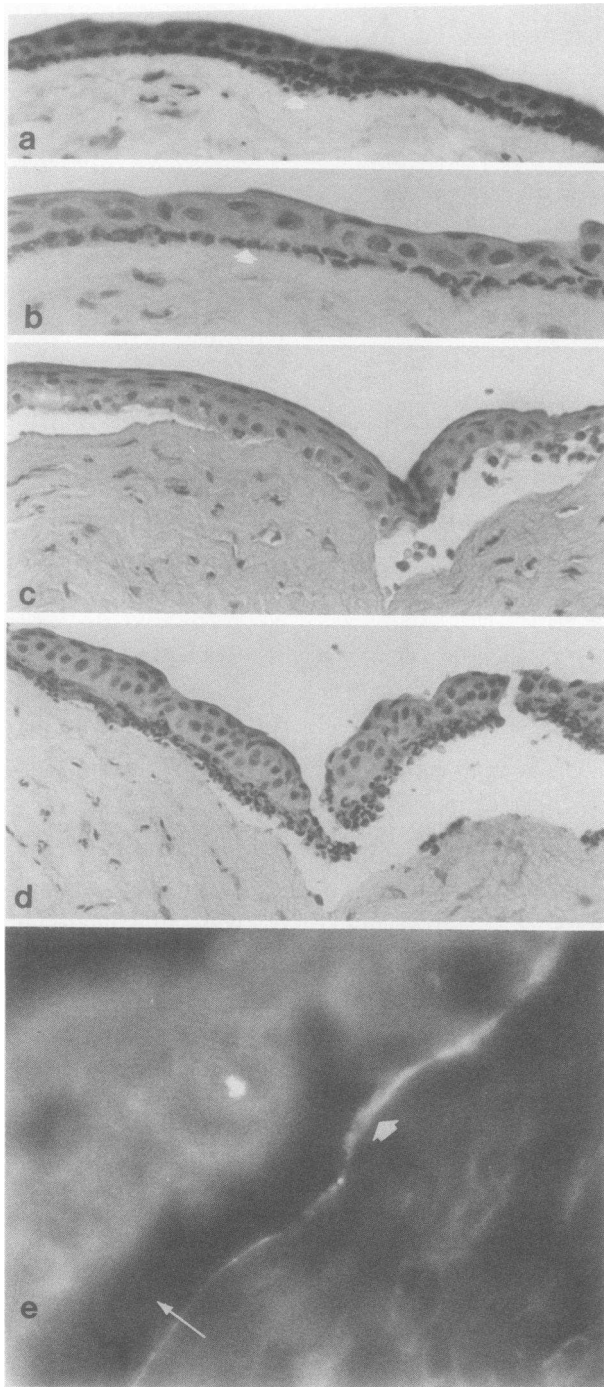


FIGURE 2 (a-d) Rabbit cornea 48 h after injection with BP IgG fraction from patient 1 (50 μ l, 1.9 mg). Arrow shows clustering of polymorphonuclear cells at the epithelial-stromal interface (a) and (b). In other areas there is subepithelial blister formation with inflammatory cells clustering along the epithelium and spilling into the blister cavity (c) and (d). (hematoxylin and eosin) (a) \times 250, (b) \times 400, (c) and (d) \times 200. (e) Rabbit cornea 24 h after injection with BP IgG. Direct immunofluorescence with fluorescein

BP antibodies produce inflammatory changes in the cornea, yet when injected into the ear skin of the same rabbits, produce no inflammation. Our studies have shown that high local concentrations of passively transferred human antibodies are required to produce lesions (19–41 mg/ml of injected IgG). By using dilutions of a single BP IgG fraction, we have also determined that the intensity of these inflammatory changes is directly related to the concentration of injected immunoglobulin. The cornea has no vascular supply or lymphatics, and injected immunoglobulins diffuse very slowly out of the stroma, as shown by Allansmith et al. (8). This presumably allows for maximal binding at the BMZ. The skin with its generous vascular and lymphatic supply, may not allow such binding to occur readily. Studies to address this possibility are in progress.

In the disease state, BP, lesions develop on skin and mucous membranes, including conjunctival epithelium, yet lesions usually are not observed in the corneal epithelium. We speculate that this is due to the relative immunological isolation of the cornea (9). Access of circulating antibodies to the corneal epithelium under normal circumstances is limited to (a) diffusion from vessels of the limbal circulation, (b) diffusion from the aqueous humor through the corneal endothelium and stroma, and (c) penetration through the tear film. IgG concentration in the aqueous humour of the humans ranges from 5 to 22 mg/100 ml, \sim 100 times lower than in serum (10). The major immunoglobulin of the tear film is IgA, not IgG, and penetration of immunoglobulin through an intact tear film is questionable. The precise amount of IgG that diffuses into the cornea from the limbal circulation is not known. It is conceivable, therefore, that the relative isolation of the corneal epithelium from circulating BP antibodies is responsible for the absence of clinically detectable corneal disease in patients with BP. It is also possible that corneal involvement in BP is subtle and easily overlooked clinically, as postulated by Foster (11).

In summary, the intracorneal injections of pemphigoid IgG reproduce the clinical, histological, and immunological changes that are seen in the cutaneous lesions of BP. On the basis of this information, as well as compelling in vitro evidence, it seems reasonable now to assume that these autoantibodies are pathogenic in the human disease, bullous pemphigoid.

ACKNOWLEDGMENTS

We gratefully acknowledge C. L. Martonyi for performing the ophthalmic photography.

This work was supported in part by the U. S. Public Health Service, National Institutes of Health grants RO 1-AM 21 608

isothiocyanate conjugated goat antihuman IgG demonstrates in vivo bound IgG at the BMZ (large arrow). A blister cavity is also seen (small arrow). (\times 400).

and 5T32 AM 07197, Veterans Administration Merit Review grant, the Veterans Administration Research Career Development Program (Dr. Anhalt), and the Heed Ophthalmic Foundation (Dr. Bahn).

REFERENCES

1. Jordon, R. E., E. H. Beutner, E. Witebski, G. Blumenthal, W. L. Hale, and W. F. Lever. 1967. Basement-zone antibodies in bullous pemphigoid. *JAMA (J. Am. Med. Assoc.)* **200**: 751-746.
2. Jordon, R. E. 1976. Complement activation in pemphigus and bullous pemphigoid. *J. Invest. Dermatol.* **67**: 366-371.
3. Diaz, L. A., H. J. Weiss, and N. J. Calvanico. 1979. Phylogenetic studies with pemphigus and pemphigoid antibodies. *Acta Dermato-Venereol.* **59**: 537-540.
4. Gammon, W. R., D. M. Lewis, J. R. Carlo, W. M. Sams, and C. E. Wheeler. 1980. Pemphigoid antibody mediated attachment of peripheral blood leukocytes at the dermal-epidermal junction of human skin. *J. Invest. Dermatol.* **75**: 334-339.
5. Sams, W. H., and G. J. Gleich. 1971. Failure to transfer bullous pemphigoid with serum from patients. *Proc. Soc. Exp. Biol. Med.* **136**: 1027-1031.
6. Schert, G. W., and Y. Takenaka, 1955. A spectrophotometric determination of Trypsin and Chymotrypsin. *Biochim. Biophys. Acta* **16**: 570-575.
7. Wessely, K. 1925. Ueber Anaphylaktische Erscheinungen an der Hornhaut. *Munch. Med. Wochenschr.* **58**: 1713-1714.
8. Allansmith, M., A. De Ramus, and D. Maurice, 1979. The dynamics of IgG in the cornea. *Invest. Ophthalmol. Visual Sci.* **18**: 947-955.
9. Barker, C. F., and R. E. Billingham. 1977. Immunologically privileged sites. *Adv. Immunol.* **25**: 1-54.
10. Zirm, M. 1980. Proteins in aqueous humor. *Adv. Ophthalmol.* **40**: 100-172.
11. Foster, C. S., 1979. Ocular surface manifestations of neurological and systemic disease. *Int. Ophthalmol. Clin.* **19**: 207-242.