

Immunohistochemical changes in morphologically involved and uninvolved colonic mucosa of patients with idiopathic proctitis.

K M Das, ... , W F Erber, A Rubinstein

J Clin Invest. 1977;**59**(3):379-385. <https://doi.org/10.1172/JCI108650>.

Research Article

Alterations in secretory component, IgA, IgG, and IgM were studied by immunofluorescent techniques in mucosal biopsy specimens obtained at colonoscopy from inflamed and grossly uninvolved colonic mucosa from 12 patients with idiopathic proctitis. Parotid-salivary secretory component and IgA and serum immunoglobulins were also investigated. Decreased secretory IgA was observed in the epithelium of all grossly involved rectal mucosa and in 40% of proximal normal mucosa. Salivary secretory IgA was not diminished. These observations suggest that a local immune defect may be pathogenetically related to idiopathic proctitis.

Find the latest version:

<https://jci.me/108650/pdf>



Immunohistochemical Changes in Morphologically Involved and Uninvolved Colonic Mucosa of Patients with Idiopathic Proctitis

KIRON M. DAS, WILLIAM F. ERBER, and ARYE RUBINSTEIN

From the Division of Gastrointestinal and Liver Disease, Department of Medicine, Cell Biology, and Pediatrics, Albert Einstein College of Medicine, Bronx, New York 10461

ABSTRACT Alterations in secretory component, IgA, IgG, and IgM were studied by immunofluorescent techniques in mucosal biopsy specimens obtained at colonoscopy from inflamed and grossly uninvolved colonic mucosa from 12 patients with idiopathic proctitis. Parotid-salivary secretory component and IgA and serum immunoglobulins were also investigated. Decreased secretory IgA was observed in the epithelium of all grossly involved rectal mucosa and in 40% of proximal normal mucosa. Salivary secretory IgA was not diminished. These observations suggest that a local immune defect may be pathogenetically related to idiopathic proctitis.

INTRODUCTION

Systemic and local immunologic abnormalities have been described in ulcerative colitis and Crohn's disease (1-10); however, data regarding the local immunologic factors are conflicting. Immunologic abnormalities have also been reported in idiopathic proctitis (11), a localized form of inflammatory bowel disease (12). Although abnormalities in IgA in colonic mucosa occur (5-8), the status of colonic mucosal secretory IgA, which is the predominant local antibody (13, 14), has not been established in idiopathic proctitis. The present study examines secretory IgA in histologically involved as well as in uninvolved mucosa in an attempt to clarify the possible pathogenetic role of this system in idiopathic proctitis

which is considered to be a forerunner of ulcerative colitis (12, 15, 16). For comparison between colonic and extraintestinal S-IgA system, salivary S-IgA in the same group of patients was also investigated.

METHODS

Patients. The untreated patients with idiopathic proctitis (aged 20-55 yr, mean 32 yr; 11 female, 1 male) verified by sigmoidoscopy had a normal mucosa on barium enema examinations. All the patients had mild to moderate disease on the basis of number of bowel movements, amount of blood and mucus in the stool, and sigmoidoscopic appearance. The duration of the disease ranged from 3 wk to several mo before the present episode. After initial investigations, all patients were colonoscoped while they were symptomatic to determine the extent of the lesion and to obtain multiple mucosal biopsy specimens. Endoscopic mucosal disease was localized to the rectum (up to 15-20 cm from the anus) (12, 15). In no case did the disease extend endoscopically beyond the rectum. All patients were subsequently treated with hydrocortisone enemas (Cortenema, Rowell Laboratories, Inc., Baudette, Minn.) with or without salicylazosulfapyridine (SAS-500, Rowell Laboratories, Inc.; Azulfidine, Pharmacia Fine Chemicals, Inc., Piscataway, N. J.). Nine additional patients in whom colonoscopy was required for a workup of diarrheal problems unrelated to idiopathic proctitis or any other inflammatory bowel disease served as controls. In addition, biopsy specimens were obtained at colonoscopy in one patient with clindamycin-associated colitis and another patient with gonococcal proctitis. Informed consent was obtained from all patients before colonoscopy.

Biopsy specimens. Colonoscopic mucosal biopsies were obtained from rectum, sigmoid, or descending colon and transverse colon in each patient and included macroscopically involved and uninvolved mucosa. Similar biopsy specimens were obtained from the control subjects. Specimens for immunofluorescent studies were immediately placed in isopentane, then in liquid nitrogen and stored at -70°C for a maximum period of 6-8 wk. The biopsy specimens were mounted on a block, embedded in OCT compound (Ames Co., Div. of Miles Lab., Inc., Elkhart, Ind.) and serially sectioned at $4\ \mu\text{m}$ with a cryostat at -20°C . Parallel specimens were fixed in formalin for light microscopy.

A preliminary report of this material was presented, in part, at the Meeting of the Eastern Gut Club, New York, in March 1976 and in abstract form in 1975. *Gastroenterology*, 68: 880. (Abstr.)

Dr. Das is the recipient of a Clinical Investigator Award from the National Institutes of Health, 1K08 AM00237.

Received for publication 16 July 1976 and in revised form 16 November 1976.

Collection of parotid saliva. Parotid saliva was collected for 30 min from 7 of the 12 patients with idiopathic proctitis and from 10 control subjects by utilizing special cups to fit duct openings while stimulating secretion with citric acid. Saliva specimens were dialyzed and concentrated 25-fold by freeze drying. Presence of secretory IgA, free and bound secretory component, was verified by double diffusion in agar gel with anti-IgA and anti-free and anti-bound secretory component sera with control salivas and colostrum IgA as standards (17). Quantitative determinations of salivary secretory IgA was determined by radial immunodiffusion and compared to 10 controls (IgA: range 0.56–2.2 mg/100 ml; mean value 1.4 mg/100 ml). Electrophoretic mobility of the patient's salivary proteins was determined by microzone electrophoresis (Beckman Instruments, Inc., Fullerton, Calif.) on cellulose acetate membrane (18). Salivary proteins of the patients were compared with three normal control saliva specimens, secretory IgA, secretory component, and lactoferrin purified by us from human colostrum (19) and myeloma IgA. Although this is an insensitive technique to quantitate salivary proteins, it was found adequate to compare their electrophoretic mobility to normal controls.

Immunofluorescent methods

Antisera. Rabbit antihuman IgA, IgG, IgM, β_2 C, and secretory component unconjugated and (or) conjugated with fluorescein isothiocyanate were obtained from Behring Diagnostics, American Hoechst Corp., Somerville, N. J. Rhodamine-conjugated IgG goat antirabbit gamma globulin was obtained from Cappel Laboratory, Downingtown, Pa. Monospecificity of antisera was screened by immunoelectrophoresis before use. Two types of antisera to secretory component were used, one that reacted only with free secretory component (Behring Diagnostics) and one that reacted in addition with colostrum IgA. Each batch of antiserum was tested in double diffusion in agar against SC and S-IgA isolated by us from human colostrum (19). The purity of SC and S-IgA purified by us was compared to reference samples (kindly supplied by Doctors D. Goodenberger and W. Strober, National Cancer Institute, National Institutes of Health, Bethesda, Md.), by using SDS acrylamide gels, double diffusion in agar, and immunoelectrophoresis setups. An antifree SC antiserum was defined as that reacting to free SC and not to S-IgA. The antibody SC reacted with both S-IgA and free SC. Anti-IgA was tested in immunoelectrophoresis and double diffusion in agar not to cross react to SC or other salivary protein except for IgA.

Direct technique. Cryostat sections were fixed in 95% ethanol, washed with phosphate-buffered saline (0.1 M, pH 7.2) for 5 min, and stained with fluorescein-conjugated antisera to IgG, IgM, IgA, and β_2 C. To remove any aggregated immunoglobulin which may be present in the antisera and that can react with Fc receptors every fluorescent antiserum was ultracentrifuged immediately before its use. After 1 h of incubation in a moist chamber, slides were rinsed with buffer and washed twice in buffer for 10 min. Sections were dried and sealed using elvanol and cover glass. Specificity of the staining of each conjugate in the direct technique was confirmed by incubating parallel sections first with unconjugated antisera to IgA, IgG, IgM, washing in buffered saline and then adding the corresponding conjugated anti-immunoglobulin for an additional 20 min.

Indirect technique. Sections were processed as in the direct technique and were incubated with unconjugated antisera to human free secretory component followed by a wash

in phosphate-buffered saline. Sections were then stained with rhodamine-conjugated IgG goat antirabbit gamma globulin and incubated for 1 h in a moist chamber. Slides were rinsed, washed with buffer, and mounted as above.

Unstained sections mounted in buffered glycerin were used to estimate autofluorescence. A parallel section was incubated with conjugated antisera as control for non-specific fluorescence. The specificity of the antifree SC was tested by preincubation and precipitation of the antifree SC with free SC followed by the use of the supernate of the antiserum for immunofluorescent staining. No immunofluorescence for SC was obtained by this experimental set up. Serial sections were also stained with hematoxylin and eosin.

Fluorescent microscopy. A Zeiss microscope (Carl Zeiss, Inc., New York) equipped with vertical illuminator HBO 200 W Mercury lamp, fluorescein isothiocyanate and KP-600 exciter filters, FL-500 and 580 reflectors, 53- and 44-barrier filters were used for fluorescein isothiocyanate and rhodamine stainings, respectively. Photographs were taken with Kodak Ektachrome film ASA 160 (Eastman Kodak Co., Rochester, N.Y.).

Sections were examined with 400 × 900 × magnification. 30 sections from each biopsy specimen were stained with different antisera. Immunofluorescence of mucosal glandular epithelia was quantitated by utilizing a 0 to +++ scale: 0, no fluorescence; +, minimal fluorescence detected only after close observation; ++, clear-cut fluorescent pattern of epithelial subcellular structures; +++, diffuse band of fluorescence of epithelia. The scale of 0 or + was considered as diminished and ++ to +++ was considered to be normal. The slides were examined double blind by three of us and individually scored. The superficial colonic mucosal biopsy specimens used did not enable us to quantitate the immunocytes in the lamina propria.

RESULTS

Light microscopy. Biopsy specimens from sites of obvious lesions seen by colonoscopy showed at least three or more of the following histologic abnormalities: increased inflammatory cells (including neutrophils) in the lamina propria, glandular necrosis, ulcerations, crypt abscesses, depletion of goblet cells, and mucosal atrophy. Mucosal atrophy was judged by the length of crypts and the density of glands as compared with that seen in normal controls. Biopsy specimens from proximal colonic mucosa of normal appearance were histologically normal in 7 out of 12 patients. In the remaining five, the mucosa of the sigmoid colon revealed atrophy, depletion of goblet cells, excess chronic inflammatory cells, and, in one patient, crypt abscesses. Two of the five patients had these morphological abnormalities in the biopsy specimens taken from the transverse colon. The detailed morphology is being reported elsewhere (20).

Fluorescent microscopy. In all sections from the nine control subjects, secretory component appeared as a dense band at the apices (+++) and in small quantity (++) at the basal membrane and intercellular areas of glandular epithelia (Figs. 1A and 2A). Secretory component was not seen in the lamina propria.

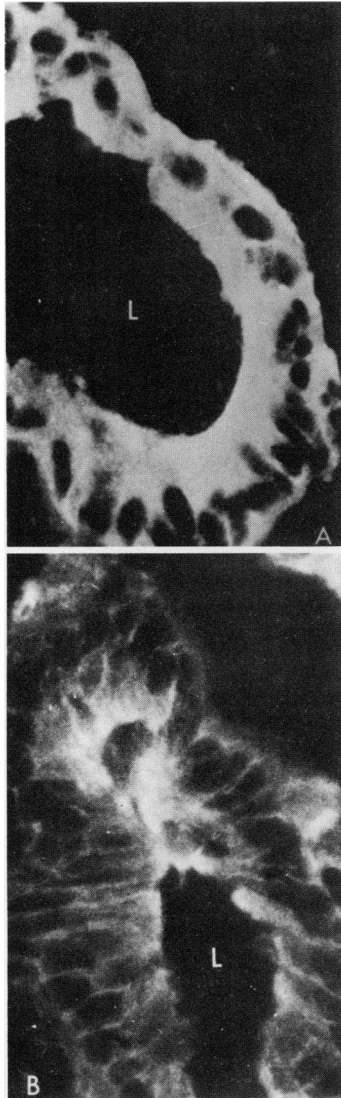


FIGURE 1 Immunohistochemical localization of secretory component (SC) in glandular epithelium of comparable fields from sections of the alcohol-fixed biopsy specimens taken from the mucosa of the transverse colon: (A) from a control subject. There is intense staining for SC in the luminal side (L) of the glandular columnar epithelium. Note that SC is present also along the cell membranes including the basement membrane areas (B) from a patient with idiopathic proctitis. Note the marked diminution of staining of SC at the luminal aspect (L) of the glandular columnar epithelium and the staining is practically nil along the cell membranes including the basal areas ($\times 400$).

The distribution of IgA was similar to that of secretory component and was markedly dense (+++) (Fig. 3A). Plasma cells in the lamina propria contained primarily IgA. No epithelial fluorescence was seen on staining for IgG and β_1C . There was minimal epithelial fluorescence when staining for IgM (Fig. 4).

The patients with clindamycin-associated colitis and gonococcal proctitis showed immunohistochemical patterns similar to those of control subjects.

The immunohistochemical findings at various levels of colon in the 12 patients with idiopathic proctitis are shown in Table I. All specimens obtained from grossly involved areas showed a significant decrease of secretory component (0 or +). Apical epithelial fluorescence of secretory component appeared as a very irregular line compared with the homogenous band of staining observed in control specimens. 6 of the 12 patients showed decreased (+) epithelial secretory component in grossly uninvolved areas of the transverse colon (Figs. 1B and 2B). Two of these

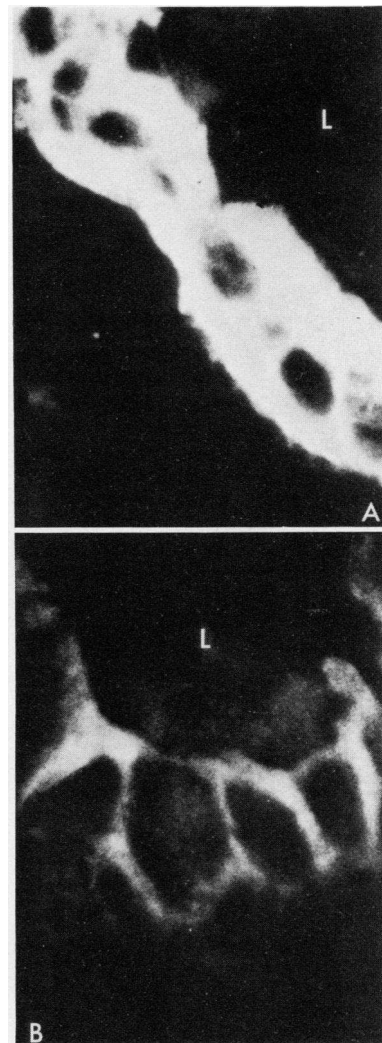


FIGURE 2 Immunohistochemical localization of SC. Higher magnification of the same specimens as in Fig. 1: (A) from a control subject and (B) from a patient with idiopathic proctitis ($\times 900$). L indicates the lumen of the gland.

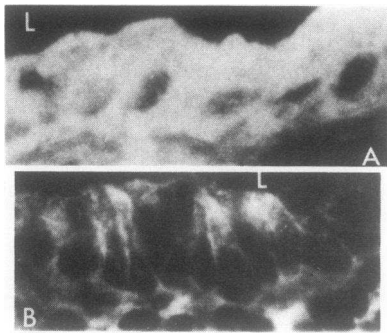


FIGURE 3 Immunohistochemical localization of IgA in the glandular epithelium in comparable parts of the biopsy specimens taken from the mucosa of the transverse colon: (A) from a control subject, the distribution and intensity of staining is more or less the same as for secretory component; (B) from a patient with idiopathic proctitis, note the marked diminution of staining for IgA both at the luminal aspect (L) and along the cell membranes ($\times 400$).

six patients had histological abnormalities in these same grossly normal areas.

When stained with anti-IgA, sections from areas showing gross and histological proctitis revealed significant diminution of epithelial fluorescence (0 to +) in 8 of the 12 patients (Table I). Epithelial fluorescence for IgA in the proximal uninvolved colonic mucosa was also significantly diminished (0 to +) in 5 of the 12 patients (Fig. 3B and Table I).

Anti-IgM sera did not give any staining above + in the biopsy specimens of nine patients or in any of

the control subjects. In three patients, the IgM staining was, however, increased. IgG staining in grossly involved mucosal specimens appeared as spicules in the lamina propria, and distinct localization within plasma cells was lacking. In no case was IgG found within mucosal epithelial cells. Three of six patients studied demonstrated faint epithelial staining for β_1C which was absent in controls.

Serum and salivary immunoglobulins and secretory component (Table II). Serum IgA deviated from the normal controls only in three patients: 350, 380, and 75 mg/100 ml (normal range = 77–257 mg/100 ml). Serum IgG and IgM were essentially normal.

Salivary IgA was slightly elevated in two patients compared to adult controls. Patient's parotid salivary total secretory component gave precipitation lines similar to normals by the double immunodiffusion test. Saliva was serially diluted to the end point where no precipitation line could be detected and then compared to the controls. The mobility on microzone electrophoresis of patients' salivary IgA and secretory component was comparable to that of control saliva, purified colostral IgA, and purified colostral secretory component.

DISCUSSION

The pathogenesis of inflammatory bowel disease is still enigmatic. Several immunologic abnormalities have been described during the course of inflammatory bowel disease, none of which could be clearly de-

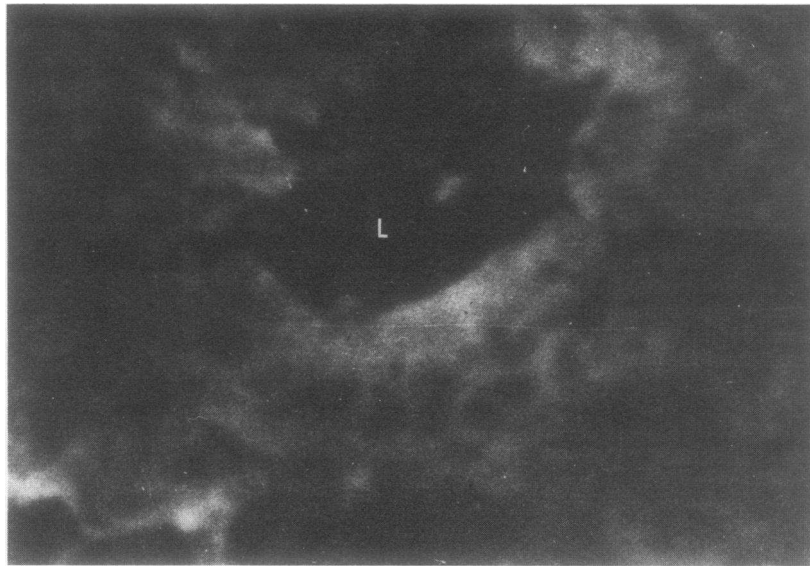


FIGURE 4 Immunohistochemical localization of IgM in the glandular epithelium of colonic biopsy specimen from a control subject. Minimal staining was noticed mainly along the luminal aspect (L) of the epithelial cells.

TABLE I
Immunohistochemical Changes at Different Levels of Colonic Mucosal Epithelium from Patients with Idiopathic Proctitis

	SC	IgA	IgM	β_2 C
Number of patients	12	12	12	6
Colonic level of biopsy from anal verge				
<20 cm (rectum)*	↓ 12	↓ 8	↑ 3	↑ 3
>20 < 40 cm (sigmoid colon)*	↓ 8	↓ 6	↑ 3	↑ 2
>40 cm (descending and transverse colon)*	↓ 6	↓ 5	N	N

* The figures indicate the number of the patients with abnormalities as indicated by arrows. The findings in the rest of the patients were within normal limits. ↑, increased; ↓, decreased; N, normal in all.

ined as primary. In this study, we attempted to define the role of the secretory IgA system in idiopathic proctitis.

Local mucosal immune abnormalities are frequently associated with chronic inflammation and autoimmune disease (13, 14, 21, 22). Such abnormalities especially those of the secretory IgA system may occur secondarily to acute or chronic infections (23). Previous reports regarding the colonic IgA system in inflammatory bowel disease were conflicting (3, 5-8, 10); in ulcerative colitis the density of IgA positive lymphocytes is decreased in the rectal mucosa (3). In some instances where IgA immunocytes were normal or even increased (5-8), a paradoxical depletion of glandular IgA occurred (7). Such a depletion of epithelial secretory IgA was reported to be restricted only to histologically involved areas obtained at colectomy from patients with Crohn's disease (10). These observed variations in distribution of colonic IgA raise the question as to whether they are primary or secondary to epithelial destruction. We approached this question by utilizing histologically normal and abnormal colonic mucosa obtained during colonoscopy from the same patient. Since previous studies have revealed histological abnormalities in proximal macroscopically normal colon (20), "uninvolved areas" were strictly defined as those which were not only macroscopically but also histologically normal. Any abnormality in the secretory IgA system in uninvolved areas could be more likely a primary disorder. To further minimize artifactual immunofluorescent abnormalities present in advanced disease, only untreated patients in the initial phase of idiopathic proctitis, an inflammatory disease of predominantly restricted extension, were included. The study showed that in patients with idiopathic proctitis, secretory IgA and free secretory

component were markedly diminished, not only in areas of histologic involvement but also in histologically uninvolved areas in about one-third of the patients.

The meaning of this local S-IgA deficiency is speculative at this stage. A certain concentration of free secretory component is important in maintaining the carrier transport milieu for IgA (24). Its lack (i.e., a local immune deficiency) could be implicated as a causative factor and may precede proximal spread of the disease leading to generalized colitis in the patients with idiopathic proctitis. This finding was also compared with other extraintestinal sites of the secretory IgA system and with serum IgA levels. Serum and salivary IgA were, however, not significantly diminished in any of the studied patients (Table II). Such a dissociation between the abnormal colonic IgA and the normal serum and salivary IgA system is unusual. A selective global secretory piece deficiency (22) as well as absent parotid and normal gut IgA (25) deficient serum IgA with normal gut IgA (26) have been reported. In our patients, however, the reverse situation was observed, namely a depletion of colonic secretory IgA with normal salivary and serum IgA. This cannot be explained on the basis of the phylogenetic and ontogenetic development of the IgA system and thus raises the alternative possibility that a local exogenous toxic process may have depleted the epithelial secretory IgA even before any histologic changes were noted. In support of this concept are recent observations that granulomas can be elicited in footpads of mice by injection of homogenates from diseased bowel tissue with Crohn's disease as well as from histologically normal resection margins (27). Moreover, in Crohn's disease, increased glucosamine synthetase activity was noticed in apparently normal rectal biopsy specimens (28). The latter data indicate

TABLE II
Salivary and Serum IgA in Patients with Idiopathic Proctitis

	Parotid saliva IgA	Serum IgA
	mg/100 ml	mg/100 ml
Idiopathic proctitis (n = 7)	1.2	350
	1.3	75
	0.09	380
	1.8	158
	1.3	158
	3.2	205
	2.02	165
Normal range (n = 10)	0.56-2.2	77-257

that a "toxic agent" or a pathological process may be present in tissues long before morphological abnormalities are detectable.

Abnormal systemic and local cellular immunity may also contribute to failure of the secretory IgA system. Preliminary studies in our patients failed to reveal a major deficiency in systemic cellular immunity (unpublished data). Secretory component may be present in two distinct immunochemical and physicochemical forms in rats (29). Our initial studies by microzone electrophoresis could not, however, detect an abnormal electrophoretic mobility of secretory IgA or secretory piece from patients' saliva. Further analysis of secretory IgA isolated from mucosal secretions is necessary to examine the role of breakdown of host defenses in the pathogenesis of inflammatory bowel disease. Abnormalities in glycosylation of secretory component or in polymerization, assembly, or binding of IgA to secretory component may result in a biologically deficient secretory IgA which escapes detection by the immunofluorescence techniques employed.

ACKNOWLEDGMENTS

The authors wish to acknowledge the invaluable help that Boyce Bennet, Professor of Pathology, and Rachel Morecki, Associate Professor of Pathology, Albert Einstein College of Medicine, gave in critical interpretation of immunohistochemical and morphological findings. We are also grateful to Irwin M. Arias, Professor of Medicine, for helpful criticisms in the preparation of this manuscript.

This investigation was supported by grants A1 10702 and AM 05384 from the National Institutes of Health and by a grant from the Rowell Laboratories, Inc.

REFERENCES

1. Crabbé, P. A., and J. F. Heremans. 1966. The distribution of immunoglobulin-containing cells along the human gastrointestinal tract. *Gastroenterology*. **51**: 305-316.
2. Pearlmann, P., S. Hammarström, R. Lagercrantz, and D. Campbell. 1967. Autoantibodies to colon in rats and human ulcerative colitis: cross reactivity with *Escherichia coli* 0:14 antigen. *Proc. Soc. Exp. Biol. Med.* **125**: 975-980.
3. Gelzayd, E. A., S. C. Kraft, F. W. Fitch, and J. B. Kirsner. 1968. Distribution of immunoglobulins in human rectal mucosa. II. Ulcerative colitis and abnormal mucosal control subjects. *Gastroenterology*. **54**: 341-347.
4. Bendixen, G. 1969. Cellular hypersensitivity to components of intestinal mucosa in ulcerative colitis and Crohn's disease. *Gut*. **10**: 631-636.
5. Kraft, S. C., and J. B. Kirsner. 1971. Immunological apparatus of the gut and inflammatory bowel disease. *Gastroenterology* **60**: 922-951.
6. Söltoft, J., V. Binder, and E. Gudmand-Höyer. 1973. Intestinal immunoglobulins in ulcerative colitis. *Scand. J. Gastroenterol.* **8**: 293-300.

7. Brandtzaeg, P., K. Baklien, O. Fausa, and P. S. Hoel. 1974. Immunohistochemical characterization of local immunoglobulin formation in ulcerative colitis. *Gastroenterology*. **66**: 1123-1136.
8. Skinner, J. M., and R. Whitehead. 1974. The plasma cells in inflammatory disease of the colon: A quantitative study. *J. Clin. Pathol. (Lond.)*. **27**: 643-646.
9. Strickland, R. G., S. Korsmeyer, R. D. Soltis, I. D. Wilson, and R. C. Williams, Jr. 1974. Peripheral blood T and B cells in chronic inflammatory bowel disease. *Gastroenterology*. **67**: 569-577.
10. Green, F. H. Y., and H. Fox. 1975. The distribution of mucosal antibodies in the bowel of patients with Crohn's disease. *Gut*. **16**: 125-131.
11. Das, K. M., W. Erber, and A. Rubinstein. 1975. Immunological studies in patients with idiopathic proctitis: Changes in systemic immune reactions, secretory component and immunoglobulins in histologically involved and uninvolved colonic mucosa. *Gastroenterology*. **68**: 880. (Abstr).
12. Lennard-Jones, J. E., G. W. Cooper, A. C. Newell, C. W. E. Wilson, and F. A. Jones. 1962. Observations on idiopathic proctitis. *Gut*. **3**: 201-206.
13. Williams, R. C., and R. J. Gibbons. 1972. Inhibition of bacterial adherence by secretory immunoglobulin A: A mechanism of antigen disposal. *Science (Wash. D.C.)*. **177**: 697-699.
14. Fubara, E. S., and R. Freter. 1973. Protection against enteric bacterial infection by secretory IgA antibodies. *J. Immunol.* **111**: 395-403.
15. Sparberg, M., J. Fennessy, and J. B. Kirsner. 1966. Ulcerative proctitis and mild ulcerative colitis: A study of 220 patients. *Medicine (Baltimore)*. **45**: 391-412.
16. Schlachter, H., and J. B. Kirsner. 1975. Definitions of inflammatory bowel disease of unknown etiology. *Gastroenterology*. **68**: 591-600.
17. Mancini, G., A. O. Carbonara, and J. F. Heremans. 1965. Immunochemical quantitation of antigens by single radial immunodiffusion. *Immunochemistry*. **2**: 235-254.
18. Grunbaum, B. W., J. Zec, and E. L. Durrum. 1963. Application of an improved microelectrophoresis technique and immunoelectrophoresis of serum proteins on cellulose acetate. *Microchem. J.* **7**: 41-53.
19. Brandtzaeg, P. 1974. Human secretory component. I. Purification of free secretory component from colostrum. *Scand. J. Immunol.* **3**: 579-588.
20. Das, K. M., R. Morecki, P. Nair, and J. M. Berkowitz. 1976. Idiopathic proctitis: I. The morphology of proximal colonic mucosa and its clinical significance. *Am. J. Dig. Dis.* In press.
21. Walker, W. A., K. J. Isselbacher, and K. J. Bloch. 1972. Intestinal uptake of macromolecules: Effect of oral immunization. *Science (Wash. D. C.)*. **177**: 608-610.
22. Strober, W., R. Krakauer, H. L. Klaeveman, H. Y. Reynolds, and D. L. Nelson. 1976. Secretory component deficiency. A disorder of the IgA immune system. *N. Engl. J. Med.* **294**: 351-356.
23. Bürgi, H. 1971. Endogenous defense against infectious disease in chronic bronchitis. *Respiration*. **28**: 480-484.
24. Brandtzaeg, P. 1974. Mucosal and glandular distribution of immunoglobulin components: Differential localization of free and bound SC in secretory epithelial cells. *J. Immunol.* **112**: 1553-1559.
25. Rubinstein, A., J. Rádl, H. Cottier, E. Rossi, and E. Gugler. 1973. Unusual combined immunodeficiency syn-

- drome exhibiting kappa-IGD paraproteinemia, residual gut-immunity and graft-versus-host reaction after plasma infusion. *Acta Paediatr. Scand.* **62**: 365-372.
26. Broom, B. C., E. G. de la Concha, A. D. B. Webster, G. Loewi, and G. L. Asherson. 1975. Dichotomy between immunoglobulin synthesis by cells in gut and blood of patients with hypogammaglobulinaemia. *Lancet.* **II**: 253-256.
27. Taub, R. N., D. Sachar, H. Janowitz, and L. E. Siltzbach. 1976. Induction of granulomas in mice by inoculation of tissue homogenates from patients with inflammatory bowel disease and sarcoidosis. *Ann. N. Y. Acad. Sci.* **278**: 560-564.
28. Goodman, M. J., J. M. Skinner, and S. C. Truelove. 1976. Abnormalities in the apparently normal bowel mucosa in Crohn's disease. *Lancet.* **I**: 275-278.
29. Cambier, J. C., and J. E. Butler. 1976. Two immunochemically and physiocochemically distinct secretory components from rat exocrine secretions. *J. Immunol.* **116**: 994-999.