

## Gamma G globulin subgroup composition of the glomerular deposits in human renal diseases

Edmund J. Lewis, ... , George J. Busch, Peter H. Schur

*J Clin Invest.* 1970;49(6):1103-1113. <https://doi.org/10.1172/JCI106326>.

### Research Article

36 renal biopsies from patients with nephritis were studied for glomerular localization of the heavy chain subgroups of immunoglobulin G (IgG or  $\gamma$ G). The deposition pattern of these subgroups was selective and did not reflect the normal serum concentration of these proteins.  $\gamma$ G2, which comprises 18% of normal serum  $\gamma$ G, was the predominant or unique subgroup deposited in five cases of lupus nephritis and four biopsies with other forms of nephritis associated with granular  $\gamma$ G deposits.  $\gamma$ G3, which normally makes up only 8% of the serum  $\gamma$ G, was the dominant subgroup seen in one biopsy of lobular glomerulonephritis. Patients with linear  $\gamma$ G deposits generally had a selective absence of  $\gamma$ G3 and often had large amounts of  $\gamma$ G4 (normally 3% of the serum  $\gamma$ G) deposited. The deposition of complement components C1q, C4, and C3 was variable. One biopsy had only  $\gamma$ G2 and no complement components in the deposits and had no neutrophile leukocyte infiltration. This latter observation correlates well with the poor ability of  $\gamma$ G2 to fix complement in vitro. Similarly, deposits containing large amounts of  $\gamma$ G4, which does not fix complement, also tended to have less inflammatory infiltrate than deposits devoid of this subgroup. The selective deposition of monotypic or restricted  $\gamma$ G subgroups on the glomerulus supports the likelihood that the  $\gamma$ G represents antibody. The nature of the subgroup involved [...]

Find the latest version:

<https://jci.me/106326/pdf>



# Gamma G Globulin Subgroup Composition of the Glomerular Deposits in Human Renal Diseases

EDMUND J. LEWIS, GEORGE J. BUSCH, and PETER H. SCHUR

*From the Departments of Medicine and Pathology, Harvard Medical School, and the Robert B. Brigham and Peter Bent Brigham Hospitals, Boston, Massachusetts 02120*

**ABSTRACT** 36 renal biopsies from patients with nephritis were studied for glomerular localization of the heavy chain subgroups of immunoglobulin G (IgG or  $\gamma$ G). The deposition pattern of these subgroups was selective and did not reflect the normal serum concentration of these proteins.  $\gamma$ G2, which comprises 18% of normal serum  $\gamma$ G, was the predominant or unique subgroup deposited in five cases of lupus nephritis and four biopsies with other forms of nephritis associated with granular  $\gamma$ G deposits.  $\gamma$ G3, which normally makes up only 8% of the serum  $\gamma$ G, was the dominant subgroup seen in one biopsy of lobular glomerulonephritis. Patients with linear  $\gamma$ G deposits generally had a selective absence of  $\gamma$ G3 and often had large amounts of  $\gamma$ G4 (normally 3% of the serum  $\gamma$ G) deposited. The deposition of complement components C1q, C4, and C3 was variable. One biopsy had only  $\gamma$ G2 and no complement components in the deposits and had no neutrophil leukocyte infiltration. This latter observation correlates well with the poor ability of  $\gamma$ G2 to fix complement *in vitro*. Similarly, deposits containing large amounts of  $\gamma$ G4, which does not fix complement, also tended to have less inflammatory infiltrate than deposits devoid of this subgroup. The selective deposition of monotypic or restricted  $\gamma$ G subgroups on the glomerulus supports the likelihood that the  $\gamma$ G represents antibody. The nature of the subgroup involved in the deposit may represent one variable in the determination of the inflammatory and morphological picture that evolves in human glomerulonephritis.

## INTRODUCTION

The pathogenesis of most types of glomerulonephritis in man is not fully understood. Recent information suggests

Dr. Lewis' present address is Thorndike Memorial Laboratory, Boston City Hospital, Boston, Mass. 02118.

*Received for publication 15 December 1969.*

that immune reactions lead to the deposition of antibody gamma globulin on the glomerular basement membrane (GBM) and play a central role in the development of the renal lesion. Either circulating soluble antigen-antibody complexes or specific antibody directed against a renal antigen may deposit on the glomerulus. The former mechanism is operative in experimental serum sickness (1) and similar deposits of immunoglobulins and complement components have been detected in certain human diseases (2). The observation that DNA can be present on the GBM in the nephritis of systemic lupus erythematosus and that gamma globulin eluted from these glomeruli has anti-DNA antibody activity is strong evidence that "immune complexes" are involved in the pathogenesis of lupus nephritis (3). The deposition of  $\gamma$ G in a granular or lumpy pattern along the GBM in poststreptococcal glomerulonephritis (4), luetic nephrosis (5), and other forms of acute, progressive, and chronic glomerulonephritis (2) suggests that circulating antigen-antibody complexes deposit in these disorders as well.

Specific antibody directed against glomerular basement membrane antigens has been demonstrated in the kidney in Goodpasture's syndrome and some cases of chronic glomerulonephritis (6). These antibodies are responsible for a second immunopathologic mechanism in the genesis of the glomerular lesion of nephritis.

Neither of these pathogenetic mechanisms, deposited complexes or anti-GBM antibodies, have been associated with a characteristic histopathologic glomerular lesion or clinical course in either the experimental model systems or in human diseases. Thus, both experimental serum sickness nephritis and anti-GBM antibody-induced nephritis may be associated with either a proliferative or membranous lesion (7). In addition, the clinical spectrum seen in human nephritis associated with anti-GBM antibodies may vary from the acute, fulminant, necrotizing glomerulitis seen in many patients

TABLE I A  
Biopsies from Patients

Patient	IgG	Heavy chain deposit				Light chain deposit		Complement deposit		
		$\gamma$ G1	$\gamma$ G2	$\gamma$ G3	$\gamma$ G4	K	$\lambda$	Clq	C4	C3
Ols	2+	0	<u>3+</u>	tr	0	—	—	2+	0	0
Hay	2+	0	<u>3+</u>	0	0	—	—	3+	0	tr
Joh	3+	tr	<u>3+</u>	tr	1+	3+	2+	1+	3+	3+
Sev	1+	0	<u>1+</u>	0	0	0	0	1+	0	0
Sau	3+	tr	<u>1+</u>	tr	0	—	—	tr	0	0
MacD	2+	1+	tr	0	<u>2+</u>	3+	tr	0	0	2+
Gry	2+	1+	tr	1+	tr	2+	tr	tr	0	3+
Tho	3+	3+	2+	tr	3+	3+	2+	0	0	3+
Ril	2+	<u>2+</u>	1+	0	tr	1+	2+	0	0	1+
Hel	3+	<u>3+</u>	2+	1+	3+	3+	2+	tr	tr	tr
Mal	3+	1+	1+	tr	0	1+	1+	2+	tr	tr
Total	11	8	11	7	6	7	7	8	3	8

$\gamma$ G and complement component composition of immune deposits and histologic findings in the nephritides.

Numbers in italics and underlined designate that the value represents the sole or dominant heavy chain subgroup detected in the biopsy.

\* The degree of endothelial (endo) and epithelial (epi) proliferation (prolif) in the glomerular tuft.

‡ Glomerular basement membrane thickening.

§ Mesangial (Mes) condensation.

|| The average number of neutrophile leukocytes per glomerulus.

¶ Fibrin thrombi in glomerular capillary loops.

\*\* Glomerular (glom) necrosis (necr).

with Goodpasture's syndrome, to the relatively indolent lesion of chronic glomerulonephritis (6).

These studies have suggested that host mechanisms, including immunoglobulins, may be important factors in determining the morphology, severity, and natural history of a given lesion.

As human gamma G globulin (IgG or  $\gamma$ G) consists of four heavy chain subgroups, each of which has individual biological properties, we have investigated the deposition of these subgroups in human glomerulonephritis in order to determine whether this deposition is selective and represents a variable in the glomerular lesion.

## METHODS

**Patient material.** 36 biopsies were studied for  $\gamma$ G subgroup deposition. All biopsies were selected on the basis of having shown the presence of  $\gamma$ G on the GBM on previous examination. 11 of these patients had chronic nephritis associated with systemic lupus erythematosus and 25 patients had other forms of glomerulonephritis. The latter group included 12 patients who had lumpy or granular deposits of  $\gamma$ G on the GBM. The following clinical or clinicopathologic diagnosis were made in these 12 patients: 7 chronic glomerulonephritis (membranous, proliferative, or mixed), 1 lobular

glomerulonephritis, 1 hypocomplementemic membranoproliferative glomerulonephritis, 1 rapidly progressive glomerulonephritis, 1 Sjögren's syndrome, and 1 luetic nephrosis. The 13 patients with linear deposits of  $\gamma$ G included 1 patient with Goodpasture's syndrome, 3 patients with rapidly progressive glomerulonephritis, and 9 patients with chronic glomerulonephritis (membranous, proliferative, or mixed).

## Immunofluorescent reagents

**Isolation of myeloma proteins.** Myeloma proteins<sup>1</sup> were isolated by starch block electrophoresis (8) and eluted with 0.01 M phosphate buffered saline (PBS).

**Antisera preparation.** Antisera were developed in rabbits, monkeys, and guinea pigs to isolated myeloma proteins of known  $\gamma$ G subgroup (9, 10)<sup>2</sup> which had been shown to be free of detectable contamination by Gm antigen typing. The antisera were tested by immunoelectrophoresis for  $\gamma$ G specificity and by Ouchterlony double diffusion in agar for subgroup specificity. Antisera were rendered subgroup specific by absorption with Bence Jones proteins, and myeloma proteins of other subgroups until they reacted with myeloma proteins of a single heavy chain subgroup as determined by

<sup>1</sup> We thank Doctors H. G. Kunkel, W. Maloney, R. McIntyre, C. Alper, S. Rivers, and others for their kind gift of myeloma sera.

<sup>2</sup> We thank Doctors H. G. Kunkel, W. Terry, and H. Borel for typing some of our myeloma sera and proteins.

Prolif*		GBM‡	Mes§	PMN   Avg/Glom	Fibrin¶ Thrombi	Glom** Necrosis
Endo	Epi					
tr	1+	tr	1+	20	1+	+
tr	2+	tr	tr	17	tr	tr
—	—	—	—	—	—	—
—	—	—	—	—	—	—
tr	2+	1+	tr	18	2+	2+
0	tr	tr	1+	15	tr	0
—	—	—	—	—	—	—
1+	2+	1+	tr	6	0	0
1+	2+	2+	1+	6	1+	0
—	—	—	—	—	—	—
—	—	—	—	—	—	—

Ouchterlony double diffusion in agar and the formation of a single diffusion precipitin ring upon radial immunodiffusion assay (11).

$\gamma$ G subgroup levels in sera were determined by radial immunodiffusion (11) using 1% agar in PBS buffer with sodium azide added.

**Complement components.** Antiserum to C1q was produced in rabbits using previously described techniques (12, 13). The antiserum, after absorption with R11S, formed a single precipitin line with serum or euglobulin on immunoelectrophoresis and Ouchterlony double diffusion (12). Antiserum to human C4 (beta-1-E globulin) was the kind gift of Drs. Stephen Rosenfeld and K. Frank Austen. Antihuman beta-1-C/beta-1-A antisera were obtained from Hyland Laboratories (Los Angeles, Calif.) or were produced in rabbits.

**Fluorescence microscopy.** Tissue was stored in air tight containers at  $-20^{\circ}\text{C}$ . Sections were cut in a  $-20^{\circ}\text{C}$  cryostat, 4–6  $\mu$  thick, air dried, and fixed in ethanol. Fluorescent staining was carried out using a previously reported technique (3). The fluorescein/protein ratio of conjugated antisera were all in the range of 2.5–3.9. Antialbumin antiserum was employed as a control. All sections were stained with fluorescein conjugated antisera to  $\gamma$ G,  $\gamma$ G1,  $\gamma$ G2,  $\gamma$ G3,  $\gamma$ G4; kappa, and lambda light chains, C1q, C4, and C3. Antisera to  $\gamma$ G subgroups used for fluorescence microscopy were appropriately diluted so that they had equivalent titers of 1:8 when tested against appropriate isolated myeloma proteins

in a concentration of 1 mg/ml in micro-Ouchterlony diffusion.

The quantification of specific immunofluorescence on the glomerulus was graded using the following criteria:

Negative (0)—no specific staining

Trace (tr)—occasional, specific staining usually involving less than 10% of the GBM

1+—up to 25% of the GBM involved by specific immunofluorescence

2+—intermediate value

3+—75–100% of the GBM involved by intense specific fluorescence

**Histopathology.** Sections of available biopsies stained with hematoxylin and eosin and periodic acid-Schiff were reviewed by a single observer. The glomerular alterations were categorized as to their over-all pattern, namely, proliferative, membranous, membranoproliferative (mixed), or lobular. The proliferative changes were subdivided into proliferation of epithelial and/or endothelial cells. The glomerular basement membrane was evaluated for increased thickness, and the mesangium for condensation. Glomerular capillary thrombi were sought for, as were areas of glomerular necrosis. These changes were scored from 0 to 4+ positive. The number of neutrophils (PMN's) in glomeruli were quantitated by taking the average of the actual count for at least 10 glomeruli.

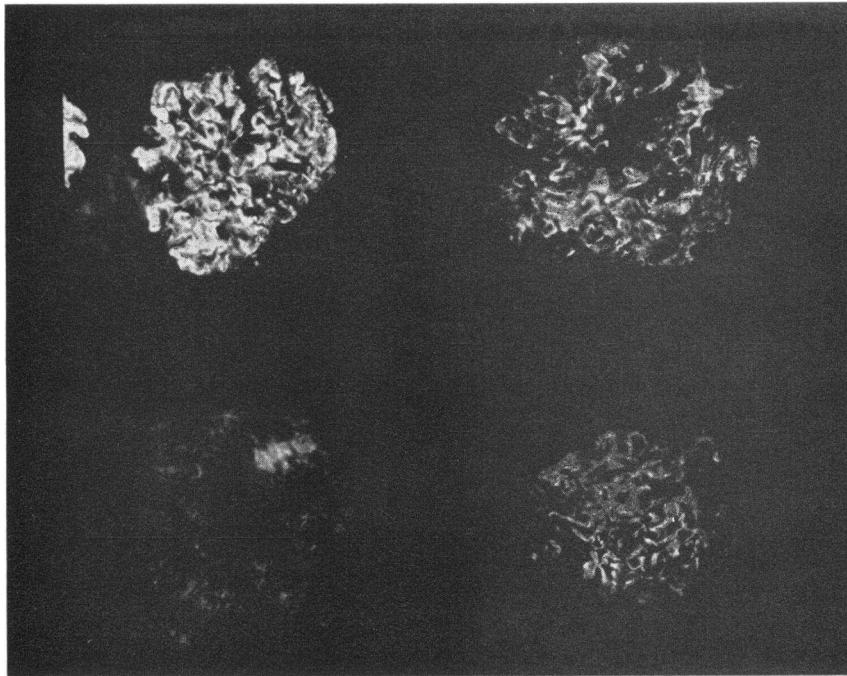


FIGURE 1  $\gamma$ G heavy chain deposition in a patient with lupus nephritis (Tho). Large amounts of  $\gamma$ G1 (upper left),  $\gamma$ G2 (upper right), and  $\gamma$ G4 (lower right) are present. Only trace amounts of  $\gamma$ G3 (lower left) are seen. The  $\gamma$ G is deposited in a very finely granular pattern without interruption along the GBM. Some mesangial  $\gamma$ G is also present.

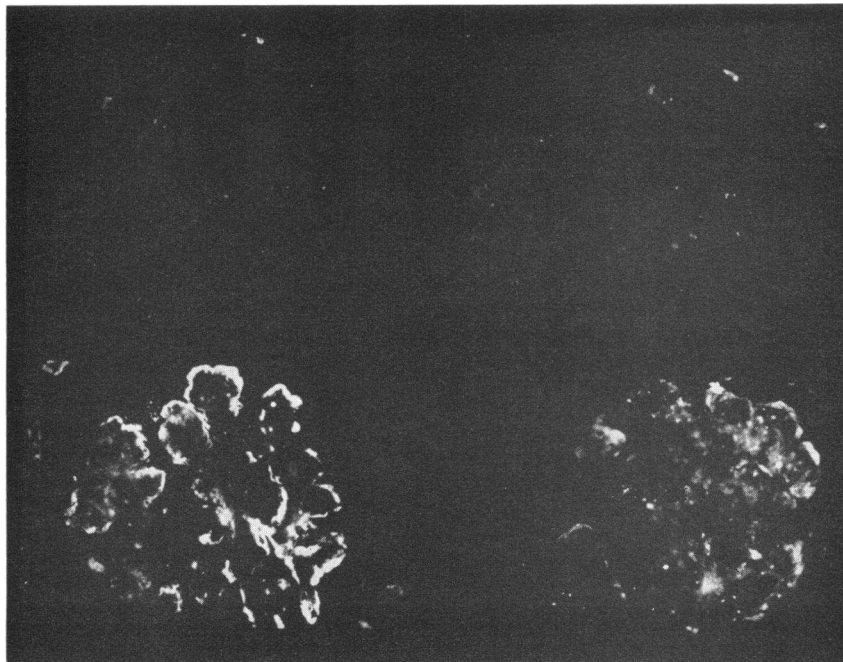


FIGURE 2  $\gamma$ G heavy chain deposition in a patient with lobular glomerulonephritis (Car). The deposit is composed mostly of  $\gamma$ G3 (lower left) with some  $\gamma$ G4 (lower right).

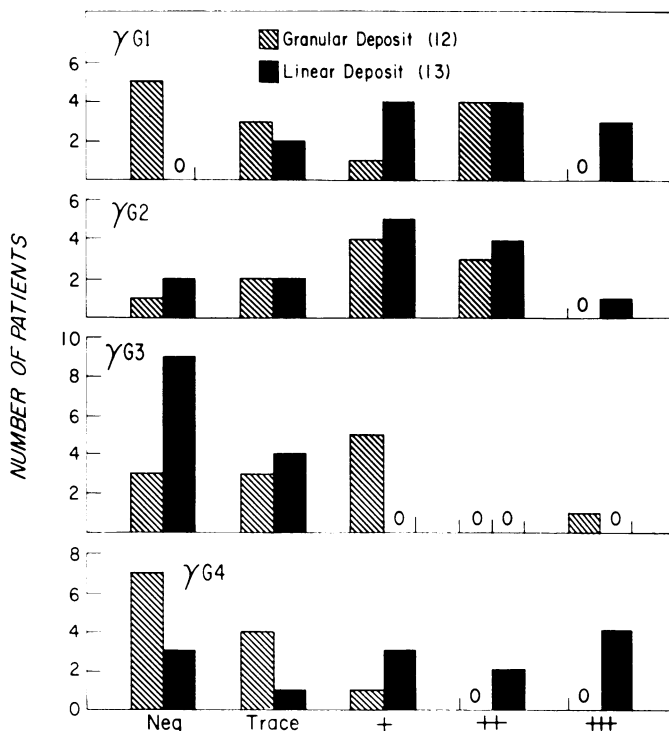


FIGURE 3 The intensity of fluorescent staining for each of the  $\gamma$ G heavy chain subgroups in patients with glomerulonephritis other than lupus nephritis, is plotted along the horizontal axis. It is noteworthy that no biopsies with linear staining for  $\gamma$ G had more than trace amounts of  $\gamma$ G3. Six biopsies from patients with lumpy or granular  $\gamma$ G deposits had 1-3+ staining for  $\gamma$ G3. Conversely,  $\gamma$ G4 was commonly seen in biopsies with linear staining, whereas only one biopsy with granular staining had a deposit that was quantified as 1+ or greater.

## RESULTS

### Fluorescence microscopy

#### LUPUS NEPHRITIS

*$\gamma$ G subgroup deposition.* (See Table IA) All 11 patients had  $\gamma$ G deposited on the glomerulus in a granular or lumpy pattern. The deposit contained  $\gamma$ G1 in 8 cases,  $\gamma$ G2 in 11 cases,  $\gamma$ G3 in 7 cases, and  $\gamma$ G4 in 6 cases.  $\gamma$ G1 was the dominant in one instance (Ril).  $\gamma$ G2 was the dominant subgroup in 5 biopsies, of which it was the only subgroup in 2 biopsies (Hay, Sev).  $\gamma$ G4 was the dominant subgroup in 1 biopsy (MacD). Four biopsies showed no subgroup dominance (Fig. 1).

*Complement component deposition.* One or more complement components were found in all biopsies. Clq was present in 8 cases, C4 in 3, and C3 in 8. Three components were localized in the GMB of three biopsies. The biopsies devoid of C3 all had  $\gamma$ G2 as the dominant heavy chain subgroup. Clq was seen in all of these latter cases (Ols, Sev. San).

*Histopathology.* Biopsies were available from five patients. Two patients had  $\gamma$ G2 deposits (Ols, Hay), one had a mixture of  $\gamma$ G1,  $\gamma$ G2, and  $\gamma$ G3 on the glomerulus (Sau), one had  $\gamma$ G1,  $\gamma$ G2, and  $\gamma$ G4 deposited (Ril), and one had all four subgroups present (Tho) (Fig. 1). Although the proliferative, membranous, and mesangial changes were similar in all five biopsies. The glomeruli which had Clq deposits tended to show the greatest number of PMN's and focal necrosis.

#### GLOMERULONEPHRITIS WITH GRANULAR OR LUMPY DEPOSITS, EXCLUDING LUPUS NEPHRITIS

*$\gamma$ G subgroup deposition.* (See Table I B) Seven biopsies contained  $\gamma$ G1 and 9 contained  $\gamma$ G2.  $\gamma$ G3 was seen in nine biopsies and  $\gamma$ G4 in five. The dominant subgroup was  $\gamma$ G1 in three cases (Par, Riv, Mor),  $\gamma$ G2 in four cases (Hoo, Mat, Guy, Bea),  $\gamma$ G3 in one case (Car) (Fig. 2). Of the seven biopsies with a predominant heavy chain subgroup type, six had a single or

TABLE IB  
Biopsies with Granular

Patient	Path†††	Clin diag§§	IgG	Heavy chain deposit				Light chain deposit	
				γG1	γG2	γG3	γG4	K	λ
Hoo		Syphilis	2+	0	2+	0	0	tr	2+
Gar		Sjogren's	1+	tr	0	1+	1+	—	—
Buc	P	HCGN	tr	tr	1+	1+	tr	tr	tr
Car		Lobular GN	3+	0	0	3+	tr	2+	tr
Mat	Mix	Ch GN	3+	0	2+	tr	0	2+	2+
Guy	Mix	Ch GN	2+	0	2+	1+	0	tr	3+
Nes		Ch GN	tr	tr	0	tr	0	tr	tr
Bea	P	Ch GN	tr	0	+	0	0	0	tr
Par	Mix	Ch GN	3+	2+	tr	1+	0	—	—
Riv	M	Ch GN	3+	2+	1+	1+	tr	3+	1+
Jon	M	Ch GN	2+	1+	1+	tr	tr	1+	2+
Mor		RP GN	3+	2+	1+	0	0	tr	1+
Total			12	7	9	9	5	9	10

γG and complement component composition of immune deposits and histologic findings in the nephritides.

\*\* See Table I A

‡ See Table I A.

§ See Table I A.

¶ See Table I A.

TABLE IC  
Biopsies with Linear

Patient	Clin diag§§	IgG	Heavy chain deposit				Light chain deposit	
			γG1	γG2	γG3	γG4	K	λ
Bil	Ch GN	3+	2+	3+	0	3+	3+	tr
Fla	GPS	3+	3+	2+	0	3+	3+	1+
Gai	Ch GN	3+	3+	2+	tr	3+	3+	3+
San	Ch GN	2+	1+	1+	tr	0	tr	—
Cip	Ch GN	2+	2+	tr	0	1+	1+	tr
Lyo	Ch GN	2+	2+	2+	0	2+	tr	1+
Ega	RPGN	3+	3+	1+	0	3+	2+	1+
Kin	Ch GN	2+	tr	0	0	1+	1+	0
Gal	Ch GN	1+	tr	tr	0	tr	—	—
Dod	RPGN	3+	2+	1+	tr	2+	2+	2+
Vuo	Ch GN	3+	1+	2+	tr	1+	2+	2+
Ver	Ch GN	2+	1+	1+	0	0	2+	1+
McM	RPGN	3+	1+	2+	0	0	2+	+
Total		13	13	12	4	10	11	10

γG and complement component composition of immune deposits and histologic findings in the nephritides.

\* See Table I A.

‡ See Table I A.

§ See Table I A.

Deposits of  $\gamma G$

Complement deposit			Prolif*		GBM†	Mes§	PMN   Avg/Glom	Fibrin¶ Thrombi	Glom** Necrosis
Clq	C4	C3	Endo	Epi					
0	0	0	1+	0	0	1+	0	0	0
0	0	0	tr	1+	tr	tr	9	tr	tr
tr	tr	2+	1+	2+	tr	tr	18	0	0
0	0	3+	tr	tr	3+	2+	14	tr	0
0	1+	2+	1+	1+	2+	1+	14	2+	0
0	0	tr	tr	1+	1+	2+	11	1+	0
0	0	3+	—	—	—	—	—	—	—
0	0	2+	0	tr	tr	1+	15	tr	0
—	—	—	tr	1+	1+	1+	19	tr	0
tr	0	2+	tr	+	3+	1+	5	tr	0
tr	tr	2+	tr	1+	3+	tr	9	2+	0
tr	tr	1+	—	—	—	—	—	—	—
4	4	9							

\*\* See Table I A.

†† Pathological (path) diagnosis: M, membranous glomerulonephritis; P, proliferative glomerulonephritis; Mix, both membranous and proliferative elements present.

§§ Clinical diagnosis (clin diag): HCGN, hypocomplementemic glomerulonephritis; Ch<sub>4</sub>GN, chronic glomerulonephritis; RPGN, rapidly progressive glomerulonephritis; GPS, Goodpasture's Syndrome.

Deposit of  $\gamma G$

Complement deposit			Prolif*		GBM†	Mes§	PMN   Avg/Glom	Fibrin¶ Thrombi	Glom** Necrosis
Clq	C4	C3	Endo	Epi					
0	0	2+	tr	tr	1+	tr	4	1+	0
0	0	0	tr	2+	tr	tr	2	tr	0
0	0	3+	tr	1+	2+	0	3	0	0
0	0	3+	1+	1+	1+	1+	7	tr	0
0	0	2+	1+	tr	1+	1+	3	0	0
—	—	—	1+	tr	3+	3+	2	tr	0
0	0	2+	tr	4+	tr	tr	22	3+	1+
0	0	2+	tr	tr	1+	1+	7	1+	0
—	—	—	0	1+	1+	0	2	0	0
0	0	2+	—	—	—	—	—	—	—
+	0	2+	tr	3+	tr	0	2	0	0
1+	0	1+	tr	1+	2+	1+	10	0	0
+	0	tr	—	—	—	—	—	—	—
3	0	10							

|| See Table I A.

¶ See Table I A.

\*\* See Table I A.

§§ See Table I A.



TABLE II  
Serum  $\gamma$ G Subgroup Levels

	IgG	$\gamma$ G1	$\gamma$ G2	$\gamma$ G3	$\gamma$ G4
	mg/ml	% of total serum IgG			
SLE patients					
Joh, <u><math>\gamma</math>G2</u>	14.8	71.6	8.8	17.6	2.0
Sev, <u><math>\gamma</math>G2</u>	27.4	90.1	7.3	1.8	0.7
MacD, <u><math>\gamma</math>G4</u>	10.7	73.8	22.4	2.8	0.9
Gry	50.35	73.5	11.1	5.75	1.6
Tho	9.8	74.5	15.3	7.1	3.0
Ril, <u><math>\gamma</math>G1</u>	16.1	62.1	34.2	3.1	0.6
Hel	32.5	80.0	14.8	3.7	1.5
Patients with granular IgG deposits					
Hoo, <u><math>\gamma</math>G2</u>	18.25	81.6	12.0	5.75	0.5
Buc	9.7	74.2	16.5	8.2	1.0
Car, <u><math>\gamma</math>G3</u>	7.2	73.6	18.0	6.9	1.4
Mor, <u><math>\gamma</math>G1</u>	11.7	81.2	12.8	4.3	1.7
Bea	12.0	75.8	15.0	8.3	0.8
Patients with linear IgG deposits					
Bil	7.4	82.4	6.75	5.4	5.4
Cip	4.0	61.7	30.9	2.5	4.9
Gai	12.1	66.9	21.5	6.6	4.95
Kin	15.4	86.3	7.8	5.2	0.6
McM	19.9	72.9	14.6	9.5	3.0
Natvig et al (10)		70.0	18.0	8.0	3.0

Total serum IgG and  $\gamma$ G subgroup levels were determined in 17 patients with glomerulonephritis. The subgroup (in italics and underlined) represents the dominant subgroup present on the glomerulus and corresponds to the results tabulated in Table I A, I B, and I C.

predominant kappa (Riv, Car), or lambda (Mor, Hoo, Guy, Bea) light chain type.

**Complement component deposition.** 1 or more of the 3 complement components studied, Clq, C4, and C3, were present in 9 of the 12 cases. Clq was seen in four biopsies, C4 in four biopsies, and C3 in nine biopsies. Four of the biopsies contained C3 only. In contrast to the kidneys with lupus nephritis, Clq was not present in any of the biopsies in which  $\gamma$ G2 was the predominating or sole subgroup deposited.

**Histopathology.** Nine biopsies were examined; two showed predominantly proliferative changes (Buc, Bea), two showed membranous changes (Riv, Jon), four had both membranous and proliferative (mixed) changes (Car, Nat, Guy, Par), and one had minimal mesangial changes (Hoo). The latter biopsy had a  $\gamma$ G2 deposit, and PMN's were absent from the glomeruli. One patient (Car) had dominant  $\gamma$ G3 deposits and had a lobular glomerular pattern. Otherwise, the glomerular patterns did not correlate with specific subgroup deposits. Most of the biopsies in this group, even those devoid of Clq, had large numbers of PMN's in glomeruli.

## GLOMERULONEPHRITIS WITH LINEAR $\gamma$ G DEPOSITS

**$\gamma$ G subgroup deposition.**  $\gamma$ G1 was found in all 13 biopsies,  $\gamma$ G2 in 12,  $\gamma$ G3 in 4, and  $\gamma$ G4 in 10. There was no dominant pattern in the heavy chain deposits except that  $\gamma$ G3 was generally absent but, when found, was present in small amounts (Fig. 3).  $\gamma$ G4 was present in larger amounts in biopsies with linear deposits than in those with granular or lumpy deposits (Fig. 3).

**Complement component deposition.** C3 was found in 10 of the 11 biopsies studied. Weak deposits of Clq were found in three biopsies, of which one case had rapidly progressive glomerulonephritis (McM), and two cases had chronic glomerulonephritis.

**Histopathology.** 11 biopsies were examined; 3 showed proliferative lesions (Fla, Ega, Vuo), 4 had membranous lesions (Gai, Lyo, Kin, Gal), and 3 had mixed lesions (Bil, Sau, Cip). Biopsies with heavy deposits of  $\gamma$ G4 (Bil, Fla, Gai, Lyo, Ega) tended to have few neutrophile leukocytes in glomeruli.

### Serum $\gamma$ G subgroup levels

(See Table II)  $\gamma$ G subgroup levels were measured in seven patients with lupus nephritis, five with nephritis with granular  $\gamma$ G deposits, and five with nephritis with linear  $\gamma$ G deposits. The normal level of total serum  $\gamma$ G in our laboratory is 12–18 mg/ml (14). Hypergammaglobulinemia was found in four patients with lupus nephritis (Sev, Gry, Ril, Hel), one patient with lumpy  $\gamma$ G deposits (Hoo) and one patient with linear  $\gamma$ G deposits (McM). Hypogammaglobulinemia was seen in one patient with granular and lumpy  $\gamma$ G deposits (Car) and two patients with linear  $\gamma$ G deposits (Cip, Bil). The selective glomerular deposit of a dominant subgroup in four patients with lupus nephritis, and three patients with granular and/or lumpy deposits did not reflect any selective increase in the serum concentration of the corresponding subgroup on the patient's glomerulus.

## DISCUSSION

Human  $\gamma$ G comprises four subgroups which differ in the structure of their gamma heavy chains. These subgroups vary in their concentration in serum as well as in their synthetic and catabolic rates and in certain biologic properties (10, 15). For example,  $\gamma$ G1 and  $\gamma$ G3 fix complement well,  $\gamma$ G2 fixes complement poorly, and  $\gamma$ G4 does not fix complement (16, 17). This variability in complement fixing properties of the  $\gamma$ G subgroups may have special relevance with respect to the occurrence of glomerular inflammation in nephritis. Ward and Cochrane have shown that the fixation of complement and the generation of leukocyte chemotactic factor are important to the development of the lesion of experi-

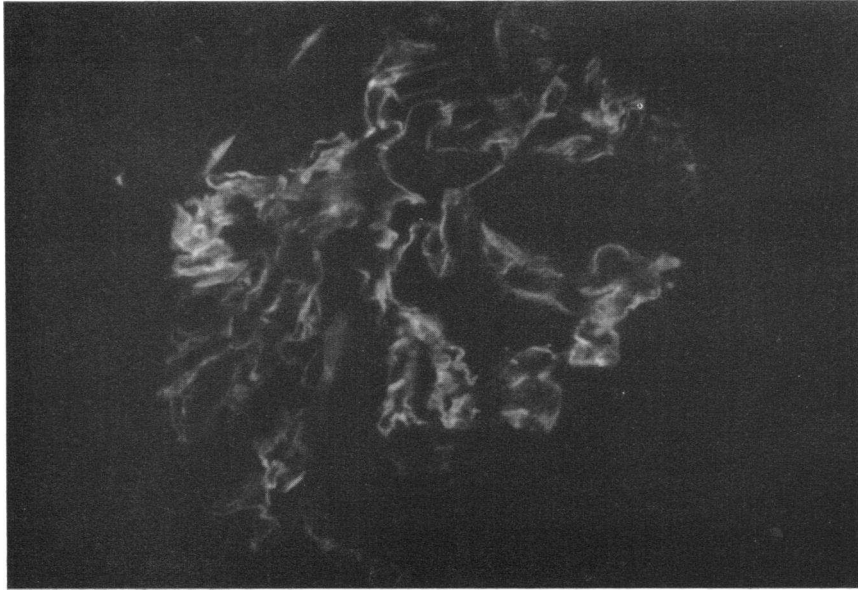


FIGURE 4 The linear deposition of  $\gamma$ G4 along the GBM. A heavy uninterrupted deposit of the immunoglobulin strongly suggestive that the  $\gamma$ G4 has antiglomerular basement membrane activity, is noted in patient EGA's biopsy.

mental nephrotoxic glomerulonephritis and the Arthus phenomenon (18, 19). The induction of nephrotoxic nephritis using avian antiserum, which does not fix complement, is not associated with PMN accumulation in the glomeruli (20). It is therefore possible that the subgroup composition of a given antibody which becomes deposited on the GBM in human glomerulonephritis will elicit a variable inflammatory response depending upon its ability to fix complement.

In the present study, the deposition of  $\gamma$ G subgroups on the GBM differed from the relative amount of each subgroup found in normal serum:  $\gamma$ G1 = 70%,  $\gamma$ G2 = 18%,  $\gamma$ G3 = 8%, and  $\gamma$ G4 = 3% of the total  $\gamma$ G (10). Absence of a particular subgroup in the glomerular deposit did not reflect an abnormality in the serum concentration of the subgroup. This observation infers that  $\gamma$ G deposits in glomerulonephritis are selective and supports the likelihood of their antibody nature.

Patients who had lumpy or granular deposits of  $\gamma$ G, which suggest an immune complex pathogenesis, tended to have selective deposits of  $\gamma$ G composed of a single or dominant subgroup. Thus, four patients with lupus nephritis, three patients with chronic glomerulonephritis, and a case of luetic nephrosis had deposits that were almost entirely composed of  $\gamma$ G2. The  $\gamma$ G2 deposit in the latter case was not associated with detectable Clq, C4, or C3. In addition, there were no neutrophil leukocytes present in the glomerulus in this biopsy. The inability of the  $\gamma$ G2 deposit in this case to fix complement *in vivo* or to be associated with leukocyte infil-

tration would appear to correlate well with the poor *in vitro* complement-fixing properties of this subgroup (16, 17).

The pattern of deposition of complement components Clq, C4, and C3 differed in patients with lupus nephritis as compared to patients who had other forms of nephritis associated with granular  $\gamma$ G deposits. Clq was seen more frequently in lupus nephritis than in other nephritides and the deposition of this component, which is capable of interacting with  $\gamma$ G (17), was not necessarily accompanied by the detection of the later components, C4 or C3. In contrast, patients with other forms of nephritis had little Clq in the glomerulus but had C3 associated with the immune deposit. Perhaps the immune complex involved in lupus nephritis has a greater affinity for Clq than do complexes in other nephritides regardless of the antibody heavy chain class. The glomerular deposit in lupus nephritis has been shown to contain DNA (3) which is capable of interacting with Clq *in vitro* in the absence of immunoglobulins (21).

Patients with the linear deposition of  $\gamma$ G along the glomerular basement membrane, characteristic of the nephritis associated with anti-GBM antibodies, did not tend to selectively deposit an individual heavy chain subgroup. On the contrary, large amounts of  $\gamma$ G1,  $\gamma$ G2, and  $\gamma$ G4 were present in the majority of these patients. However,  $\gamma$ G3 was either absent or present in only trace amounts in these linear deposits. It is possible that this paucity of  $\gamma$ G3 deposits reflects the increased catabolic rate of this protein (15). However, the selec-

tive absence of a subgroup may also bear relevance with respect to the immunizing antigen. Yount, Dorner, Kunkel, and Kabat (22) have presented evidence that the  $\gamma$ G heavy chain subgroups making up a given antibody may be determined by the chemical makeup of the antigen. Thus, anti-A isoagglutinins and anti-tetanus toxoid antibodies were predominantly  $\gamma$ G1, while antibodies to dextran and teichoic acid were  $\gamma$ G2. The latter observation, that polysaccharide antigens elicit  $\gamma$ G2 antibodies, may also have relevance in lupus nephritis, insofar as lupus patients form antibodies which react with nuclear glycoprotein (23). An additional observation which relates to the selective functional difference in  $\gamma$ G3 heavy chains has been made by Kronvall and Williams (24), who showed that antistaphylococcal protein A activity is found in  $\gamma$ G1,  $\gamma$ G2, and  $\gamma$ G4 myeloma proteins and not in  $\gamma$ G3 myeloma proteins. The relevance of this observation to antibody formation or deposition is not clear at present.

As  $\gamma$ G4 does not fix complement (16, 17), the presence of large amounts of  $\gamma$ G4 in some glomerular deposits, particularly in cases with linear deposits, (Fig. 4) suggests that renal damage may occur through mechanisms independent of complement-mediated leukocyte chemotaxis. The induction of proteinuria in experimental nephrotoxic nephritis using avian antisera demonstrates that glomerular damage can occur in the absence of complement-fixing antibody (20). The recent observation that some patients with focal glomerulonephritis may have deposits of only immunoglobulin A, which does not fix complement, further suggests that another non-complement-fixing antibody may also have a pathogenic role in nephritis (25). The relative absence of neutrophil leukocytes in patients with linear deposits may thus relate to the presence of either large amounts of noncomplement-fixing antibody or the absence of  $\gamma$ G3 antibody.

Our results indicate that the  $\gamma$ G which is present in glomerular deposits of patients with nephritis has a restricted gamma heavy chain subgroup composition. The variation in biological properties of these subgroups may account for differences in the inflammatory reaction that occurs in the glomerulus and this may reflect upon the severity and clinical outcome of the renal disease.

#### ACKNOWLEDGMENTS

We wish to thank Mrs. Phyllis Vineyard, Miss Margaret Monroe, and Dr. S. Salazar for their excellent technical assistance. We also thank Dr. J. Decker for allowing us to examine biopsy material from four of his patients.

This work was carried out during the tenure of U. S. Public Health Service Special Fellowship 1 FO3 AM 19727, and was supported by grants from the U. S. Public Health Service (AM 11414, AM 12051, AM 5076, HE 06370, HE 1771), and a grant from the Massachusetts Kidney Foundation.

#### REFERENCES

- Dixon, F. J., J. D. Feldman, and J. J. Vazquez. 1961. Experimental glomerulonephritis: the pathogenesis of a laboratory model resembling the spectrum of human glomerulonephritis. *J. Exp. Med.* **113**: 899.
- Koffler, D., and F. Paronetto. 1965. Immunofluorescent localization of immunoglobulins, complement, and fibrinogen in human disease. II. Acute, subacute, and chronic glomerulonephritis. *J. Clin. Invest.* **44**: 10.
- Koffler, D., P. H. Schur, and H. G. Kunkel. 1967. Immunological studies concerning the nephritis of systemic erythematosus. *J. Exp. Med.* **126**: 607.
- Michael, A. F., Jr., K. N. Drummond, R. A. Good, and R. L. Vernier. 1966. Acute poststreptococcal glomerulonephritis: immune deposit disease. *J. Clin. Invest.* **45**: 237.
- Braunstein, G. D., E. J. Lewis, E. G. Galvanek, A. Hamilton, and W. R. Bell. 1970. The nephrotic syndrome associated with secondary syphilis: an immune deposit disease. *Amer. J. Med.* In press.
- Lerner, R. A., R. H. Glasscock, and F. J. Dixon. 1967. The role of antiglomerular basement membrane antibody in the pathogenesis of human glomerulonephritis. *J. Exp. Med.* **126**: 989.
- Germuth, F. G., Jr., L. B. Senterfeit, and A. D. Pollack. 1967. Immune complex disease. I. Experimental acute and chronic glomerulonephritis. *Johns Hopkins Med. J.* **120**: 225.
- Kunkel, H. G., and R. J. Slater. 1952. Zone electrophoresis in a starch supporting medium. *Proc. Soc. Exp. Biol. Med.* **80**: 42.
- Grey, H. M., and H. G. Kunkel. 1964. H chain subgroups of myeloma proteins and normal 7S-gamma globulin. *J. Exp. Med.* **120**: 253.
- Natvig, J. B., H. G. Kunkel, and S. D. Litwin. 1967. Genetic markers of the heavy chain subgroups of human gamma g globulin. *Cold Spring Harbor Symp. Quant. Biol.* **32**: 173.
- Fahey, J. L., and E. M. McKelvey. 1965. Quantitative determination of serum immunoglobulins in antibody-agar plates. *J. Immunol.* **94**: 84.
- Morse, J. H., and C. L. Christian. 1964. Immunological studies of the 11S protein component of the human complement system. *J. Exp. Med.* **119**: 195.
- Müller-Eberhard, H. J. 1968. Chemistry and reaction mechanisms of complement. *Advan. Immunol.* **8**: 2.
- World Health Organization Committee. 1964. *Bull. World Health Organ.* **30**: 447.
- Morell, A., W. Terry, and T. Waldmann. 1969. Relation between metabolic properties and serum concentration of IgG-subclasses in man. *Clin. Res.* **17**: 356. (Abstr.)
- Ishizaka, T., K. Ishizaka, S. Salmon, and H. Fudenberg. 1967. Biologic activities of aggregated gamma globulin. VIII. Aggregated immunoglobulins of different classes. *J. Immunol.* **99**: 82.
- Müller-Eberhard, H. J., and M. A. Calcott. 1966. Interaction between C1q and gamma g globulin. *Immunochimistry.* **3**: 500. (Abstr.)
- Ward, P. A., and C. G. Cochrane. 1965. Bound complement and immunologic injury of blood vessels. *J. Exp. Med.* **121**: 215.
- Cochrane, C. G., E. R. Unanue, and F. J. Dixon. 1965. A role of the polymorphonuclear leukocytes and complement in nephrotoxic nephritis. *J. Exp. Med.* **122**: 99.

20. Hammer, D. K., and F. J. Dixon. 1962. Experimental glomerulonephritis. II. Immunologic events in the pathogenesis of nephrotoxic serum nephritis in the rat. *J. Exp. Med.* **117**: 1019.
21. Agnello, V., R. I. Carr, D. Koffler, and H. G. Kunkel. 1969. Gel diffusion reactions of Clq with aggregated gamma globulin, DNA, and various ionic substances. *Fed. Proc.* **28**: 2447. (Abstr.)
22. Yount, W. J., M. A. Dorner, H. G. Kunkel, and E. A. Kabat. 1968. Studies on human antibodies. IV. Selective variations in subgroup composition and genetic markers. *J. Exp. Med.* **127**: 633.
23. Tan, E. M., and H. G. Kunkel. 1966. Characteristics of a soluble nuclear antigen precipitating with sera of patients with systemic lupus erythematosus. *J. Immunol.* **96**: 464.
24. Kronvall, G., and R. C. Williams, Jr. 1969. Differences in antiprotein A activity among IgG subgroups. *J. Immunol.* **103**: 828.
25. Berger, J. 1969. IgA deposits in renal disease. *Transplant. Proc.* **1**: 939.