

## Intraglomerular fibrin, platelet aggregation, and subendothelial deposits in lipid nephrosis

John L. Duffy, ... , Edith Grishman, Jacob Churg

*J Clin Invest.* 1970;49(2):251-258. <https://doi.org/10.1172/JCI106234>.

### Research Article

We have investigated the formation of fibrin, platelet aggregates, and subendothelial deposits in lipid nephrosis. Fibrin formation was found in 10 cases of active lipid nephrosis. Platelet aggregates were found in eight cases and subendothelial deposits in nine. Fibrin and platelets were also found in cases of nephrotic syndrome due to other causes, and in glomerulonephritis. Fibrin was generally absent in lipid nephrosis in remission and in benign recurrent hematuria. It is suggested that what seems to be a lower incidence in females is more apparent than real and that fibrin or related material may be present in a less easily identifiable form. Steroid therapy apparently had no effect on the presence or absence of fibrin. Most instances were associated with elevated serum cholesterol and  $\alpha_2$ -globulin. It is suggested that elevated serum lipids as well as the disease process in the kidney play a role in this phenomenon. It is further suggested that intraglomerular fibrin formation could lead to irreversible renal damage in lipid nephrosis.

**Find the latest version:**

<https://jci.me/106234/pdf>



# Intraglomerular Fibrin, Platelet Aggregation, and Subendothelial Deposits in Lipoid Nephrosis

JOHN L. DUFFY, THOMAS CINQUE, EDITH GRISHMAN, and JACOB CHURG

*From the Department of Pathology and Laboratories, and the Renal Division, Department of Medicine, Meadowbrook Hospital, East Meadow, New York 11554; and the Division of Renal Pathology, Department of Pathology, Mount Sinai School of Medicine of the City University of New York, New York 10029*

**ABSTRACT** We have investigated the formation of fibrin, platelet aggregates, and subendothelial deposits in lipoid nephrosis. Fibrin formation was found in 10 cases of active lipoid nephrosis. Platelet aggregates were found in eight cases and subendothelial deposits in nine. Fibrin and platelets were also found in cases of nephrotic syndrome due to other causes, and in glomerulonephritis. Fibrin was generally absent in lipoid nephrosis in remission and in benign recurrent hematuria. It is suggested that what seems to be a lower incidence in females is more apparent than real and that fibrin or related material may be present in a less easily identifiable form. Steroid therapy apparently had no effect on the presence or absence of fibrin. Most instances were associated with elevated serum cholesterol and  $\alpha_2$ -globulin. It is suggested that elevated serum lipids as well as the disease process in the kidney play a role in this phenomenon. It is further suggested that intraglomerular fibrin formation could lead to irreversible renal damage in lipoid nephrosis.

## INTRODUCTION

The role played by thrombotic phenomena in renal disease has been well demonstrated (1, 2). Fibrin aggregates have been described in acute glomerulonephritis (3), and recently heparin has been successfully used in the therapy of acute renal failure in this and similar nephropathies (4). The association of spontaneous thrombosis in renal veins or pulmonary arteries with the nephrotic syndrome is also well known, and it has been suggested that steroid therapy may increase the incidence of thrombotic events (5). Recently, increased fibrinogen in the blood and fibrin deposition in glomeru-

lar capillaries have been reported in nephrotic individuals (6). However, it is difficult to demonstrate small amounts of fibrin in standard histologic preparations or even by immunofluorescent methods. Although the latter identify fibrinogen as well as fibrin, electron microscopy can both detect small amounts of fibrin and localize it and other deposits more accurately. We have investigated intraglomerular fibrin formation, platelet aggregation, and subendothelial deposits in lipoid nephrosis and the possible role of these phenomena in causing glomerular damage.

## METHODS

The material studied was human renal cortical tissue obtained by percutaneous needle biopsy for diagnostic purposes. Small portions were immediately minced and fixed for 1 hr in 1% phosphate-buffered osmic acid (pH 7.2-7.5), or were first minced and fixed for 1 hr in phosphate-buffered glutaraldehyde and postfixed in osmic acid. The material was then dehydrated in graded alcohols and embedded in Epon 812, using standard methods. Unstained Epon sections approximately 2  $\mu$  thick were made of at least two, but usually four, glomeruli in each case. These were examined by phase microscopy. Areas in which the capillary lumina demonstrated unexplained increased opacity were selected for examination by electron microscopy. In cases where no such areas were observed, at least two, but usually three, random glomeruli were processed. Ultra-thin sections were placed on 200 mesh copper grids and double stained with uranyl acetate and lead hydroxide. Each grid was examined completely with an RCA EMU 3H operating at 100 kv, the grid being carefully scanned so that no area would miss examination. In this manner an average of 17 sections of at least two, but usually three, glomeruli were extensively examined in all negative cases. The intensity with which these specimens were examined cannot be overemphasized. It was observed that when a grid was completely examined a single point of interest was rarely seen in more than five sections and not infrequently came into view only once or twice. Glomeruli showing obvious evidence of damage during biopsy or findings indicating delayed fixation were dis-

*Received for publication 22 July 1969 and in revised form 19 September 1969.*

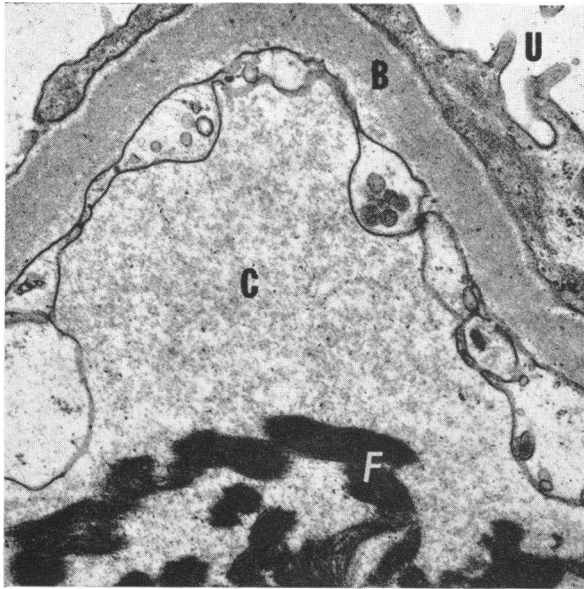


FIGURE 1 Intraglomerular fibrin in lipid nephrosis. Although periodic cross banding is indistinct, the fibrillary nature of the densely staining fibrin (F) in the capillary lumen (C) is apparent. B, basement membrane; U, urinary space. Case No. 7. Uranyl acetate and lead hydroxide,  $\times 21,000$ .

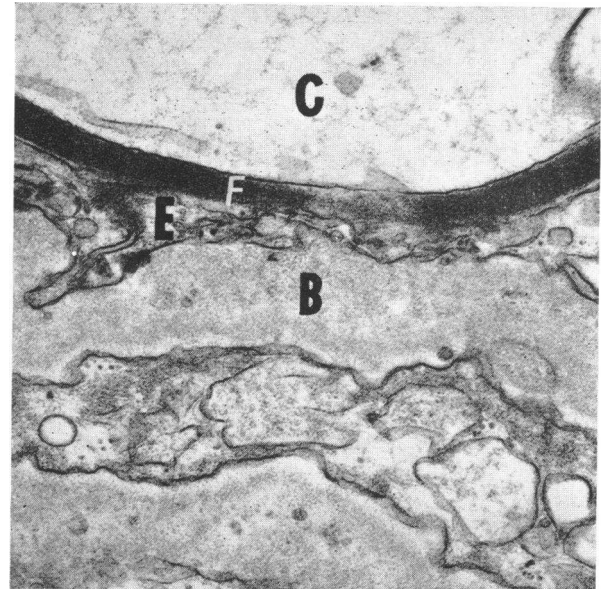


FIGURE 2 Fibrin (F) apparently attached to glomerular capillary endothelium (E) in lipid nephrosis. Periodic cross banding of approximately 230 Å is readily apparent. B, basement membrane; C, capillary lumen. Case No. 6. Uranyl acetate and lead hydroxide,  $\times 30,000$ .

carded. In some cases, previous routine micrographs were also studied. These had usually been stained only with uranyl acetate and examined at 50 kv.

Some cases were also studied by immunofluorescence. Small portions of the percutaneous biopsy were embedded in 7% gelatin in saline and quick frozen. 2- to 5- $\mu$  cryostat sections were washed three times, 5 min each, in phosphate-buffered saline (pH 7.2), then treated in acetone, 4°C for 30 sec and washed again briefly with buffer. The sections were then stained with two drops of commercial fluorescein-labeled antisera<sup>1</sup> for 30 min at room temperature, washed in three more changes of buffer, and cover slipped using phosphate-buffered glycerol mounting media (pH 7.2). Various sections were stained respectively with anti-human  $\beta 1c/\beta 1a$  globulin, anti-human gamma globulin, anti-human fibrin, and anti-human fibrinogen which had been previously diluted 1:10 with distilled water and absorbed with guinea pig liver powder. The sections were examined with dark field illumination through a fluorescence microscope with an Osram HBO 200 lamp and BG 12 excitor and K 530 barrier filters.

Table I lists the cases chosen for intensive study as outlined above (cases 1-18). The control cases, listed in Tables II and III, were studied in the same manner. As can be seen, an attempt was made to compare cases associated with nephrotic syndrome, cases of severe glomerular disease, and bland conditions such as benign recurrent hematuria and nephrosclerosis.

### Pathologic criteria

The findings we consider significant may be divided into four categories: fibrin formation, platelet aggregation, sub-endothelial deposits, and focal glomerular capillary collapse.

<sup>1</sup>Hyland Laboratories, Los Angeles, Calif.

*Fibrin formation.* Material considered to be fibrin consisted of parallel arrays of densely stained fibers (Fig. 1). These averaged approximately 30 Å in width and were arranged uniformly approximately 30 Å from one another.

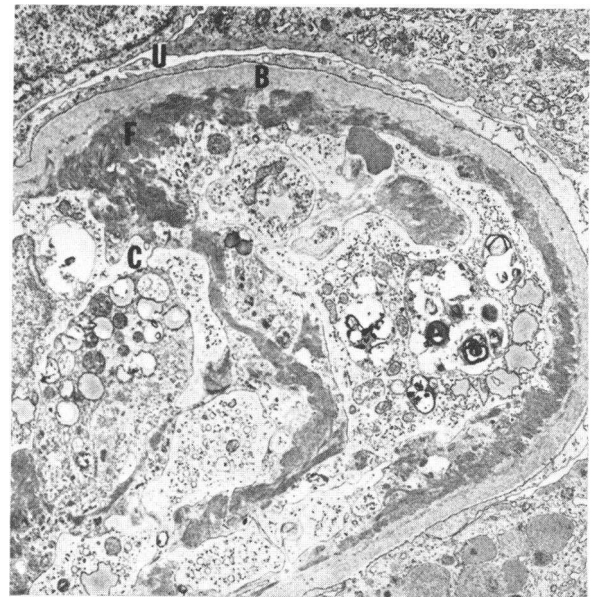


FIGURE 3 Glomerular capillary lumen (C) practically obliterated by mass of fibrin (F) and cells in lipid nephrosis. The fibrin (F) is directly attached to the glomerular basement membrane (B). U, urinary space. Case No. 9. Uranyl acetate and lead hydroxide,  $\times 5000$ .

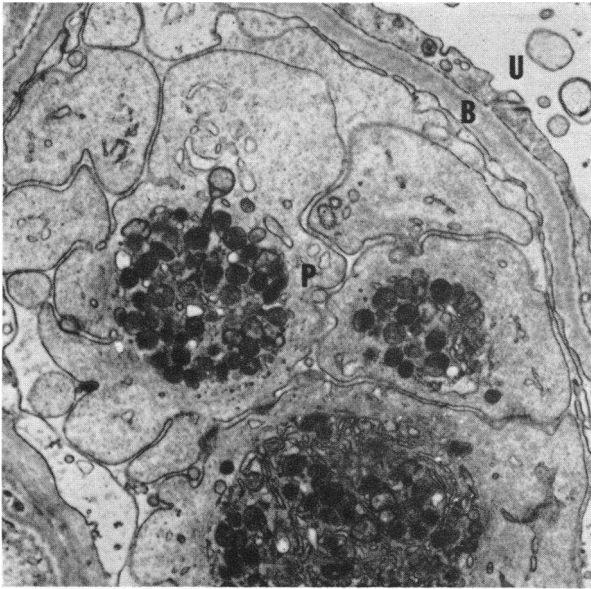


FIGURE 4 Intracapillary platelet aggregate (*P*) in lipid nephrosis. *B*, basement membrane; *U*, urinary space. Case No. 24. Uranyl acetate and lead hydroxide,  $\times 13,000$ .

Axial periodicity of approximately 230 A (Fig. 2), although present in all cases, was frequently indistinct or imperfect and could not be identified in all areas. The fibrin was not diffusely distributed throughout the glomerulus but rather was found in from only one to rarely more than three

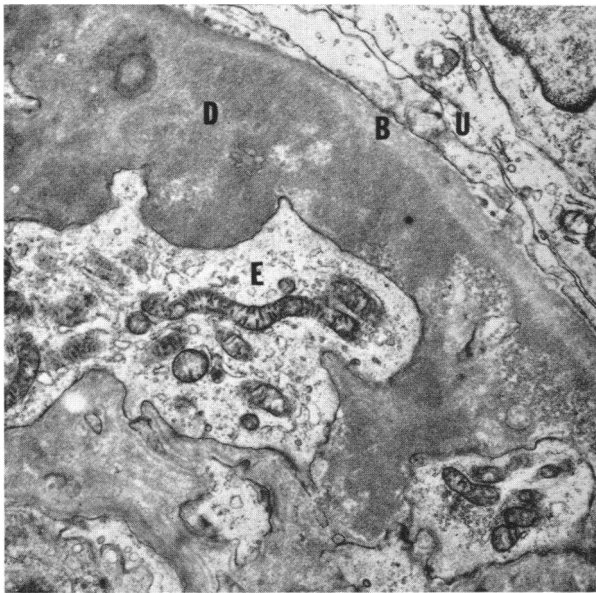


FIGURE 5 Subendothelial deposit in lipid nephrosis. The inner border of the basement membrane (*B*) is indistinct and probable remnants of subcellular organelles are noted within the deposit (*D*). *E*, endothelial cytoplasm; *U*, urinary space. Case No. 22. Uranyl acetate and lead hydroxide,  $\times 10,000$ .

neighboring capillary loops, and usually only one of three glomeruli studied was involved. In most instances the fibrin was observed free within the capillary lumen and was unassociated with platelet aggregation, although in some cases fibrin was found only enmeshed with platelets. Pure fibrin aggregates were definitely attached to the capillary wall in one case (Fig. 3), and very probably attached in three other cases of lipid nephrosis (Fig. 2).

**Platelet aggregation.** The apparent loose adherence of from two to four thrombocytes with little or no condensation of granules and intact plasma membranes was not an infrequent occurrence in a great variety of conditions. It was felt that this phenomenon could happen very rapidly and could therefore be secondary to the biopsy procedure. Therefore, only cases in which four or more platelets were tightly aggregated and showed at least partial dissolution of plasma membranes and granules were accepted as positive (Fig. 4). Although fibrin was enmeshed with the platelets in some instances, its presence was not considered necessary. Platelet aggregates both with and without associated fibrin formation almost invariably appeared adherent to the adjacent capillary epithelium. Usually only one and never more than two platelet aggregates were found in any given case.

**Subendothelial deposits.** Focal, densely staining subendothelial deposits were not infrequent. (Fig. 5). The material comprising these deposits was morphologically indistinguishable from that seen in various locations in several other conditions such as systemic lupus erythematosus and acute post-streptococcal glomerulonephritis, except that in the present cases they were strictly focal and applied against the luminal surface of the glomerular capillary basement membrane. Under high magnification this material appeared very finely granular and did not resemble fibrin. It occasionally contained what appeared to be remnants of sub-

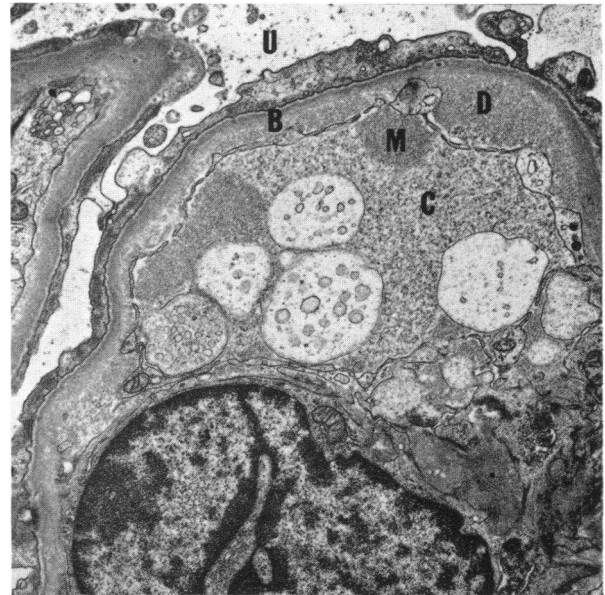


FIGURE 6 Intraluminal material (*M*) indistinguishable from subendothelial deposits (*D*) and apparently contiguous with them through endothelial fenestrations. *B*, basement membrane; *C*, capillary lumen; *U*, urinary space. Case No. 13. Uranyl acetate and lead hydroxide,  $\times 11,000$ .

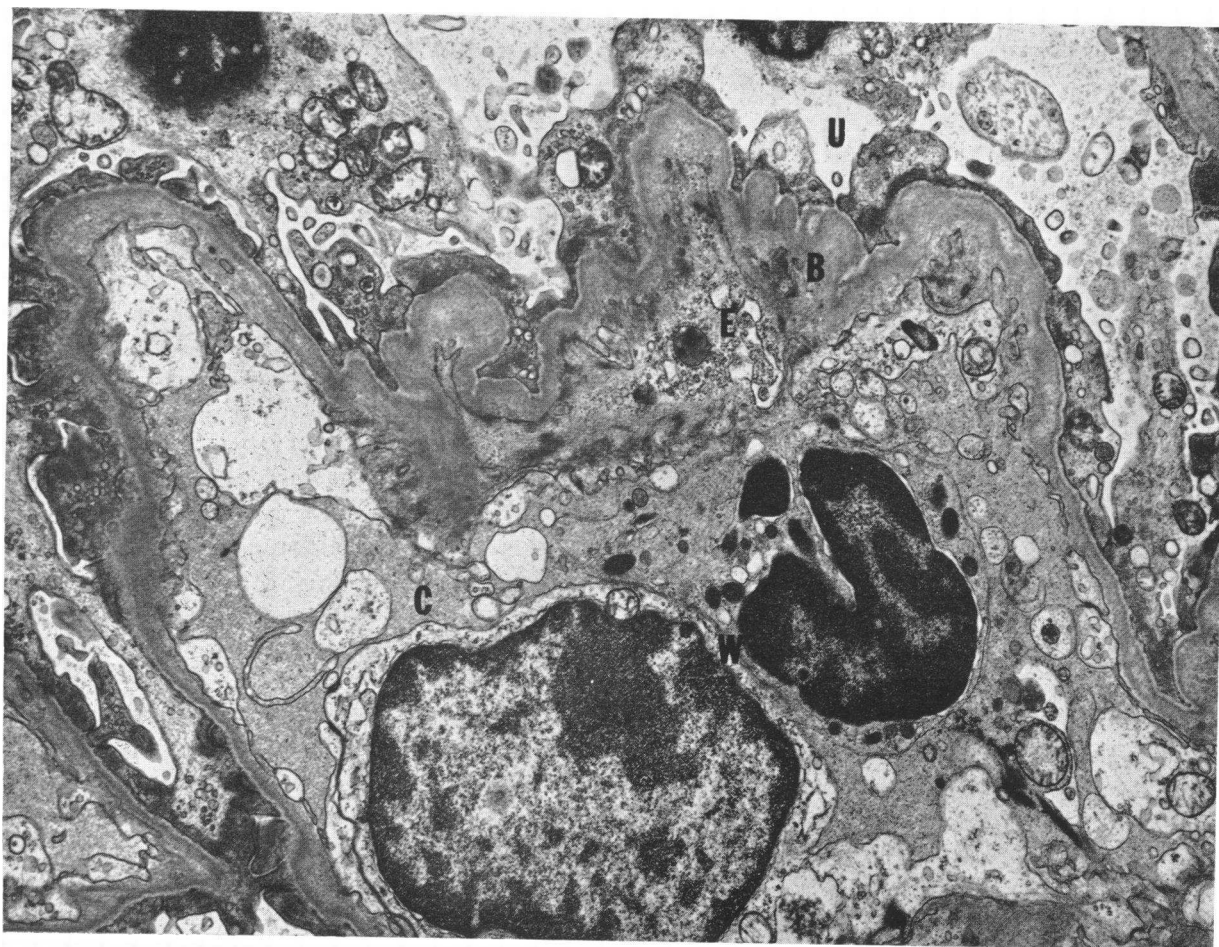


FIGURE 7 Partial focal capillary collapse in lipid nephrosis. Endothelial cytoplasm (E) is noted under collapsed and wrinkled portion of basement membrane (B). Two white blood cells (W) are noted within capillary lumen (C). U, urinary space. Case No. 1. Uranyl acetate and lead hydroxide.  $\times 11,000$ .

cellular organelles. Usually only one or two such deposits were found in any one glomerulus. Occasionally, material similar to the subendothelial deposits was noted in the capillary lumen and in one case intraluminal material appeared to be contiguous with subendothelial material through capillary endothelial fenestrations (Fig. 6).

*Focal collapse.* Focal partial collapse of glomerular capillary loops was observed from one to several times in all cases (Fig. 7). In these areas the basement membrane became undulated and wrinkled as seen in nephrosclerosis with partial glomerular ischemia. Cytoplasm, whether endothelial or mesangial could not always be determined, was occasionally noted within these areas. Deposits such as those described above were not infrequent, and probable remnants of subcellular organelles were also occasionally observed within them.

## RESULTS

*Active lipid nephrosis.* Patients we consider as having active lipid nephrosis have edema, proteinuria, hypercholesterolemia, and hypoalbuminemia. They may

also have slight microscopic hematuria and slight transient elevation of blood pressure or blood urea nitrogen. Morphologic studies show only minimal changes by light microscopy. The only consistent finding on electron microscopy is diffuse foot process fusion in untreated cases. There is no diffuse change in endothelium, mesangium, or basement membrane. This condition has also been called nil disease, foot process disease, and minimal change disease. As described in this paper, focal subendothelial deposits and focal glomerular capillary collapse may be seen by electron microscopy. There may also be focal glomerular sclerosis by light microscopy and Grishman<sup>2</sup> has recently suggested that this has prognostic significance. Thus, of 295 biopsied

<sup>2</sup> Grishman, E. Presented in discussion of lipid nephrosis and focal glomerular disease at the Symposium on Nephrotic Syndrome, American Society of Nephrology, Washington, D. C., November 1968.



patients with the nephrotic syndrome, 30 were classified as focal glomerular disease compared with 90 cases of lipid nephrosis without focal lesions. The former frequently had microhematuria, elevated blood pressure, or elevated blood urea nitrogen at onset and about 70% were steroid dependent or resistant compared to 30% in the latter group. Of the 22 cases of focal glomerular disease with follow-up, seven suffered renal failure compared to only one of 70 cases without glomerular lesions.

The cases of active lipid nephrosis in the present study all had edema, proteinuria, hypercholesterolemia, and hypoalbuminemia at the time of biopsy, although the exact figures are no longer available in a few cases. Fibrin aggregation was found in 10 of 18 intensively studied cases with active lipid nephrosis (Table I, cases 1-18). This was observed apparently unassociated with platelet aggregation in nine cases. However, platelet plus fibrin thrombi were observed in other areas of three of these. Six cases exhibited pure platelet aggregates. There was no apparent correlation with steroid therapy although no patient with fibrin plus platelet thrombus formation was known to be on such medication.

As mentioned above, one patient showed very definite adherence of the fibrin to the luminal surface of the glomerular capillary basement membrane (Fig. 3). Masses of fibrin and cells, presumably blood cells, practically obliterated the lumen in this area. This case has certain unusual features which must be mentioned. The patient is a 30 yr old male who required hospitalization after multiple bee stings at the age of 15, underwent a splenectomy for thrombocytopenic purpura at age 19, and developed arthritis at age 21. 2 yr later a diagnosis of myasthenia gravis was made. The nephrotic syndrome for which this biopsy was performed developed approximately 3 wk after the patient was bitten by an insect of unknown nature. Despite this admittedly unusual history, we have included this case because the changes seen in light microscopy were only minimal. Three other cases showed apparent adherence of the fibrin thrombus to the capillary endothelium (Fig. 2).

Nine cases also demonstrated focal dense subendothelial deposits. In four of the female cases (Nos. 10, 11, 13, and 16) similar material was noted in the capillary lumen and appeared contiguous with the subendothelial deposit in one of these (Fig. 7).

Focal capillary collapse could be observed in all cases even when no change was found by light microscopy although usually only one or two such foci were observed in any one case. It is reemphasized that these specimens were methodically scanned and that such focal lesions could easily be missed if a more random search were used.

TABLE I  
Active Lipoid Nephrosis\*

No.	Age	Sex	Dura- tion†	St.	A <sub>2</sub>	Chol	F	FP	P	D
yr										
1	4	M	4 months	+		639	+	-	+	+
2	5	M	3 yr	+		448	+	-	-	-
3	7	M	4 wk	+		478	+	-	-	-
4	7	M	5½ yr			723	+	+	-	+
5	13	M	8 wk	-	+	560	+	-	-	+
6	16	M	3 yr	-	+	430	+	+	-	+
7	17	M	2 months	+	+	1278	+	-	+	+
8	20	M	4 wk	-	+	540	+	+	+	-
9	30	M	10 days	-		350	+	-	-	-
10	4	F	1 wk	+		400	-	-	-	-
11	4	F	1 wk	+		492	-	-	+	+
12	5	F	6 months	+			-	-	-	-
13	9½	F	1½ yr	+		472	-	-	-	+
14	10	F	1½ yr	+		450	-	-	+	+
15	16	F	2 wk	-	+	532	-	-	-	-
16	17	F				374	-	-	-	+
17	42	F	3 months	-			-	+	+	-
18	67	F	1½ yr	-	+	335	-	-	-	-
Cases from files										
19	2	M	2 months	+		540	+	-	-	-
20	8	M					-	-	+	-
21	20	M	8 months				-	-	+	+
22	22	M	3 yr	+	+	700	+	-	-	+
23	10	F	2 yr	+			-	-	+	-
24	11	F	3 months	-	+	430	-	-	+	+
25	36	F			+	434	+	+	-	-

\* Abbreviations: St. = steroid therapy at time of biopsy; A<sub>2</sub> = α<sub>2</sub>-globulin elevated; Chol. = cholesterol; F = fibrin aggregate; FP = mixed fibrin-platelet aggregate; P = platelet aggregate; D = Subendothelial deposits; + = yes; - = no.

† The duration of time from appearance of first symptoms to biopsy.

Thus, 10 cases of active lipid nephrosis revealed fibrin formation, eight revealed platelet aggregation, and subendothelial deposits were found in nine. All of the patients were normotensive. Cholesterol values varied from 350 to 1278 mg/100 ml. Serum α<sub>2</sub>-globulin levels where available were consistently elevated.

A search of previously studied routine electron micrographs of 112 cases of lipid nephrosis revealed three additional examples of fibrin formation, and four of platelet aggregation (Table I, cases 19-25). One of the former and two of the latter also had subendothelial deposits. Of the total of 13 cases of fibrin formation, 11 were males ages 2-30 yr and the two females were ages 36 and 42. Fibrin formation without platelets has been found in only one female case. The eight intensively

studied cases in which fibrin was not found (although platelet aggregates were found in two) were all females. Seven varied in age from 4 to 17 yr. The remaining patient was 67 yr old.

Reexamination of micrographs of previously studied cases revealed eight additional examples of subendothelial deposits. This includes two patients in remission. The patients in whom deposits were found tended to have a longer history and had frequently been under treatment for 1 or more years before biopsy with an average of 22 months in those cases where the information was available. If only intensively studied active cases are considered, eight patients with deposits had an average history of 18 months, compared to 8 months in the nine without deposits.

*Lipoid nephrosis in remission.* Six cases of lipoid nephrosis considered to be in partial or complete remission were studied intensively as described above (Table II). These patients originally met the criteria for active lipoid nephrosis as described above but at the time of the present biopsy were free of edema, and had normal serum protein and cholesterol values. Proteinuria, if present, was much less than during the nephrotic state. In no case was fibrin noted. Subendothelial deposits were found in a 16 yr old boy and in a 4 yr old boy, both in remission on steroids for 3 yr.

*Control cases.* Table III lists the findings in the control cases. Three of six cases of membrano-proliferative glomerulonephritis revealed fibrin formation and one revealed platelet aggregation. Cholesterol values varied from 300 to 376 mg/100 ml in the four cases where the information is available.

Three of six cases of membranous nephropathy (membranous glomerulonephritis) also revealed fibrin and three revealed platelet aggregation. Cholesterol values

varied from 340 to 706 mg/100 ml in the five cases in which the information is available.

Fibrin was found in three of six cases of proliferative glomerulonephritis. The positive cases were much more severely involved by the inflammatory process. Cholesterol values are not available in these nonnephrotic patients.

TABLE III  
Control Cases\*

No.	Age	Sex	B.P.	Chol.	Light micro	F	FP	P
<i>yr</i>								
Cases with nephrotic syndrome								
Membrano-proliferative glomerulonephritis								
32	11	F	120/80	376		-	-	-
33	16	M	150/80	300		-	-	-
34	21	F				+	-	-
35	24	M	↑			+	-	+
36	30	F	150/80	325		-	-	-
37	34	F	170/90	375		+	-	-
Membranous nephropathy								
38	16	M	140/80	460		+	-	+
39	23	F	120/70	340		-	-	-
40	32	M	120/70	382		+	-	-
41	36	M	120/80	410		-	-	-
42	54	M				+	-	+
43	64	M	210/100	706		-	-	+
Cases without nephrotic syndrome								
Acute proliferative glomerulonephritis								
44	3	M			Moderate	-	-	-
45	24	M			Severe	+	+	-
46	27	F			Moderate	-	-	-
47	29	M			Severe	+	-	-
48	29	M			Moderate	-	-	-
49	40	M			Severe	+	-	-
Nephrosclerosis with hypertension								
50	23	M	280/180	320		+	-	+
51	42	M	180/120	262		+	+	-
52	43	M	180/130			-	-	-
53	52	M	↑			-	-	-
54	57	M	↑	420		-	-	-
55	69	M	140/80	170		-	-	-
Recurrent hematuria								
56	2½	M	110/64	190	NSC	-	-	-
57	5	M	110/60	180	NSC	-	-	-
58	6	F	110/70	75	NSC	-	-	-
59	7	M	110/80	150	FScI.	-	-	-
60	8	M			FScI.	-	-	-
61	24	M	135/90	500	NSC	+	-	+

TABLE II  
Lipoid Nephrosis in Partial or Complete Remission\*

Case No.	Age	Sex	Dura- tion†	B.P.	St.	Chol.	F	FP	P	D
<i>yr</i>										
26	4½	M	3 yr	100/60	+	162	-	-	-	+
27	6	M	3 yr	95/40	+	225	-	-	-	-
28	7½	M	3 yr	110/75	+	120	-	-	-	-
29	9	M	3 yr	90/60	+		-	-	-	-
30	11	F	5 yr	110/80	+	150	-	-	-	-
31	16	M	3 yr	118/68			-	-	-	+

\* Abbreviations: B.P. = blood pressure; St. = steroid therapy at time of biopsy; Chol. = cholesterol; F = fibrin aggregate; FP = mixed fibrin-platelet aggregate; P = platelet aggregate; D = subendothelial deposits; + = yes; - = no.

† The duration of time from appearance of first symptoms to biopsy.

\* Abbreviations: B.P. = blood pressure; Chol. = cholesterol; F = fibrin aggregate; FP = mixed fibrin-platelet aggregate; P = platelet aggregate; ↑ = elevated; + = yes; - = no; NSC = no significant change; FScI. = focal sclerosis.

Fibrin and platelet aggregates were found in two of six patients with nephrosclerosis and hypertension. One of these had severe hypertension and a serum cholesterol value of 320 mg/100 ml. The other patient had moderate hypertension and a serum cholesterol of 262 mg/100 ml. A platelet aggregate was also found in a third patient with moderate hypertension but whose serum cholesterol value is not available.

One out of six cases of benign recurrent hematuria revealed fibrin formation. Two of these cases showed minimal focal glomerular lesions by light microscopy. The others revealed no significant changes. The positive patient, a 24 yr old male, had negative findings on light microscopy, but a serum cholesterol of 500 mg/100 ml. The five negative patients were from 2 to 8 yr of age and none of the four patients tested had a serum cholesterol over 190 mg/100 ml.

*Immunofluorescence.* Nine cases of active lipid nephrosis, five males (Nos. 4, 5, 7, 8, and 9) and four females (Nos. 12, 15, 17 and 25) were examined by immunofluorescence. All gave negative results with anti- $\beta$ 1a/1c and anti-gamma globulin. Cases 7, 9, and 25 gave moderately positive focal fluorescence of the endothelial aspect of the glomerular basement membrane in single capillary loops with antifibrin and antifibrinogen. Case 15 gave moderately to strongly positive diffuse staining of the same area with those stains. The remaining cases gave negative results.

Control immunofluorescence studies are available only in four cases of membrano-proliferative glomerulonephritis. Three cases (Nos. 32, 36, and 37) gave moderately to strongly positive staining of glomerular basement membrane and mesangium with anti- $\beta$ 1a/1c and two of these (Nos. 36 and 37) were moderately positive with anti-gamma globulin. However, all four cases were moderately to strongly positive with antifibrin and three (Nos. 32, 34, and 37) were similarly positive with antifibrinogen. This fluorescence was much more diffuse than in the positive cases of lipid nephrosis.

## DISCUSSION

The finding of fibrin in inflammatory conditions such as glomerulonephritis is not at all unexpected, nor is its infrequency surprising in such bland conditions as benign recurrent hematuria and mild nephrosclerosis. However, the significance of finding intraglomerular fibrin in lipid nephrosis is difficult to evaluate. We really cannot explain what appears to be a higher incidence in males. This could be due to coincidence, sampling error, or to some more fundamental cause. Could it be that for some unknown reason fibrin formation under these conditions is different in females and that the intraluminal material seen in four female patients

is actually produced during the coagulation process? Since this material has little structure it is more difficult to locate than the more dense and characteristically structured fibrin. Our immunofluorescence studies show poor correlation with our electron microscopic findings of fibrin. This is felt to be due in part to the fact that both fibrin and intraluminal material described above are frequently present in very small amounts and therefore may easily be missed when studied by fluorescent techniques. It is interesting, however, that the only case (No. 16) showed intraluminal material by electron microscopy and which was also studied by immunofluorescence gave positive results.

As was noted above, the serum  $\alpha_2$ -globulin and the cholesterol were invariably elevated in those cases of the nephrotic syndrome in which it was determined. When fibrin was found in noninflammatory, nonnephrotic conditions, the serum cholesterol was also usually elevated. It has been observed by others that the antifibrinolytic effect of serum resides largely with the  $\alpha_2$ -globulin fraction (7). It has further been shown that the kidney plays a role in the regulation of fibrinolysis (8-10) and that this system can become impaired with renal damage (11). Antifibrinolysin studies are unfortunately unavailable in our cases. However, it is possible that the increased finding of fibrin is related both to the elevated blood lipids and to any renal disability which may be present because of the underlying disease process. On the other hand, the literature offers considerable experimental evidence that the coagulation process can cause glomerular damage and immunofluorescent and biochemical observations suggest that similar processes operate in human disease (2, 3). It has been suggested by some investigators that phagocytosis of fibrin and fibrinogen derivatives such as incompletely polymerized fibrin caused swelling and proliferation of intercapillary and epithelial cells (12) and there is also evidence that the process in toxemia is similar (13).

It is known that platelet aggregation is enhanced by fibrin polymerization (14), fibrin split products (15), and fatty acids (16, 17). Aggregation of platelets by adenosine diphosphate has been found to be enhanced if fibrinogen levels are low, even if in the low normal range (18). Thus, the finding of platelet aggregates in the cases presented here could reflect transformation of fibrinogen to fibrin rather than merely the elevated blood lipids. In any event, some activation of the coagulation process would seem to be involved.

The presence of subendothelial deposits is equally intriguing and difficult to evaluate. The finding of apparently identical material in the vascular lumen in three cases with possible direct contiguity with a subendothelial deposit in one case suggests that the material arrives via the blood stream. One possibility, as



suggested above, is that this material derives from the coagulation process. It is also possible that these deposits are related to deposits of IgG or  $\beta$ 1c globulin which has been demonstrated by immunofluorescence by Drummond, Michael, Good, and Vernier (19) in a small group of patients (their group II) who were similar to our patients with lipid nephrosis and most of whom showed minimal changes by light microscopy. However, all of the nine cases we studied by immunofluorescence were negative for these proteins.

Whether these deposits may represent part of the process of removal of fibrin or an aggregate of antigen-antibody complex cannot be determined at this time, but the general tendency for them to be present in cases of longer duration would suggest that they are related to the disease process in lipid nephrosis. Other available evidence presented above, although inconclusive, points to the coagulation process as a likely source. Unfortunately, more extensive studies are required to elucidate this problem.

Both hyaline glomerular capillary thrombi and focal glomerular sclerosis have been seen in lipid nephrosis. Although proof is lacking, the findings presented above are compatible with the concept that in lipid nephrosis the formation of small fibrin aggregates adherent to glomerular capillary walls could lead to focal capillary collapse and eventual obliteration of the capillary lumen in those areas. Extension of this process could lead to progressive obliteration of glomeruli.

#### ACKNOWLEDGMENTS

We are indebted to Mrs. Carolyn Schwarz, Miss Dolores Krause, Mrs. Lettie Van Cleef, Mr. Frank Colonna, Mr. Kenneth Walker, Mr. Norman Katz, Mrs. Carol Shooer, and Mrs. Lynda Gittings for technical assistance, to Mrs. Evelyn Johansson for assistance in preparation of the manuscript, and to Doctor Edward C. Zaino for permission to study cases 8 and 13.

Supported in part by Research Grant AM-00918 from the National Institute of Arthritis and Metabolic Diseases, U. S. Public Health Service.

#### REFERENCES

1. Taub, R. N., F. Rodriguez-Erdmann, and W. Dame-scheck. 1964. Intravascular coagulation, the Schwartzman reaction and the pathogenesis of T.T.P. (thrombotic thrombocytopenic purpura). *Blood* 24: 775.
2. Vassalli, P., and R. T. McCluskey. 1965. The coagulation process and glomerular disease. *Amer. J. Med.* 39: 179.
3. McCluskey, R. T., P. Vassalli, G. Gallo, and D. S. Baldwin. 1966. An immunofluorescent study of pathogenic mechanisms in glomerular diseases. *N. Engl. J. Med.* 274: 695.
4. Kincaid-Smith, P., B. M. Saker, and K. F. Fairley. 1968. Anticoagulants in "irreversible" acute renal failure. *Lancet.* 2: 1360.
5. Lieberman, E., E. Heuser, G. S. Gilchrist, G. N. Donnell, and B. H. Landing. 1968. Thrombosis, nephrosis, and corticosteroid therapy. *J. Pediat.* 73: 320.
6. Todd, M. E., J. Borrero, and E. L. Becker. 1968. Renal disease and coagulation alterations. *Ann. Intern. Med.* 68: 1183. (Abstr.)
7. Mann, R. D., S. Cotton, and D. Jackson. 1966. Antiplasmin activity of electrophoretically separated human serum fractions. *J. Clin. Pathol.* 19: 185.
8. Januszko, T., M. Furman, and K. Buluck. 1966. The kidneys and the liver as organs regulating the fibrinolytic system of the circulating blood. *Thromb. Diath. Haemorrh.* 15: 554.
9. Menon, I. S., H. A. Dewar, and D. J. Newell. 1968. Role of the kidney in fibrinolytic activity of blood. *Lancet.* 1: 785.
10. Worowski, K., A. Poplawski, J. Kochanska, and S. Niewiarowski. 1965. Effect of kidney elimination on fibrinolysis and clotting factors in dog blood plasma. *Bull. Acad. Pol. Sci. Ser. Sci. Biol.* 13: 683.
11. Niewiarowski, S., J. Prokopowicz, A. Poplawski, and K. Worowski. 1964. Inhibition of dog fibrinolytic system in experimental tubular necrosis of kidney. *Experientia.* 20: 101.
12. Vassalli, P., and R. T. McCluskey. 1964. The pathogenic role of the coagulation process in rabbit masugi nephritis. *Amer. J. Pathol.* 45: 653.
13. Morris, R. H., P. Vassalli, and R. T. McCluskey. 1968. Immunofluorescent studies of renal biopsies in pregnancy. *Clin. Obstet. Gynecol.* 11: 522.
14. Solum, N. O. 1966. Platelet aggregation during fibrin polymerization. *Scand. J. Clin. Lab. Invest.* 18: 577.
15. Barnhart, M. I., D. C. Cress, R. L. Henry, and J. M. Riddle. 1967. Influence of fibrinogen split products on platelets. *Thromb. Diath. Haemorrh.* 17: 78.
16. Connor, W. E., J. C. Hoak, and E. D. Warner. 1965. The effects of fatty acids on blood coagulation and thrombosis. *Thromb. Diath. Haemorrh.* 17 (Suppl.): 89.
17. Pilgeram, L. O., and L. R. Pickart. 1968. Control of fibrinogen biosynthesis: the role of free fatty acid. *J. Atheroscler. Res.* 8: 155.
18. Bloom, A. L., and E. P. Evans. 1969. Plasma fibrinogen and the aggregation of platelets by adenosine diphosphate. *Lancet.* 1: 349.
19. Drummond, K. N., A. F. Michael, R. A. Good, and R. L. Vernier. 1966. The nephrotic syndrome of childhood: immunologic, clinical, and pathologic correlations. *J. Clin. Invest.* 45: 620.