

The nephrotic syndrome of childhood: immunologic, clinical, and pathologic correlations.

K N Drummond, ... , R A Good, R L Vernier

J Clin Invest. 1966;[45\(4\)](#):620-630. <https://doi.org/10.1172/JCI105376>.

Research Article

Find the latest version:

<https://jci.me/105376/pdf>



The Nephrotic Syndrome of Childhood: Immunologic, Clinical, and Pathologic Correlations *

KEITH N. DRUMMOND,† ALFRED F. MICHAEL,‡ ROBERT A. GOOD,§ AND
ROBERT L. VERNIER ||

(From the Pediatric Research Laboratories of the Variety Club Heart Hospital, and the
Department of Microbiology, University of Minnesota, Minneapolis, Minn., and
the Department of Pediatrics, McGill University, Montreal, Canada)

The role of immunologic processes in the pathogenesis of human renal disease has been the subject of investigation and discussion for over half a century. Factors interpreted as favoring an immunologic basis for some of the diffuse glomerular diseases of man include reduced serum complement levels, the presence of antikidney antibodies, and the similarity of pathologic changes in immunologically induced experimental renal disease to lesions in human glomerulonephritis. More recently, the demonstration by immunofluorescent techniques of glomerular deposition of immunoglobulins and complement in a number of these disorders has provided more compelling support for the immunologic hypothesis. The possible pathogenetic mechanisms by which immunologic processes may induce renal disease in man have been recently reviewed (2).

Most immunofluorescent studies of kidney biopsies in the nephrotic syndrome have suggested that immunoglobulin deposition along glomerular basement membranes is characteristic (3-7). Such studies have dealt predominantly with adult nephrotic patients, a group in which membranous glomerulonephritis is a frequent pathologic alter-

ation. However, even in patients with the idiopathic nephrotic syndrome, positive staining for gamma globulin and complement has been described as a characteristic finding (6). Similar observations have been made in infants with the congenital nephrotic syndrome (8, 9).

The purpose of this work was to obtain more definitive information about the significance of immunologic processes in a relatively large group of patients with the nephrotic syndrome of childhood. Our observations were carried out in 35 children with this disease. Deposition of immunoglobulin G (IgG) and beta_{1c}-globulin in glomeruli was studied by the immunofluorescent technique and correlated with light microscopic findings and with the clinical course and response to therapy. Serum complement activity was measured in 10 of these patients. We found that in children whose nephrotic syndrome is responsive to steroid therapy and whose renal pathology is minimal, immunoglobulin and complement are not demonstrable on the glomerular basement membrane, suggesting that immunologic processes may not be of pathogenetic importance in this group. However, such mechanisms do appear to be operative in many of the nephrotic children whose clinical courses and kidney lesions are indicative of severe glomerular injury.

Methods

Subjects. The patient group consisted of 35 children who were admitted to the University of Minnesota Hospitals between 1962 and 1964 with the clinical and laboratory features of the nephrotic syndrome. Patients were considered to have this disorder if they presented the following features: 1) generalized edema, with or without ascites; 2) marked proteinuria as judged by a urinary protein concentration of 1,000 mg per 100 ml or more, a 24-hour urinary protein excretion of 2 g per m² or more, or both; 3) depression of serum albumin below 2 g per 100 ml; and 4) elevation of serum cholesterol above

* Submitted for publication September 2, 1965; accepted January 3, 1966.

Aided by grants from the U. S. Public Health Service (AI-02018, HE-05662, HE-06314), the National Foundation, The American Heart Association, and the Medical Research Council of Canada (MA-1579).

Presented in part at the Annual Meeting of the Society for Pediatric Research, Seattle, Wash., June 20, 1964 (1).

† Address requests for reprints to Dr. Keith N. Drummond, the Montreal Children's Hospital, 2300 Tupper St., Montreal 25, Quebec, Canada.

‡ Established Investigator, American Heart Association.

§ American Legion Memorial Heart Research Professor of Pediatrics and Microbiology.

|| Present address: Dept. of Pediatrics, University of California, Los Angeles, Calif.

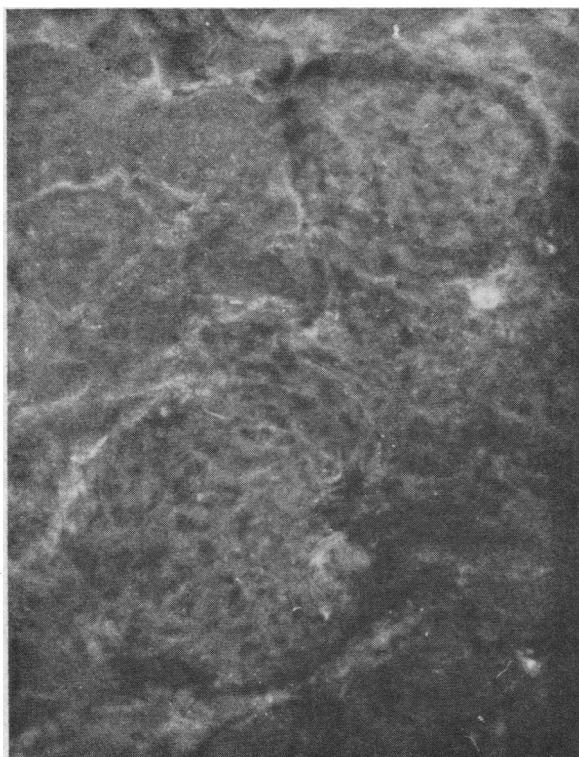


FIG. 1. NO FLUORESCENCE IS SEEN IN THESE TWO GLOMERULI FROM A PATIENT IN GROUP I, SUBGROUP A, STAINED FOR IMMUNOGLOBULIN G (IgG). ($\times 200$.)

220 mg per 100 ml. In most patients all features were present at the time of the study biopsy. However, in a few from whom biopsies were taken early in the course of an exacerbation, after onset of improvement, or after the development of chronic renal disease, not all features were present at the actual time of biopsy.

One patient had a sore throat 1 month preceding onset of the nephrotic syndrome and showed an antistreptolysin O titer of 500 Todd U at the time of biopsy. The other patients had no clinical or laboratory evidence of preceding streptococcal infection. None had gross hematuria, and in none was the diagnosis of acute post-streptococcal glomerulonephritis considered likely.

Two patients with the nephrotic syndrome developing in the course of systemic lupus erythematosus were not included in the study. Laboratory, clinical, and pathologic findings were considered adequate to exclude this diagnosis in the remaining patients.

In one patient it was possible to relate the development of the nephrotic syndrome to preceding Tridione¹ administration. In the others, a distinctive disease process or known precipitating cause was not apparent.

Tissue preparation. Renal tissue was obtained by percutaneous biopsy or at autopsy and was divided into two pieces. One portion was fixed in 10% buffered formalin

¹ Trimethadione, Abbott Laboratories, North Chicago, Ill.

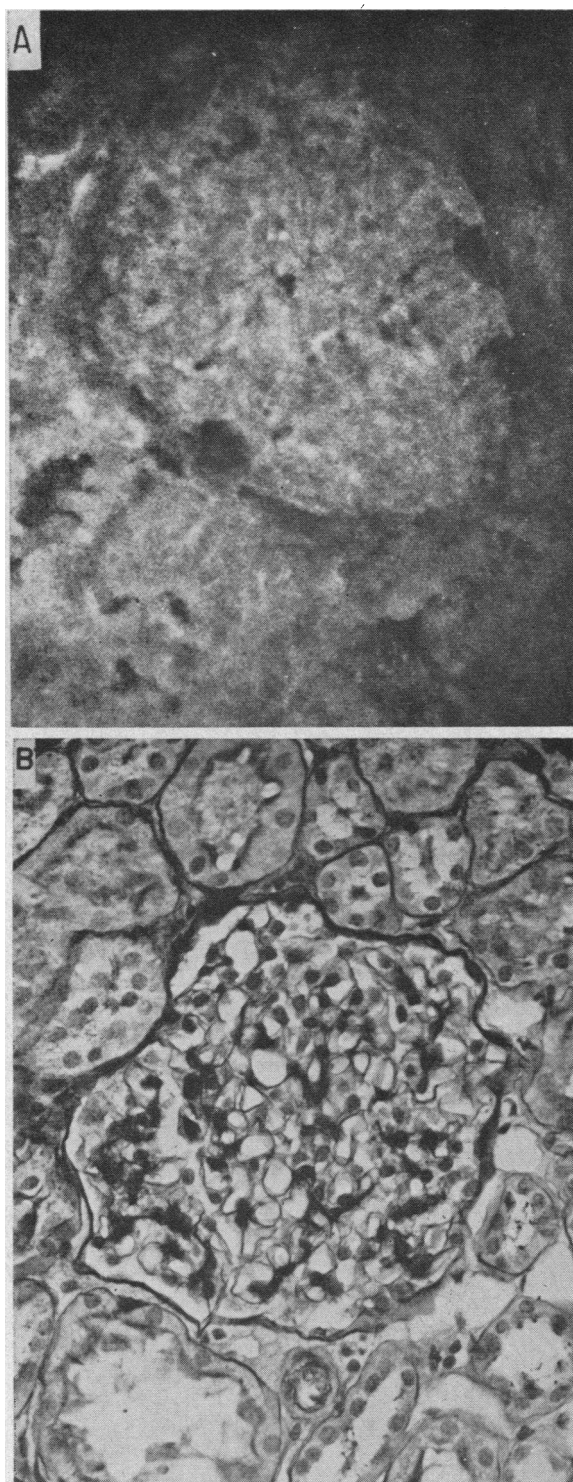


FIG. 2. A) THIS GLOMERULUS FROM ANOTHER PATIENT IN GROUP I, SUBGROUP A, STAINED FOR β_{1c} -GLOBULIN SHOWS NO FLUORESCENCE. ($\times 400$.) B) LIGHT MICROSCOPY OF A GLOMERULUS FROM THE SAME PATIENT REVEALS NO ABNORMALITY. (PAS $\times 400$.) PAS = periodic acid Schiff stain.

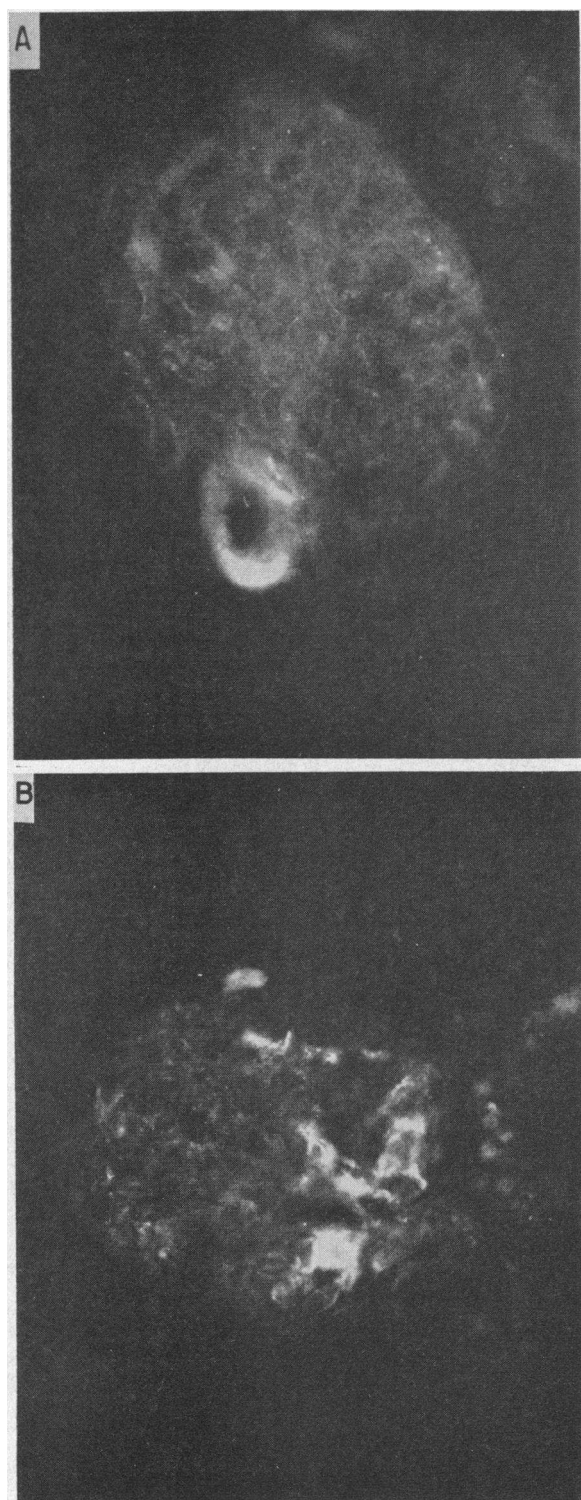


FIG. 3. A) ONLY THE REGION OF THE AFFERENT ARTERIOLE IS FLUORESCENT IN THIS GLOMERULUS FROM A PATIENT IN GROUP II, SUBGROUP D, STAINED FOR IgG. ($\times 400$.) B) ANOTHER GLOMERULUS FROM THE SAME PA-

(pH 7.35) and processed for routine pathologic examination with the periodic acid Schiff (PAS), hematoxylin and eosin (H and E), and azocarmine stains on 4- μ sections. The other piece was immediately frozen in isopentane that had been precooled to -170°C by liquid nitrogen. This tissue was kept frozen at -70°C until sectioned at 4 μ on a Lipshaw cryotome at -20°C . The tissue was stained by the direct immunofluorescent method with fluorescein isothiocyanate (FITC)-labeled antisera. Antisera were prepared in rabbits to purified human IgG,² albumin,³ and beta_{1c}-globulin,⁴ and in a goat to rabbit gamma globulin.⁵ The methods used for immunization, antisera preparation, FITC conjugation, tissue sectioning, staining, and microscopic and photographic techniques are described in another publication (11). Antisera to human albumin and to rabbit gamma globulin were used as control stains for the antisera to human IgG and beta_{1c}-globulin. In no instance was positive glomerular staining noted with these control stains. Specificity of IgG and beta_{1c}-globulin fluorescence was established by using an inhibition test in which the section was pretreated with unlabeled antisera. These sections were then compared with those in which the inhibition step with unlabeled antisera had been omitted. Reduction in fluorescence in the inhibited sections was interpreted as indicating specificity for IgG or beta_{1c}-globulin fluorescence and was uniformly seen in all sections so tested. The tissues were examined independently by two investigators using a Zeiss fluorescent microscope.

Serum complement activity was determined by the method of Kabat and Mayer (12)⁶ in 10 of the patients within 1 week of the biopsy. In this method the level of complement activity is expressed as the titer of serum causing 50% hemolysis of a test suspension of sensitized sheep erythrocytes. Control values in our laboratory are 45 ± 8 (mean ± 1 SD).

Sections for routine light microscopy were examined independently by at least two of the authors and by a pathologist who had no knowledge of the clinical status

² Isolated by DEAE chromatography; IgG was also obtained from Immunology, Inc., Chicago, Ill.

³ Normal human serum albumin, Cutter Laboratories, Berkeley, Calif.

⁴ Prepared according to the method of Müller-Eberhard, Nilsson, and Aronsson (10).

⁵ Rabbit gamma globulin, Cohn Fraction II, Nutritional Biochemicals Corp., Cleveland, Ohio.

⁶ These determinations were performed by Dr. Henry Gewurz of the Dept. of Pediatrics, University of Minnesota.

TIENT STAINED FOR BETA_{1c}-GLOBULIN. This glomerulus shows more extensive fluorescence, which arises in the region of the afferent and efferent arterioles and appears to extend into the stalk or mesangium. The exact localization of the fluorescence cannot be determined; however, it is clearly not along the capillary basement membranes. ($\times 400$.)

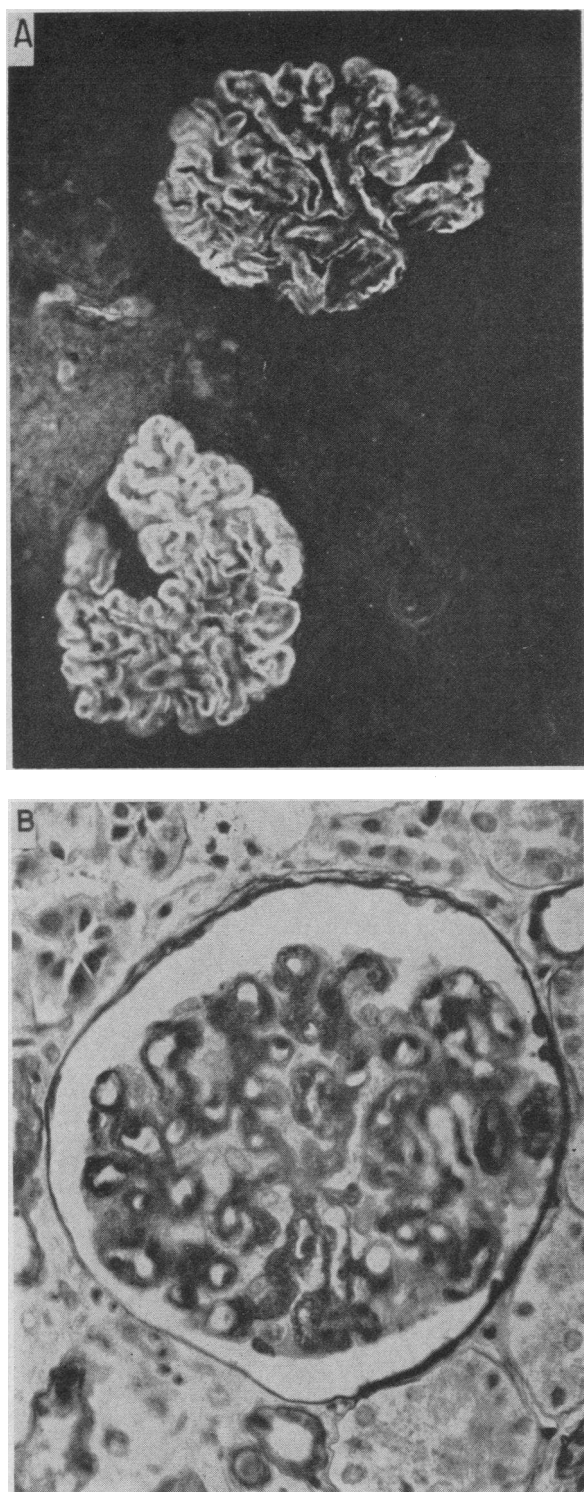


FIG. 4. A) TWO GLOMERULI FROM THE PATIENT IN GROUP III WITH MEMBRANOUS GLOMERULONEPHRITIS SHOWING MARKED DEPOSITION OF IgG ALONG THE CAPILLARY BASEMENT MEMBRANES. ($\times 250$.) B) DIFFUSE

of the patient.⁷ An over-all assessment of the degree of abnormality was made; in addition, the specific abnormal features were graded on a scale ranging from 1+ (minimal) to 4+ (marked).

Results

Immunofluorescent studies

On the basis of the immunofluorescent findings it was possible to separate the patients into three groups. The first group (I) consisted of 22 patients whose renal glomeruli showed no deposition of IgG or β_{2} -globulin (Figures 1, 2A).

In the second group (II) were seven patients whose glomeruli showed a coarse focal or basal distribution of IgG or β_{2} -globulin. Deposition of these proteins along glomerular basement membranes was negligible. Occasionally the fluorescence was confined to the stalk or mesangial region or to the basal area near the afferent or efferent arterioles. In some instances the fluorescence appeared to be within capillary lumina or in Bowman's space. Often the area of fluorescence was only one-tenth to one-twentieth of the glomerular surface area, and different glomeruli from a given specimen were involved to a variable degree (Figure 3, A and B).

The third group (III) comprised six patients whose biopsies showed extensive glomerular deposition of both IgG and β_{2} -globulin. The deposition was usually linear and appeared to be on the basement membrane, although in some cases nodular excrescences and lumpy deposits along the basement membrane were also observed. Regardless of the predominant pattern it was clear that the fluorescence was related to the basement membranes of the capillary loops of the glomeruli (Figure 4A).

Clinical course and routine laboratory studies (Tables I and II)

Group I. These 22 patients showing no glomerular fluorescence could be separated into two groups, A and B, on the basis of their responses to

⁷ We are indebted to Dr. Barbara Burke of the Departments of Pediatrics and Pathology, University of Minnesota, for her assistance in this evaluation.

THICKENING OF THE CAPILLARY BASEMENT MEMBRANES IS SEEN IN THE LIGHT MICROSCOPIC STUDY OF THE SAME PATIENT. (PAS $\times 400$.)

TABLE I
 Clinical features and laboratory

Group	Patient	Sex	Age at onset†		Age at biopsy		No. of preceding episodes	Clinical status at biopsy‡
			years	months	years	months		
IA	1	M	6	3	6	4	0	1+ edema
	2	M	3	6	10	1	1	4+ edema, ascites
	3	F	5	5	8	1	4	1+ edema, ascites
	4	M	5	2	5	3	0	1+ edema
	5	M	4		11	8	8	1+ edema, ascites
	6	M	5		5	1	0	3+ edema, ascites
	7	M	1	8	17	5	8	1+ edema
	8	M	2	6	5	10	7	1+ edema
	9	M	2		2	6	2	3+ edema, ascites
	10	M	1	6	10	5	18	3+ edema, ascites
	11	F	3		8	1	3	No edema
	12	M	1	3	4	10	1	No edema
	13	M	1	6	6	10	8	No edema
	14	F	14	8	14	9	0	1+ edema
	15	M	8	4	8	6	0	3+ edema
	16	M	2	2	2	3	0	2+ edema, ascites
IB	17	M	3	1	3	3	0	1+ edema
	18	M		5		6	0	4+ edema, ascites
	19	M	1	1	1	10	0	4+ edema, ascites
	20	M	1	1	1	3	0	4+ edema, ascites
	21	F	5	3	13	5	7	3+ edema, ascites
	22	F	3		6	3	6	2+ edema, anemia, azotemia, hypertension
IIC	23	F	2	10	5	7	1	No edema
	24	F	2		8	8	9	1+ edema, ascites
	25	M	9	7	9	10	1	3+ edema, ascites
	26	M	5	8	6	5	1	1+ edema
IID	27	F	14		14	4	0	1+ edema
	28	F	2	10	2	11	0	Tridione for 1 year 4+ edema, ascites
	29	M	7	8	7	10	0	3+ edema, ascites
III	30	F	12	2	12	3	0	3+ edema, ascites
	31	F	11	3	11	4	0	1+ edema
	32	M	5	6	5	7	0	3+ edema, ascites
	33	M	12		20		8	2+ edema, uremia, anemia
	34	M	7	10	9	1	2	Hypertension—no edema
	35	F	3		6	8	3	1+ edema, ascites, hypertension

* Abbreviations: BUN = blood urea nitrogen, C_{cr} = creatinine clearance.

† The age at which the first episode of the nephrotic syndrome occurred.

‡ The degree of edema and ascites has been graded from 1+ (minimal) to 4+ (marked).

§ C_{H₅₀} represents the titer of serum that will cause 50% lysis of a test suspension of sensitized sheep erythrocytes. Normal control values in our laboratory are 45 ± 8 (mean ± 1 SD).

steroid therapy. In this and the subsequent groups patients were considered to have responded to steroid therapy or to have had cessation of proteinuria if the qualitative test for urinary protein was negative or if the excretion of protein was less than 100 mg per m² per 24 hours. Patients were considered resistant to steroid therapy if the features of the nephrotic syndrome, as described earlier,

persisted after 4 to 6 weeks of treatment (prednisone, 60 mg per m² per day).

Subgroup A. The 16 patients in this subgroup were in most respects typical of children with the idiopathic nephrotic syndrome. Although the age of onset ranged from 1 year 3 months to 14 years 8 months, in only three instances was it over 6 years. Ten of the patients had had previous epi-

TABLE I
data at time of study biopsy*

Serum proteins		Serum choles- terol	Urinary protein	BUN		Ccr	C'H ₂ O ₂	Response
Albumin	Globulin							
g/100 ml		mg/100 ml		g/24 hours	mg/100 ml	L/24 hours/ 1.73 m ²		
1.1	3.4	542		3.2	7			+
0.7	3.2	756	4+¶	3.5		110	40	+
0.7	3.0	528	3+	2.1	12	125		+
0.7	2.9	570		1.7	18	131		+
0.9	2.9	476	4+	19.0	8	150		+
0.7	3.2	620	3+	1.3	16			+
		247	3+	2.8	8	154		+
1.0	3.7	409	4+	3.6	13	177		+
0.8	2.7	414	4+	1.1	14			+
1.8	2.7	337	3+	6.0				+
1.7	2.8	406	4+	2.2	11	178	42	+
2.6	2.5	227	4+	2.4	15		38	+
2.7	3.0	177	2+	0.4	12	136		+
1.5	2.9	498		20.0	16	129		+
0.5	3.7	487		3.8	8	200		+
0.4	3.0	353	1+	2.5	13	107	43	+
0.8	2.4	378	3+	1.9	17	169	33	—
0.9	2.9	264	4+	5.0	26	48	29	—
0.3	3.8	642	4+	8.0	12			—**
0.2	2.1	355	4+	17.0	58			—**
0.6	2.9	542	4+	5.7	7	156		—
0.9	3.5	722	2+	6.0	226			—**
2.1	3.3	96	1+	0.3				+
0.5	3.3	375	3+	2.7	20		33	+
0.4	2.8	532	4+		9	86		+
1.6	3.2	297	4+	1.5	9	220	34	+
1.8	2.7	406	4+	6.6	10	142		—
1.6	2.5	391		13.0	25	33		—
1.0	2.9	406	3+	5.2	20	76		—
1.0	2.2	274	3+	8.0	64	34	40	—
0.7	2.6	528	3+	2.7	75	20		—
0.5	3.4	440	4+	3.9	88			—
1.8	2.2	279	4+	2.6	190			—**
1.5	2.3	357	4+	6.4	21	87	14	—
1.6	1.9	440	3+	6.2	14	107		—

^{||} Refers to the 4- to 6-week period after onset of therapy; + = cessation of proteinuria within 1 month; — = failure to respond.

[¶] Qualitative test for urinary protein: 1+ = 30 to 100 mg per 100 ml, 2+ = 100 to 500 mg per 100 ml, 3+ = 500 to 1,000 mg per 100 ml, and 4+ = more than 1,000 mg per 100 ml.

** Deceased.

sodes of the nephrotic syndrome, and all had experienced cessation of proteinuria with previous therapy. At the time of biopsy, edema, ascites, or both, were present in all but three patients, although each of these had shown these physical findings in the past. None of the patients were receiving daily steroid therapy at the time of biopsy.

Marked proteinuria was present in all patients, and depression of the serum albumin was seen in all but one, in whom it was not measured, although during this patient's previous nephrotic episodes hypoalbuminemia was documented. Serum cholesterol values were elevated in all but one patient, who had recently responded to steroid therapy and had protein-free urine until 3 days

TABLE II
Correlation of immunofluorescent, morphologic, and clinical characteristics in 35 children with the nephrotic syndrome

Group	Deposition of IgG* and beta ₁₀ -globulin	No. of Patients	Response to steroid therapy†	Renal pathology			Serum complement levels‡	Comments	
				Normal	Minimal abnormalities	Abnormal			
I	Negative	22	A. Responsive	16	2	13	Normal	4	Patients with subsequent exacerbations have remained steroid responsive.
			B. Resistant	6	2	4	Normal	2	Three dead with renal failure.
II	Coarse, focal, stalk, or basal	7	C. Responsive	4		4	Normal	2	No clinical or laboratory differences from group IA.
			D. Resistant	3		2	1		Tridione§ administration preceding nephrotic syndrome in one patient.
III	Basement membrane	6	Resistant	6		6	Normal Low	1 1	One dead with renal failure.

* Immunoglobulin G.

† Refers to the 4- to 16-week period after onset of therapy. A, B, C, and D are subgroups.

‡ All serum complement levels were obtained within 7, and in most instances within 4, days of study biopsy.

§ Trimethadione.

|| Greater than 2 SD below normal control values.

before biopsy. Normal values for creatinine clearance were found in the 11 patients in whom it was determined. These 16 patients were characterized by the responsiveness of their nephrotic syndrome to steroid therapy. Within 20 days of initiating daily steroid therapy (prednisone, 60 mg per m² per day) all experienced cessation of proteinuria, and when edema was present a diuresis occurred. In those patients who have had subsequent exacerbations a continuing responsiveness to steroid therapy has been noted.

Subgroup B. The second group of patients with no glomerular fluorescence consisted of six patients who failed to respond to steroid therapy. One patient was only 5, and two were only 13, months of age when the nephrotic syndrome was diagnosed; otherwise, the clinical features that these children presented did not distinguish them from those of subgroup A. The laboratory studies in these six patients revealed essentially the same features as seen in those of subgroup A, except that three patients had evidence of glomerular insufficiency, as indicated by elevation of the blood urea nitrogen, reduced creatinine clearance, or both.

These patients were resistant to what were considered adequate trials of steroid therapy—prednisone, 60 mg per m² per day for 1 to 2 months. In three patients, death ultimately resulted from the renal disease. In the others, persistent proteinuria and other clinical and laboratory findings indicated continued active renal disease.

Group II. This group of seven patients was

characterized by a coarse focal pattern of glomerular IgG and beta₁₀-globulin deposition. These patients could also be subdivided into two subgroups (C and D) on the basis of their responses to steroid therapy.

Subgroup C. This consisted of four patients who had experienced at least one previous episode of the nephrotic syndrome from which they had recovered with cessation of proteinuria. On the basis of their clinical and routine laboratory findings and their favorable responses to steroid therapy, it was not possible to separate these patients from those of Group I (subgroup A) who responded to steroid therapy.

Subgroup D. This subgroup consisted of three patients who failed to respond to steroid therapy. One had taken Tridione as treatment for seizures in the year preceding the clinical onset of the nephrotic syndrome. Two had reduction of creatinine clearance and elevation of blood urea nitrogen at the time of the study. Otherwise, these patients were not separable on the basis of their clinical and laboratory findings from the other patients of groups I and II.

Group III. This group of six nephrotic patients showing glomerular basement membrane deposition of IgG and beta₁₀-globulin differed in several respects from the patients in groups I and II. Their average age was higher (three patients were over 11 years old at the time of onset), and in general their clinical and laboratory findings indicated more severe disease than in the patients of groups I and II. Each patient showed microscopic he-

maturia, five had reduction in glomerular filtration rate, several were hypertensive, and one who has since died was in advanced renal insufficiency with uremic pericarditis. None responded to the usual courses of steroid therapy.

Renal pathology of group I (Figure 2B)

Subgroup A. The renal tissue in two of the patients showed no abnormality. In one, although a suitable specimen was obtained for immunofluorescent study, no glomeruli were present in the routine pathologic preparation. Minimal abnormalities were seen in the other 13, including focal glomerular hypercellularity, segmentation of the glomerular tuft, prominence or proliferation of the mesangial or stalk region, focal thickening of the glomerular basement membranes, foci of interstitial calcium deposition, and tubular dilatation or atrophy. Six patients showed infrequent hyalinized glomeruli. These abnormalities were not striking; when judged on a scale of severity from 1+ (minimal) to 4+ (marked), the great majority were considered to be 1+ and none were worse than 2+.

Subgroup B. By contrast, of the six patients with no glomerular fluorescence who resisted steroid therapy, four showed clearly abnormal renal tissue. In each of these patients there was marked mesangial or stalk proliferation. In addition, focal glomerular scarring, interstitial fibrosis, hyalinized glomeruli, and tubular dilatation were seen in some of them. Two showed minimal abnormalities similar in type and severity to those seen in patients who responded to steroid therapy.

Renal pathology of group II

Renal abnormalities in this group were similar to those of group I. In each of the patients who responded to steroid therapy (subgroup C) only minimal abnormalities, indistinguishable from those of group I, subgroup A, were seen. Of the steroid resistant patients (subgroup D), two had minimal abnormalities, and one showed clearly abnormal renal tissue with epithelial crescents and capsular adhesions.

Renal pathology of group III

All patients in this group showed severe pathologic changes. In three, the lesions of proliferative subacute glomerulonephritis were found. In

two the lesions, although as severe, were more chronic, in that scarring was more pronounced and basement membrane thickening more widespread; these changes are compatible with the pathologic diagnosis of chronic glomerulonephritis. In one patient, the changes were those of a diffuse membranous glomerulonephritis (Figure 4B), a relatively common pathologic finding in adults with the nephrotic syndrome (13), but uncommon in nephrotic children.

Serum complement levels. Each of the eight values obtained from the patients in group I and II fell within normal limits; in group III one value was normal and one was low.

Discussion

These data suggest that it is possible, on the basis of immunopathologic studies, to delineate two groups of children with nephrotic syndrome. In one, comprising the majority of children with nephrosis, no evidence that immunologic mechanisms are operative was obtained with the methods used; in the other, immunologic mechanisms are probably of pathogenetic importance. The latter group, represented by our group III, was separable on the basis of clinical, laboratory, or pathologic findings from patients of groups I and II. The diagnoses include membranous glomerulonephritis [or membranous nephrosis of Churg and associates (13)] and subacute and chronic glomerulonephritis. Deposition of IgG and β_{1C} -globulin was seen along the glomerular basement membranes. These patients all failed to respond to conventional doses of corticosteroids, but several did respond to subsequent large doses of immunosuppressive agents, among them prednisone (14). Group III constitutes only a relatively small proportion of children with the nephrotic syndrome. However, since the nephrotic syndrome can occur as a manifestation of acute post-streptococcal glomerulonephritis (15), and since recent studies have established that immunologic mechanisms are operative in this disease (11, 16, 17), patients developing the nephrotic syndrome in the course of this disease could be included in this group.

Patients in groups I and II satisfy the clinical and pathologic criteria of idiopathic nephrotic syndrome of childhood. In none of these patients was IgG or β_{1C} -globulin detected along the glomerular basement membrane. In group I all glo-

meruli examined were completely negative, whereas in group II there were focal glomerular deposits of these immunoproteins. These appeared to lie within the mesangium, at the base of the glomerulus in the region of the afferent or efferent arterioles, within capillary lumina, or within Bowman's space. The significance of these immune deposits is not clear; however, we are inclined to interpret them as secondary to the proteinuria and not of primary pathogenetic significance since they are not localized in the glomerular membranes at the site of the functional lesion. Further study is necessary to clarify these relationships, but certainly the quantity and distribution of the immunoglobulin and complement deposits in group II clearly distinguish them from those of group III, which involved most of the glomerular surface of all the glomeruli examined and were located predominantly along the capillary basement membrane.

In view of previously published reports of glomerular immunoprotein deposition as a characteristic finding in the idiopathic nephrotic syndrome (3-7), it is important to attempt reconciliation of such observations with the results of the present study. First, most of these reports have dealt with adults. In adults, membranous glomerulonephritis [or membranous nephrosis (13)] is a common pathologic finding. By contrast, children with nephrosis rarely have diffuse thickening of the basement membrane (18). In our one patient with membranous glomerulonephritis, deposition of IgG and β_{2} -globulin was found on the glomerular basement membranes. Secondly, at low intensities of fluorescence, subjective and technical factors become more important; we may be underinterpreting, or others overinterpreting, the results obtained. The question is a significant one, nevertheless, and here certain observations are pertinent. In patients with early disseminated lupus erythematosus in whom renal disease is not detectable by clinical and laboratory evaluation, minimal deposits of IgG and β_{2} -globulin are readily detectable along glomerular basement membranes (19). In patients with acute poststreptococcal glomerulonephritis showing minimal proteinuria, deposits of these immunoproteins are easily found along capillary basement membranes (11). When massive proteinuria occurs in these diseases, extensive deposition of IgG and β_{2} -globulin is always present along the glo-

merular basement membranes. Lupus nephritis and acute poststreptococcal glomerulonephritis are considered the prototypes of human renal diseases that have an immunologic basis. It seems extremely unlikely that immunoprotein deposits on basement membranes large enough to be of pathogenetic importance in the development of massive proteinuria of the children of groups I and II are escaping detection by the techniques employed in this study. Moreover, in immunologically induced experimental renal disease in animals [nephrotoxic serum nephritis (20), antigen-antibody complex nephritis (21), and the "autoimmune" model of Heymann (22, 23)], renal damage sufficient to result in proteinuria is associated with readily detectable deposits of immunoproteins on glomerular membranes.

Of particular interest was the failure to demonstrate IgG and β_{2} -globulin in the glomeruli of four patients in group I whose renal pathologic changes were moderate to severe. Their clinical and laboratory features did not distinguish them from the other patients with the idiopathic nephrotic syndrome; however, they proved resistant to steroid therapy. This absence of immune globulin deposition despite significant renal pathology suggests that immune globulin deposition is not simply a secondary phenomenon that occurs when glomerular damage is severe. Conversely, as mentioned earlier, glomerular immune globulin deposition has been observed early in the course of disseminated lupus erythematosus in patients whose routine light microscopic examinations revealed minimal or no abnormalities (19). These observations suggest that the presence or absence of immune globulin deposition, as detected by the immunofluorescent technique, is not directly related to the severity of the pathologic changes.

Churg and associates (13) recently separated patients with the idiopathic nephrotic syndrome into two groups on the basis of light and electron microscopic findings. One exhibited minimal or no changes by light microscopy and fusion of epithelial foot processes by electron microscopy, and the other showed diffuse membranous thickening by light microscopy and numerous dense deposits along the basement membrane by electron microscopy. These distinctive findings were seen in the initial studies of the patients, and progression from lesions of the first type to those of the second was

not observed (13, 19), suggesting different pathogenetic mechanisms. Most of our patients that showed no membrane deposition of IgG and β_{10} -globulin would be classified morphologically with Churg's group that had isolated foot process lesions. The single child in our study who had diffuse membranous glomerulonephritis exhibited marked deposition of both IgG and β_{10} -globulin on the glomerular membrane.

None of the patients in groups I and II had depressed serum complement levels. Several authors have reported such depression in patients with the nephrotic syndrome (24-26). By contrast, Ellis and Walton (27) found normal values in some of their patients with "uncomplicated nephrotic syndrome," presumably the idiopathic nephrotic syndrome. West, Northway, and Davis (17) used an immunodiffusion technique to measure serum β_{10} -globulin levels and found normal values in patients with idiopathic nephrotic syndrome.

It seems unlikely from these data that immunologic mechanisms of the type thus far associated with the pathogenesis of renal disease are operative in the most common form of childhood nephrosis. Perhaps immunologic mechanisms that require gamma globulin and complement in molecular quantities not detectable by these techniques may produce the nephrotic syndrome; however, our interpretation of the observations herein reported leads us to favor a biochemical or metabolic defect that leads to episodic and potentially reversible changes in the permeability of the glomerular basement membrane as the basic abnormality in the nephrotic syndrome of childhood.

Summary

Renal tissue from 35 children with the nephrotic syndrome was studied by the immunofluorescent technique for IgG and β_{10} -globulin deposition. Findings were correlated with the clinical course and with pathologic changes seen by light microscopy.

Twenty-two children showed no deposition of either IgG or β_{10} -globulin. Most of these children had minimal renal changes by light microscopy and responded to steroid therapy. Clinically, the patients of this group corresponded to the most commonly seen form of the nephrotic syndrome of childhood.

Seven patients showed a focal type of glomerular IgG and β_{10} -globulin deposition. Although the exact localization of these deposits was not clear, they were not along capillary basement membranes. It was not possible to separate these patients clinically and pathologically from the group showing no immune deposits.

A final group of six nephrotic patients whose glomerular basement membranes showed marked deposition of IgG and β_{10} -globulin was defined. The renal pathologic changes in these children were marked, and none of them responded to steroid therapy.

Levels of serum complement activity were determined in 10 of the patients. Normal values were obtained in the patients of the first two groups.

We concluded that immunologic mechanisms of the type thus far associated with the pathogenesis of renal disease are probably not operative in the majority of children with the idiopathic nephrotic syndrome.

References

1. Drummond, K. N., A. F. Michael, Jr., R. A. Good, and R. L. Vernier. Immunopathologic studies in the nephrotic syndrome (abstract). *J. Pediat.* 1964, 65, 1114.
2. Michael, A. F., K. N. Drummond, R. L. Vernier, and R. A. Good. Immunologic basis of renal disease. *Pediat. Clin. N. Amer.* 1964, 11, 685.
3. Mellors, R. C., and L. G. Ortega. Analytical pathology. III. New observations on the pathogenesis of glomerulonephritis, lipid nephrosis, periarteritis nodosa, and secondary amyloidosis in man. *Amer. J. Path.* 1956, 32, 455.
4. Mellors, R. C., L. G. Ortega, and H. R. Holman. Role of gamma globulins in pathogenesis of renal lesions in systemic lupus erythematosus and chronic membranous glomerulonephritis, with an observation on the lupus erythematosus cell reaction. *J. exp. Med.* 1957, 106, 191.
5. Burkholder, P. M. Complement fixation in diseased tissues. I. Fixation of guinea pig complement in sections of kidney with membranous glomerulonephritis and rats injected with anti-rat kidney serum. *J. exp. Med.* 1961, 114, 605.
6. Lange, K., G. Treser, E. Wasserman, and I. Sagel. Routine immunohistology as an aid in the diagnosis and prognosis of renal diseases (abstract). *Ann. intern. Med.* 1964, 60, 738.
7. Freedman, P., J. H. Peters, and R. M. Kark. Localization of gamma-globulin in the diseased kidney. *Arch. intern. Med.* 1960, 105, 524.

8. Lange, K., M. Wachstein, E. Wasserman, F. Alptekin, and L. B. Slobody. Nephrotic syndrome in the newborn infant: an immune reaction? (abstract). *Amer. J. Dis. Child.* 1962, 104, 496.
9. Kouvalainen, K. Immunological features in the congenital nephrotic syndrome. A clinical and experimental study. *Ann. Paediat. Fenn.* 1963, 9, (suppl. 22).
10. Müller-Eberhard, H. J., U. Nilsson, and T. Aronsson. Isolation and characterization of two B₁-glycoproteins of human serum. *J. exp. Med.* 1960, 111, 201.
11. Michael, A. F., K. N. Drummond, R. A. Good, and R. L. Vernier. Acute poststreptococcal glomerulonephritis: immune deposit disease. *J. clin. Invest.* 1966, 45, 237.
12. Kabat, E. A., and M. M. Mayer. Complement and complement fixation in *Experimental Immunochimistry*, 2nd ed. Springfield, Ill., Charles C Thomas, p. 149.
13. Churg, J., E. Grishman, M. H. Goldstein, S. L. Yunis, and J. G. Porush. Idiopathic nephrotic syndrome in adults: a study and classification based on renal biopsies. *New Engl. J. Med.* 1965, 272, 165.
14. Michael, A. F., K. N. Drummond, R. L. Vernier, and R. A. Good. Immunosuppressive therapy of diffuse glomerular disease. In preparation.
15. Wilson, S. G. J., and W. Heymann. Acute glomerulonephritis with the nephrotic syndrome. *Pediatrics* 1959, 23, 874.
16. Seegal, B. C., G. A. Andres, K. C. Hsu, and J. B. Zabriskie. Studies on the pathogenesis of acute and progressive glomerulonephritis in man by immunofluorescein and immunoferritin techniques. *Fed. Proc.* 1965, 24, 100.
17. West, C. D., J. D. Northway, and N. C. Davis. Serum levels of beta₁₀ globulin, a complement component, in the nephritides, lipoid nephrosis, and other conditions. *J. clin. Invest.* 1964, 43, 1507.
18. Vernier, R. L., H. G. Worthen, and R. A. Good. The pathology of the nephrotic syndrome. *J. Pediat.* 1961, 58, 620.
19. Drummond, K. N., A. F. Michael, R. A. Good, and R. L. Vernier. Unpublished observations.
20. Hammer, D. K., and F. J. Dixon. Experimental glomerulonephritis. II. Immunologic events in the pathogenesis of nephrotoxic serum nephritis in the rat. *J. exp. Med.* 1963, 117, 1019.
21. Dixon, F. J., J. D. Feldman, and J. J. Vasquez. Experimental glomerulonephritis. The pathogenesis of a laboratory model resembling the spectrum of human glomerulonephritis. *J. exp. Med.* 1961, 113, 899.
22. Heymann, W. Further studies in experimental autoimmune renal disease of rats in *Renal Metabolism and Epidemiology of Some Renal Diseases*. Proceedings of the 15th Annual Conference on the Kidney, J. Metcalf, Ed. New York, National Kidney Foundation, 1964, pp. 217-21.
23. Okuda, R., M. H. Kaplan, F. E. Cuppage, and W. Heymann. Deposition of autologous gamma globulin in kidneys of rats with nephrotic renal disease of various etiologies. *J. Lab. clin. Med.* 1965, 66, 204.
24. Lange, K., L. Slobody, and R. Strang. Prolonged intermittent ACTH and cortisone therapy in the nephrotic syndrome; immunologic basis and results. *Pediatrics* 1955, 15, 156.
25. Wedgwood, R. J. P., and C. A. Janeway. Serum complement in children with "collagen diseases." *Pediatrics* 1953, 11, 569.
26. Fischel, E. E., and D. C. Gajdusek. Serum complement in acute glomerulonephritis and other renal diseases. *Amer. J. Med.* 1952, 12, 190.
27. Ellis, H. A., and K. W. Walton. Variations in serum complement in the nephrotic syndrome and other forms of renal disease. *Immunology* 1958, 1, 234.