

Presbyesophagus: Esophageal Motility in Nonagenarians

Konrad H. Soergel, ... , F. Frank Zboralske, John R. Amberg

J Clin Invest. 1964;43(7):1472-1479. <https://doi.org/10.1172/JCI105023>.

Research Article

Find the latest version:

<https://jci.me/105023/pdf>



Presbyesophagus: Esophageal Motility in Nonagenarians *

KONRAD H. SOERTEL,† F. FRANK ZBORALSKE,‡ AND JOHN R. AMBERG

(From the Departments of Internal Medicine and Radiology, Marquette University School of Medicine, and the Milwaukee County General Hospital, Milwaukee, Wis.)

Intraluminal manometry and cineradiography have permitted the characterization of esophageal motor activity in various pathologic states, notably achalasia, diffuse spasm, hiatus hernia, reflux esophagitis, and collagen diseases. The results of such investigations have been compared with those obtained from young or middle-aged normal subjects, without consideration of the effect of aging alone.

Changes of esophageal motor function occurring with advanced age, although alluded to in the literature (1-7), have not been systematically studied. We have investigated 15 subjects of 90 years of age and older in an attempt to find answers to the following related questions: What are the changes in esophageal function related to age alone? Does the aged esophagus simulate any of the known clinical disorders of this organ?

Methods

Fifteen individuals from 90 to 97 years of age were studied; 13 were males and 2 females. Some were convalescing hospital patients; others were receiving nursing home care. A complete medical history was obtained, and a physical examination was performed by one of the authors. Patients with gastric, esophageal, or central nervous system disease, other than senile dementia, were excluded.

Four of the subjects had a moderate degree of senile dementia with confusion and defects in recent memory; 4 subjects were bedridden. Deep tendon reflexes and the perception of pin pricks and vibration were frequently absent or impaired (Table I). Ten suffered from a number of chronic ailments common in this age group, such as diabetes and ischemic heart disease. One subject had a mild, normochromic anemia (11.4 g hemo-

globin per 100 ml) of unknown cause. No history of aspiration pneumonia was obtained. Only one subject (No. 14) had any symptoms that could be related to the esophagus (see under Discussion).

Cineradiography. Esophageal cineradiography was performed with all subjects in the supine position; in 12 subjects upright studies were also obtained. Sixty ml of barium suspension (850 g barium sulfate per 1,000 ml water) was used, and the end of swallowing was marked on the films. Subjects were examined in the right and left anterior oblique positions. No special maneuvers were employed to induce gastroesophageal reflux or the formation of a hiatus hernia. Approximately 3 minutes of esophageal activity was recorded.

Emptying was termed "delayed" when contrast material was still present in the esophageal lumen 20 seconds after the end of swallowing. In normal young adults the peristaltic wave that follows swallowing empties the esophagus in less than 15 seconds (8). Esophageal dilatation was recorded only if all 3 authors independently judged it to be present. Variations in distances between focal spot and the subject's esophagus did not permit objective measurement of the esophageal diameter.

Motility studies. Esophageal pressures were registered with a standard recording system: 3 open-tipped, water-filled, polyvinyl tubes of 1.8 mm internal diameter, fused longitudinally, with their tips 5 cm apart, were connected to Sanborn transducers (model 267). Recordings were made on a 4-channel direct writing Sanborn instrument. The transducers were leveled at 10 cm above the table with the patient lying supine. Pressures are reported in millimeters Hg above atmospheric pressure. Height of peristaltic waves is recorded as pressure increment above resting pressure. All pressures analyzed are end-expiratory, except peristaltic peak pressure. Distances are expressed in centimeters from the nares.

Respirations and swallows were recorded simultaneously on a fourth channel with 2 pneumographic belts that were attached around chest and neck. The catheter tips were withdrawn from the stomach into the esophagus by 0.5-cm increments. A dry and a wet swallow was recorded with each new tube position. When the distal tip was in the high pressure zone (HPZ), the recording tube was fixed in this position, and a number of dry and wet swallows were recorded. Next, a 10-minute resting recording was obtained with the distal tip still in the HPZ. After this, a thin-walled rubber balloon attached to a polyvinyl tube (1.8 mm internal diameter), which had a metal marker at its distal end, was intro-

* Submitted for publication September 13, 1963; accepted March 12, 1964.

An abstract of this work appeared in *Gastroenterology* 1963, 44, 853.

† Supported by U. S. Public Health Service research career development award AM-K3-16,605 from the National Institute of Arthritis and Metabolic Diseases.

‡ Scholar in Radiological Research of the James Picker Foundation.

TABLE I
Clinical evaluation*

Subject	Senile dementia; confusion	Deep tendon reflexes			Sensory examination (legs)		Diabetes mellitus
		Biceps	Patellar	Achilles	Pin prick	Vibration	
1	Moderate	N	N	N	D	D	-
2	Moderate	N	D	D	N	N	-
3	None	N	D	D	D	D	-
4	None	N	N	N	N	N	-
5	None	D	D	D	D	N	-
6	Slight	N	N	N	N	N	-
7	None	D	D	D	N	N	-
8	Moderate	N	N	A	N	D	+
9	None	N	N	N	N	N	-
10	Slight	D	D	D	N	D	+
11	Slight	D	D	D	N	D	-
12	Moderate	A	A	A	D	A	+
13	None	A	A	A	N	A	+
14	None	N	N	N	D	D	-
15	None	N	N	N	D	A	-

* N = normal; D = decreased; A = absent.

duced *per os* in 14 subjects and positioned under fluoroscopic control in the mid-esophagus with the proximal end of the inflated balloon at the aortic arch and the distal end several centimeters above the proximal pressure recording tip. Although fluoroscopically the position of the distal recording tip appeared unaltered, the pressure tracing indicated that this tip was no longer in the HPZ in 3 subjects after introduction of the rubber balloon. To stimulate secondary peristalsis, the balloon was inflated within 1 second with air for 3 seconds; this was repeated 10 times. The volume of air used was determined by the amount needed to create a slight resistance upon inflation of the balloon *in situ* or the appearance of mild substernal pain in the subject; this usually required 30 ml, sometimes 40 ml, of air.

Finally, the balloon was inflated with air and connected to a volume recording device inscribing on a kymograph (9). Ten-minute recordings on the kymograph and the

Sanborn recorder were made after subcutaneous injection of 5.0 mg of methacholine chloride in 13 subjects, followed after 10 minutes by a 7.5-mg dose in 5 subjects.

The term "peristaltic wave" as used in this paper refers to the major, symmetrical pressure wave of the peristaltic complex (Figure 1A). "Duration" of the peristaltic wave is defined as the time necessary for the peristaltic wave to pass by a recording tip; in our studies this tip was located 10 cm proximal to the HPZ or to the point of respiratory phase reversal if no HPZ was present. Pressure waves were designated as "nonpropulsive" if a difference of 0.2 second or less was present between the onset of the pressure rise on 2 tracings recorded from tips 5 cm apart (10).

Results were calculated from the total number of observations made in the entire investigation. In addition, data on the various motor phenomena recorded in individual subjects are presented in Table III. The esopha-

TABLE II
Cineradiography

Subject	Incidence of peristalsis	Tertiary contractions	Dilatation	Delayed emptying		Gastroesophageal reflux
				Supine	Upright	
1	Reduced	Occasional	No	No	No	Yes
2	Reduced	Frequent	No	No	Yes	No
3	Reduced	Frequent	No	Yes	No	Yes
4	Reduced	Frequent	No	No	Yes	No
5	Normal	Occasional	No	No	No	No
6	Absent	Frequent	No	Yes	Not done	Yes
7	Reduced	Occasional	No	No	No	No
8	Absent	Occasional	No	Yes	No	No
9	Reduced	Frequent	Yes	No	No	Yes
10	Absent	Frequent	Yes	Yes	Not done	Yes
11	Reduced	Occasional	Yes	Yes	Not done	Yes
12	Normal	Occasional	No	No	No	Yes
13	Absent	Frequent	No	Yes	Yes	No
14	Absent	Frequent	Yes	Yes	No	No
15	Absent	Frequent	Yes	Yes	No	No

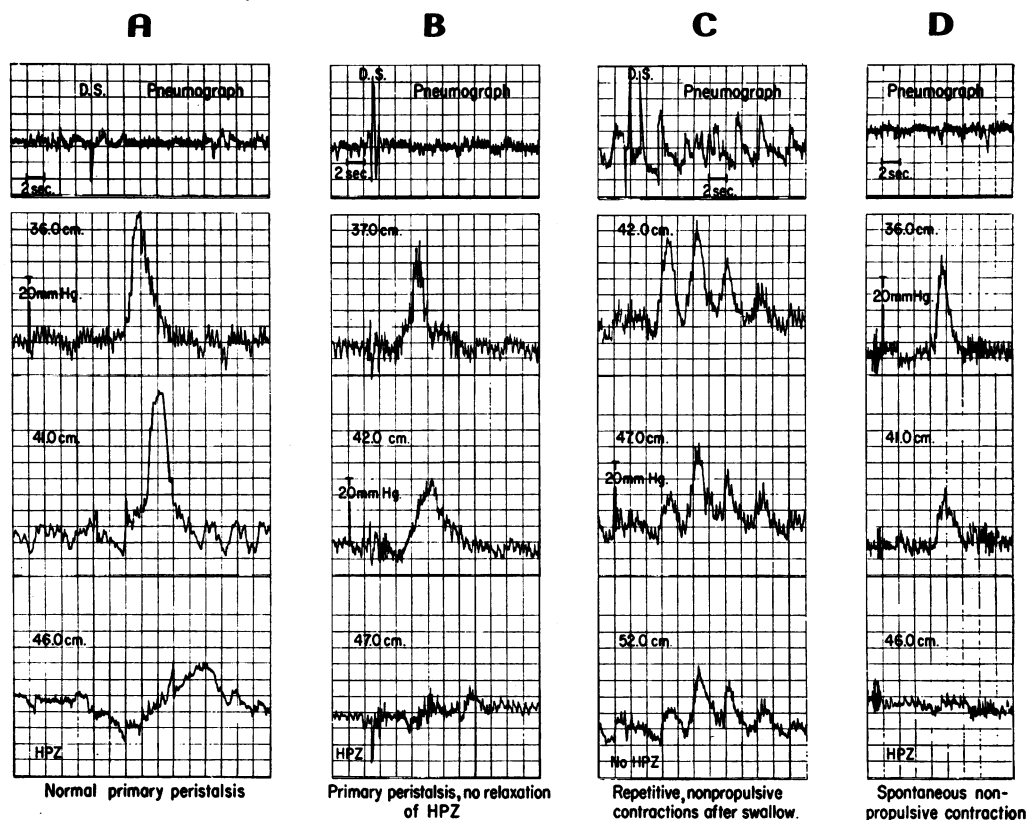


FIG. 1. REPRESENTATIVE EXAMPLES OF ESOPHAGEAL PRESSURE PROFILES. Distance of the 3 recording tips from the nares is indicated on each tracing. Paper speed on the original records: 2.5 mm per second. Pressures are reported as millimeters of Hg above atmospheric pressure. Brief deflections of high amplitude on the pneumograph tracing represent dry swallows (D.S.) recorded from a pneumographic belt around the neck. The distal tip is in the high pressure zone (HPZ) in all 4 panels and is located intra-abdominally in panels B and D.

geal motor responses to dry and to wet swallows were nearly identical in all respects and are, therefore, not reported separately.

Results

Cinicrodiography

Tertiary contractions occurred frequently, and in 9 studies they were the predominant motor response (Table II). In 6 subjects no esophageal peristalsis was observed. In only 2 subjects did esophageal motor activity appear similar to that in normal younger adults.

Appreciable delay in emptying of esophageal contents into the stomach was observed in 8 of the 15 studies with the subjects supine and in 3 of the 12 subjects examined in the upright position. In 5 subjects there was a moderate degree

of uniform esophageal dilatation. Gastroesophageal reflux was seen in 7 of 15 subjects in the horizontal position. A small sliding hiatus hernia was observed in only 1 subject (No. 3). Frequently the abnormal motor activity of the distal esophagus produced an appearance similar to a small hiatal hernia. When the differentiation could not be made with certainty, a hiatus hernia was not diagnosed.

Motility studies (Table III)

1) *High pressure zone (HPZ)* The high pressure zone (HPZ) or lower esophageal sphincter is defined as an area in the distal esophagus that exhibits an elevated resting pressure compared to adjacent segments of the esophagus or to intra-gastric pressure. In 7 subjects the HPZ was lo-

cated entirely in the thorax, and in another 7 it straddled the "effective diaphragmatic hiatus." The latter is defined as the point of reversal of the respiratory waves on the pressure tracing. In 1 subject (No. 15) an HPZ was not present. The length of the HPZ was 3.7 ± 1.1 cm (mean \pm 1 SD), and pressure increase recorded was 7.5 ± 2.3 mm Hg.

Relaxation of the HPZ was observed after 44% of all swallows and was consistently absent in 2 subjects (No. 1, 3) (Figure 1B). In every subject the distal recording tip remained in the zone of elevated esophageal resting pressure during all swallows that were evaluated.

2) *Primary esophageal peristalsis.* A total of 403 swallows was recorded. Fifty-one per cent were followed by peristalsis, 45% by nonpropulsive contractions, and 4% by no motor response at all. In 3 of the 15 subjects (No. 10, 11, 14), no esophageal peristalsis was registered by the recording tips located 5 and 10 cm above the HPZ.

Duration of the peristaltic wave was 4.16 ± 1.19 seconds (mean \pm 1 SD), and the speed was 3.54 ± 1.33 cm per second; the pressure increment above base line was 29.2 ± 10.5 mm Hg.

Nonpropulsive contractions followed more than 25% of all swallows in 10 of the 15 subjects. In 8 subjects (No. 8 to 15) some of the nonpropulsive contractions were repetitive in character, as defined by momentary return of the pressure tracing to the base line between two pressure maxima (Figure 1C). These 8 subjects had 149 nonpropulsive contractions of which 48 (32%) were repetitive. Of the total 403 recorded swallows, 12% were followed by repetitive nonpropulsive contractions.

3) *Esophageal activity during resting.* During 8 minutes of observation, spontaneous nonpropulsive contractions, not preceded by swallowing (Figure 1D), were seen in 7 of our 15 subjects. In 6, only a small number of spontaneous contractions were observed (1.33 per 8 minutes). In 1 subject (No. 15) the rate of spontaneous contractions was 27 per 8 minutes. Of a total of 36 spontaneous contractions, 30 were of the repetitive type.

4) *Secondary peristalsis.* Secondary peristalsis was studied in 14 of the 15 subjects. The esophageal balloon was distended 138 times.

Peristalsis followed 40%, nonpropulsive contractions 53%, and no response occurred after 7% of distentions. In 3 of the 14 subjects (No. 11, 13, 15) no peristaltic activity followed any of the 10 distentions. In the 3 subjects with absence of primary peristalsis, secondary peristalsis did not occur in 1 (No. 11), and it occurred only one out of ten times in the 2 other subjects (No. 10, 14). HPZ relaxation was evaluated in 10 subjects and occurred after only 54% of esophageal distentions.

5) *Response to methacholine.* In none of the subjects did the balloon kymographic response characteristic of cardiospasm appear. However, patients with cardiospasm occasionally require larger doses than those used by us to elicit the typical "Mecholy" response (11). In 1 subject (No. 15) an increase in esophageal resting tone developed, reflected by a change in balloon volume from 37.4 to 28.0 ml of air. A slight rise in intraluminal pressure of 2 and 3 mm Hg occurred in 2 of the 14 subjects (No. 10 and 15). None developed substernal pain. The absence of esophageal motor response after swallowing rose from 4% before to 26% after methacholine.

Discussion

On radiologic examination, esophageal motor function appeared disorganized and inefficient. This is in agreement with other reports on aged individuals (1, 3-6). Uniform esophageal dilatation, seen in one-third of our subjects, was found to be even more pronounced and frequent in a larger group of nonagenarians studied by cine-radiography alone (12).

The 50% incidence of upward displacement of the HPZ into the thorax in our subjects approaches that observed in pregnant women (13), many of whom had gastroesophageal reflux with heartburn. By contrast, in normal younger subjects the HPZ straddles the effective diaphragmatic hiatus in 80 to 100% of cases (14-16). Abnormalities of esophageal pressure recordings, such as double respiratory reversal, two pressure peaks on withdrawal of the recording tips, and increased length of the HPZ have been reported to indicate the presence of a hiatus hernia (17). In view of the frequently intrathoracic position of the HPZ in our subjects, these pressure phenom-

TABLE III
Motility studies*

Subject	H P Z			Response to swallows				
	Located in thorax	Length	Maximal pressure rise	N P C				
				No.	% peristalsis	% of total	% repetitive of total	% HPZ relaxations
		<i>cm</i>	<i>mm Hg</i>		<i>%</i>	<i>%</i>	<i>%</i>	<i>%</i>
1	Yes	4.5	5.5	28	64	32	0	0
2	Yes	5.0	9.5	18	83	17	0	17
3	Yes	4.5	9.5	13	54	38	0	0
4	Yes	4.0	8.0	22	68	27	0	20
5	No	3.0	8.5	41	88	10	0	70
6	Yes	4.5	8.0	25	96	4	0	48
7	No	4.0	7.5	16	81	19	0	66
8	Yes	3.0	6.0	25	36	64	4	71
9	No	2.5	4.5	20	50	45	10	52
10	No	4.0	7.0	16	0	63	25	75
11	No	3.0	6.0	10	0	100	70	64
12	No	5.0	14.0	40	77	23	8	61
13	No	4.0	5.5	73	38	56	18	12
14	Yes	1.0	6.0	34	0	100	6	54
15	None	None	None	22	5	91	73	Not present
Mean of all observations ± 1 SD	7/14	3.7 ±1.1	7.5 ±2.3	Total: 403	51	45	12	44
Young adults	0/19† (14)‡ 2/10 (15) 0/15 (16)	2-3 (14) 2-4 (15) 1-4 (16) 2-5 (18)	1-14 (15) 4.4-11.0 (16) 7.3-30.0 (18) 7.8 (19)		94 (7) 90 (15)		None (13, 15)	100 (7) 95 (14) Always (20)

* HPZ = high pressure zone; NPC = nonpropulsive contractions; no. = number of observations.
 † HPZ in thorax per number of subjects studied.
 ‡ Reference numbers are given in parentheses.

ena were carefully looked for but were never observed on our tracings. Reflux was present in 3 of the 7 subjects with an entirely intrathoracic HPZ and in 4 of the 7 in whom the HPZ extended below the effective diaphragmatic hiatus. Mean length and resting pressure of the HPZ are similar to the reported values in younger adults (14-16, 18, 19). Therefore, the high incidence of gastroesophageal reflux seen on cineradiography cannot be attributed to an insufficiency of the HPZ or to its location.

In young adults the HPZ responds to 90 to 100% of swallows and distentions of the esophagus with a sudden drop in pressure (7, 14, 20). Relaxation of the HPZ occurred only half as often in our nonagenarians, and this may be partly responsible for the delay in esophageal emptying observed cineradiographically in 3 subjects in the upright position (Tables II and III).

In young normal adults, 90% (15) to 94% (7) of swallows initiate an esophageal peristaltic

wave, compared to our figure of 51%. In 11 of our 15 subjects the incidence of peristalsis after swallows was less than 80%. In contrast to the defect in initiating primary peristalsis, the speed, height, and duration of peristaltic waves that did occur were normal (2, 7, 15, 18).

The decreased incidence of primary peristalsis was accompanied by a marked increase in nonpropulsive contractions after swallows. A nonpropulsive contraction was elicited by more than 25% of swallows in 10 of our 15 subjects, and in only 3 of 10 young normal adults studied by Nagler and Spiro (15). The same authors (13, 15) did not find repetitive nonpropulsive contractions after swallows in their younger subjects. In our group, 12% of all swallows evoked such a pressure profile. Creamer, Donoghue, and Code (10) in a study of subjects 43 to 60 years of age reported that repetitive nonpropulsive contractions followed 10% or less of swallows. This incidence was exceeded by 4 of our nonagenarians.

TABLE III
Motility studies*

No.	Peristalsis			Response to balloon distention		
	Speed	Height	Duration	% peristalsis	% NPC	% no response
	<i>cm/second</i>	<i>mm Hg</i>	<i>seconds</i>	%	%	%
10	4.8	19.8	3.7	63	37	0
10	5.1	37.8	4.5	90	10	0
10	3.0	24.8	3.6	Not done	Not done	Not done
7	3.3	26.1	3.4	90	10	0
34	3.0	37.1	4.8	50	50	0
14	2.8	40.0	6.1	100	0	0
19	4.2	34.3	3.5	10	70	20
5	3.1	12.0	3.1	10	80	10
13	3.3	29.1	3.5	70	30	0
				10	90	0
				0	90	10
33	3.5	17.1	4.0	60	10	30
32	3.7	31.3	3.9	0	100	0
				10	80	10
1	2.5	14.0	3.2	0	80	20
Total:	3.54	29.2	4.16	40	53	7
188	±1.33	±10.5	±1.19			
	2.0-2.5 (2)	15-50 (15)	2-6 (15)	37 (7)	5 (7)	58 (7)
	2-4 (7)		8-10 (18)	47 (22)	6 (22)	47 (22)
	2-4 (15)					
	2.5 (18)					

Comparison of the esophageal motility pattern on the manometric tracings with the cineradiographic appearance shows some discrepancies for which a variety of factors may be responsible (see Tables II and III). Of the 6 subjects in whom no peristalsis was seen on the radiographic film strips, only 2 subjects showed no primary peristalsis on the motility tracing; in 3 the incidence was reduced to 5%, 36%, and 38% of swallows, but in 1 (No. 6) peristalsis followed 96% of swallows. Conversely, peristalsis was judged to be reduced (1 subject) or absent (5 subjects) in all 6 subjects who showed an incidence of peristalsis after swallowing of less than 50%. In general, the incidence of primary peristalsis was underestimated on the radiologic examination. Reasons for this discrepancy may be the much longer period of observation during the motility study, the fact that the radiologic and the manometric studies were performed on different days, and lastly, technical differences between the two methods of observation as discussed in a recent review (21).

The incidence of peristalsis after esophageal distention (40%) in our aged subjects is similar to the figures of 37% (7) and 47% (22) reported in young subjects. In the same reported studies, no motor response occurred in 58 and 47% of balloon distentions, respectively; this compares to 7% in our cases. Nonpropulsive contractions after esophageal distention occurred frequently in our subjects, viz. 53% versus 5 and 6% in young adults (7, 22).

Spontaneous contractions, observed in 7 of our 15 subjects, were recorded in 5 of 24 young adult subjects by Nagler and Spiro (13, 15) and are frequently seen in cardiospasm (23), scleroderma (24), and diffuse spasm (10). It is unlikely that these pressure profiles represent a response to gastroesophageal reflux, since all contractions that were designated "spontaneous" were of the nonpropulsive type, and none was preceded by the pressure plateau indicative of reflux of material from the stomach into the esophagus (13).

The slight rise in esophageal resting pressure

after methacholine injection in 2 of our subjects is similar to the response of 10 young subjects to 3.0 mg of the drug as reported by Nagler and Spiro (15).

The degree by which esophageal function of individual subjects differed from the pattern seen in young adults was quite variable (Table III). However, esophageal motility in our group as a whole evidently bears some similarity to that reported in patients with "diffuse spasm" (10). One of our subjects (No. 14) admitted, after persistent questioning, to several years of mild, infrequent dysphagia when eating solids, although he had suffered no loss of weight. Esophageal peristalsis followed none of 34 swallows and 1 of 10 balloon distentions; the HPZ relaxed after only 54% of swallows. Esophagoscopy and cineradiography disclosed no further abnormalities. The rather low incidence of repetitive contractions in this subject, the absence of prolonged duration and increased peak pressure of the nonpropulsive and propulsive deglutitive responses, and the normal length and resting pressure of the HPZ make the diagnosis of "diffuse spasm" appear unlikely (10). We tentatively ascribe this subject's dysphagia to advanced senile deterioration of esophageal function. This case illustrates that there is no reliable way of differentiating between "diffuse spasm—asymptomatic or symptomatic" and "presbyesophagus" at our present state of knowledge. It is indeed possible that only a quantitative difference exists between these two entities.

The existence and location of an anatomical lesion accounting for the "disorganization of the highly integrated act of deglutition" (25) found in old age is a matter of speculation. Normal peristalsis requires an intact myenteric plexus (5), but the microscopic appearance of the intramural esophageal ganglion cells in advanced age is unknown. There is no clear-cut correlation between the degree of abnormality found on the neurological examination, the incidence of primary and secondary peristalsis, and the presence of senile dementia in our subjects (Table I and III).

Summary

Esophageal motor function was evaluated by cineradiography, intraluminal manometry, and

balloon kymography in 15 nonagenarians without gastrointestinal and central nervous system illness other than moderate degrees of senile dementia. Results were compared with those obtained by other investigators in younger subjects. Disorganization of the response to deglutition was revealed by a defect in initiating relaxation of the lower esophageal sphincter and of primary peristalsis, whereas the incidence of secondary peristalsis was impaired less frequently. Nonpropulsive, often repetitive, contractions were numerous. Tertiary contractions, delay of esophageal emptying, and dilatation of the esophagus were the predominant radiographic abnormalities.

The observed motility pattern resembles that of diffuse esophageal spasm.

Acknowledgment

We wish to thank Dr. Laurant D. Harris for his help with the technique of intraluminal manometry.

References

1. Templeton, F. E. *X-ray Examination of the Stomach*. Chicago, University of Chicago Press, 1944, pp. 110, 461.
2. Sanchez, G. C., P. Kramer, and F. J. Ingelfinger. Motor mechanisms of the esophagus, particularly of its distal portion. *Gastroenterology* 1953, **25**, 321.
3. Cross, F. S., E. B. Kay, and G. F. Johnson. Studies on neuromuscular imbalance of the esophagus. Cinefluorography and intraesophageal pressure studies. *Arch. Surg.* 1957, **75**, 631.
4. Kramer, P., and B. Fleshler. The pathophysiology of diffuse esophageal spasm. *Clin. Res.* 1958, **6**, 30.
5. Ingelfinger, F. J. Esophageal motility. *Physiol. Rev.* 1958, **38**, 533.
6. Johnstone, A. S. Diffuse spasm and diffuse muscle hypertrophy of lower oesophagus. *Brit. J. Radiol.* 1960, **33**, 723.
7. Siegel, C. I., and T. R. Hendrix. Evidence for the central mediation of secondary peristalsis in the esophagus. *Bull. Johns Hopk. Hosp.* 1961, **108**, 297.
8. Lorber, S. H., and C. J. D. Zarafonitis. Esophageal transport studies in scleroderma. *Amer. J. med. Sci.* 1963, **245**, 654.
9. Ingelfinger, F. J., and W. O. Abbott. Intubation studies of the human small intestine. XX. The diagnostic significance of motor disturbances. *Amer. J. dig. Dis.* 1940, **7**, 468.

10. Creamer, B., F. E. Donoghue, and C. F. Code. Pattern of esophageal motility in diffuse spasm. *Gastroenterology* 1958, **34**, 782.
11. Kramer, P., and F. J. Ingelfinger. Esophageal sensitivity to Mecholyl in cardiospasm. *Gastroenterology* 1951, **19**, 242.
12. Zboralske, F. F., J. R. Amberg, and K. H. Soergel. Presbyesophagus: cineradiographic manifestations. *Radiology* 1964, **82**, 463.
13. Nagler, R., and H. M. Spiro. Heartburn in late pregnancy. Manometric studies of esophageal motor function. *J. clin. Invest.* 1961, **40**, 954.
14. Fyke, F. E., Jr., C. F. Code, and J. F. Schlegel. The gastroesophageal sphincter in healthy human beings. *Gastroenterologia (Basel)* 1956, **86**, 135.
15. Nagler, R., and H. M. Spiro. Serial esophageal motility studies in asymptomatic young subjects. *Gastroenterology* 1961, **41**, 371.
16. Atkinson, M., D. A. W. Edwards, A. J. Honour, and E. N. Rowlands. The oesophagogastric sphincter in hiatus hernia. *Lancet* 1957, **2**, 1138.
17. Code, C. F., M. L. Kelley, Jr., J. F. Schlegel, and A. M. Olsen. Detection of hiatal hernia during esophageal motility tests. *Gastroenterology* 1962, **43**, 521.
18. Pert, J. H., M. Davidson, T. P. Almy, and M. H. Sleisenger. Esophageal catheterization studies. I. The mechanism of swallowing in normal subjects with particular reference to the vestibule (esophago-gastric sphincter). *J. clin. Invest.* 1959, **38**, 397.
19. Kelley, M. L., Jr., D. L. Wilbur III, J. F. Schlegel, and C. F. Code. Deglutitive responses in the gastroesophageal sphincter of healthy human beings. *J. appl. Physiol.* 1960, **15**, 483.
20. Atkinson, M., D. A. W. Edwards, A. J. Honour, and E. N. Rowlands. Comparison of cardiac and pyloric sphincters. A manometric study. *Lancet* 1957, **2**, 918.
21. Ingelfinger, F. J. The esophagus, March 1961 to February 1963. *Gastroenterology* 1963, **45**, 241.
22. Fleshler, B., T. R. Hendrix, P. Kramer, and F. J. Ingelfinger. The characteristics and similarity of primary and secondary peristalsis in the esophagus. *J. clin. Invest.* 1959, **38**, 110.
23. Butin, J. W., A. M. Olsen, H. J. Moersch, and C. F. Code. A study of esophageal pressures in normal persons and patients with cardiospasm. *Gastroenterology* 1953, **23**, 278.
24. Creamer, B., H. A. Andersen, and C. F. Code. Esophageal motility in patients with scleroderma and related diseases. *Gastroenterologia (Basel)* 1956, **86**, 763.
25. Vantrappen, G., M. D. Liemer, J. Ikeya, E. C. Texter, Jr., and C. J. Barborika. Simultaneous fluorocinematography and intraluminal pressure measurements in the study of esophageal motility. *Gastroenterology* 1958, **35**, 592.