

The Acute Effects of Atelectasis on the Pulmonary Circulation

Albert H. Niden

J Clin Invest. 1964;43(5):810-824. <https://doi.org/10.1172/JCI104967>.

Research Article

Find the latest version:

<https://jci.me/104967/pdf>



The Acute Effects of Atelectasis on the Pulmonary Circulation *

ALBERT H. NIDEN

(From the Department of Medicine, University of Chicago, Chicago, Ill.)

There is little doubt that pulmonary arterial blood flow is diverted away from chronically collapsed lung tissue. The earlier literature has been extensively reviewed by Berggren (1), and more recently other investigators have confirmed this finding (2-9). The effects of acute atelectasis on pulmonary blood flow are not, however, so well established (1, 4, 5, 7, 10, 11). Acute atelectasis has been induced by pneumothorax (1), by bronchial occlusion with chest wall intact (4), and by bronchial occlusion with chest opened wide and lungs ventilated by intermittent positive pressure (5, 7, 10, 11). It is generally assumed that the pulmonary hemodynamic changes with acute atelectasis are similar regardless of the method of inducing atelectasis. However, each of the above methods for producing local collapse of lung tissue (segment, lobe, or one lung) produces different "intrathoracic" pressure changes, different effects on left atrial pressure and on the non-collapsed lung tissue, and possibly noncomparable hemodynamic consequences. Since the early pulmonary vascular changes after endobronchial occlusion in the intact animal have not been well delineated, the following study was undertaken. The effects on the pulmonary circulation of acute atelectasis by endobronchial obstruction were investigated in fourteen intact lightly anesthetized dogs breathing spontaneously and six innervated perfused dog lungs ventilated by means of a whole body negative pressure respirator. In addition, the hemodynamic response to local pulmonary hypoxia and hypercapnea was contrasted with that of local collapse of lung tissue.

* Submitted for publication July 17, 1963; accepted December 26, 1963.

Supported by grants from the National Heart Institute (H-3878) (H-6918) and the Schweppe Foundation.

Presented in part at Federation Meetings of American Societies for Experimental Biology (Fed. Proc. 1961, 20, 105).

Methods

Mongrel dogs (15.6 to 22.8 kg) were anesthetized with morphine sulfate (2 mg per kg subcutaneously) and α -chloralose (50 to 100 mg per kg intravenously). Heparin (5 mg per kg, iv) was used for anticoagulation; additional heparin (2.5 mg per kg, iv) was administered every 2 to 3 hours. The trachea was cannulated routinely. Systemic blood pressure was measured with polyethylene tubing inserted into the carotid artery, pulmonary arterial blood pressure by cardiac catheter inserted into the pulmonary artery via the external jugular vein, and left auricular blood pressure by polyethylene tubing inserted into the left auricular appendage. Perfused pulmonary arterial (*vide infra*) blood pressure was determined by polyethylene tubing inserted into a side arm of the perfusion tubing and extending one-eighth to one-fourth inch beyond the orifice of the perfusion cannula (12). All pressures were measured by Statham strain gauge transducers and recorded on a Grass polygraph instrument. Peripheral arterial and mixed venous blood from the pulmonary artery were analyzed in duplicate for oxygen content and oxygen capacity by Van Slyke determinations (13). [In dogs no. 79, 80, and 81 oxygen saturation was determined with the Beckman spectrophotometer (14).]¹

Experiments were performed on fourteen dogs breathing spontaneously with chest wall intact, subsequently referred to as "intact dog" preparations. In an additional six dogs with chest wall opened, innervated left middle and lower lobes of the lung were perfused with a constant flow of blood (*vide infra*). These dogs will be referred to as "perfusion" experiments. In eleven of the fourteen intact dog preparations as well as all of the perfusion experiments, acute atelectasis was produced by a balloon-tipped single lumen polyethylene catheter (i.d., 0.07 inch; o.d., 0.11 inch). The catheter with balloon deflated was inserted into the trachea below the tracheostomy and positioned in the bronchus with the aid of bronchoscopy.

In three intact dog experiments the right lung was separated from the left by a modified Wright tracheal divider (15) or a Zavod-type bronchospirometer tube positioned under fluoroscopic control. When utilizing either the tracheal divider or the bronchospirometer tube, complete separation of the two lungs was confirmed by monitoring the nitrogen content in the ex-

¹ Analyses kindly performed by Gladys Mims.

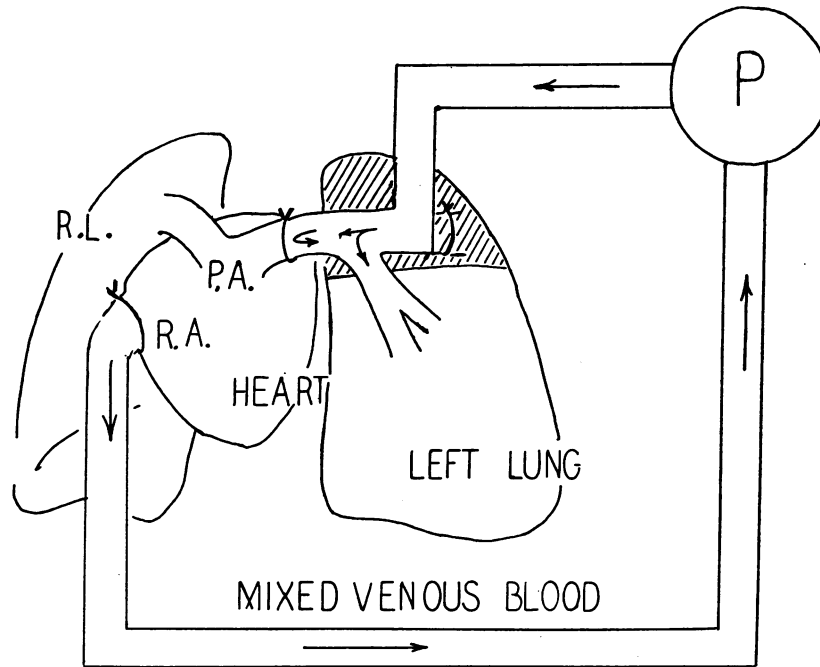


FIG. 1. SCHEMATIC DIAGRAM OF THE INNERVATED PERFUSION OF LEFT MIDDLE AND LOWER LOBES. Left upper lobe artery cannulated; see text for details. P = constant flow perfusion pump, PA = pulmonary artery, RA = right auricle, RL = right lung.

pired air² from each lung while giving 100% oxygen to one lung. As a result of tracheobronchial tree distortion with atelectasis, it was difficult to maintain separation of the right and left lungs with the tracheal divider or bronchospirometer tube. For this reason the balloon-tipped single lumen catheter was preferred to the tracheal divider or bronchospirometer tube.

The anatomic shunting of blood through the lungs can be estimated from the "shunt equation" (16):

$$\frac{\dot{Q}_s}{\dot{Q}} = \frac{C\dot{e}_{O_2} - Ca_{O_2}}{C\dot{e}_{O_2} - C\dot{v}_{O_2}} \quad [1]$$

where \dot{Q} and \dot{Q}_s are the total pulmonary blood flow and blood flow shunted past nonventilating alveoli, respectively, and $C\dot{e}_{O_2}$, Ca_{O_2} , and $C\dot{v}_{O_2}$ are the oxygen content of pulmonary end capillary, peripheral arterial, and mixed venous bloods, respectively.

The increased mixed venous blood shunted as a result of obstructing portions of lung was determined in the following manner. After insertion of the endobronchial tube (balloon-tipped, tracheal divider, or bronchospirometer tube) but before bronchial occlusion, the intact animals, breathing spontaneously, were ventilated with 100% oxygen for 15 minutes, and the oxygen content of the peripheral arterial blood was determined as a control value. After

² Nitralyzer Model 100 A, Custom Engineering and Development Co., St. Louis, Mo.

the animal had been returned to ventilation with room air for 10 minutes, portions of lung (segment, lobe, or whole lung) were made atelectatic by obstructing the bronchus. In four of the intact dogs, atelectasis was also induced while the animal was being ventilated with 100% oxygen, after which the nonobstructed lung was immediately returned to ventilation with room air. Peripheral arterial oxygen saturation was continuously monitored by a cuvette oximeter inserted between a femoral artery and vein and recorded on the Grass polygraph. At varying intervals after endobronchial obstruction, samples of peripheral arterial blood from the femoral artery and mixed venous blood from the pulmonary artery were obtained simultaneously for oxygen content determinations. To assess anatomic shunting, all blood samples were collected after the noncollapsed lung had been ventilated with 100% oxygen for 10 to 15 minutes. Thus in all experiments non-obstructed portions of lung were ventilated with room air except for 15-minute periods at the time of blood sample collections.

In these experiments the peripheral arterial blood oxygen content obtained as a control value while breathing 100% oxygen (Ca_{O_2} control) is used as an estimate of the pulmonary end capillary blood oxygen content. By substituting the Ca_{O_2} control for $C\dot{e}_{O_2}$ in Equation 1, we have:

$$\frac{\dot{Q}_s}{\dot{Q}} = \frac{Ca_{O_2\text{control}} - Ca_{O_2}}{Ca_{O_2\text{control}} - C\dot{v}_{O_2}} \quad [2]$$

which is then an estimate of the blood flow shunted as a

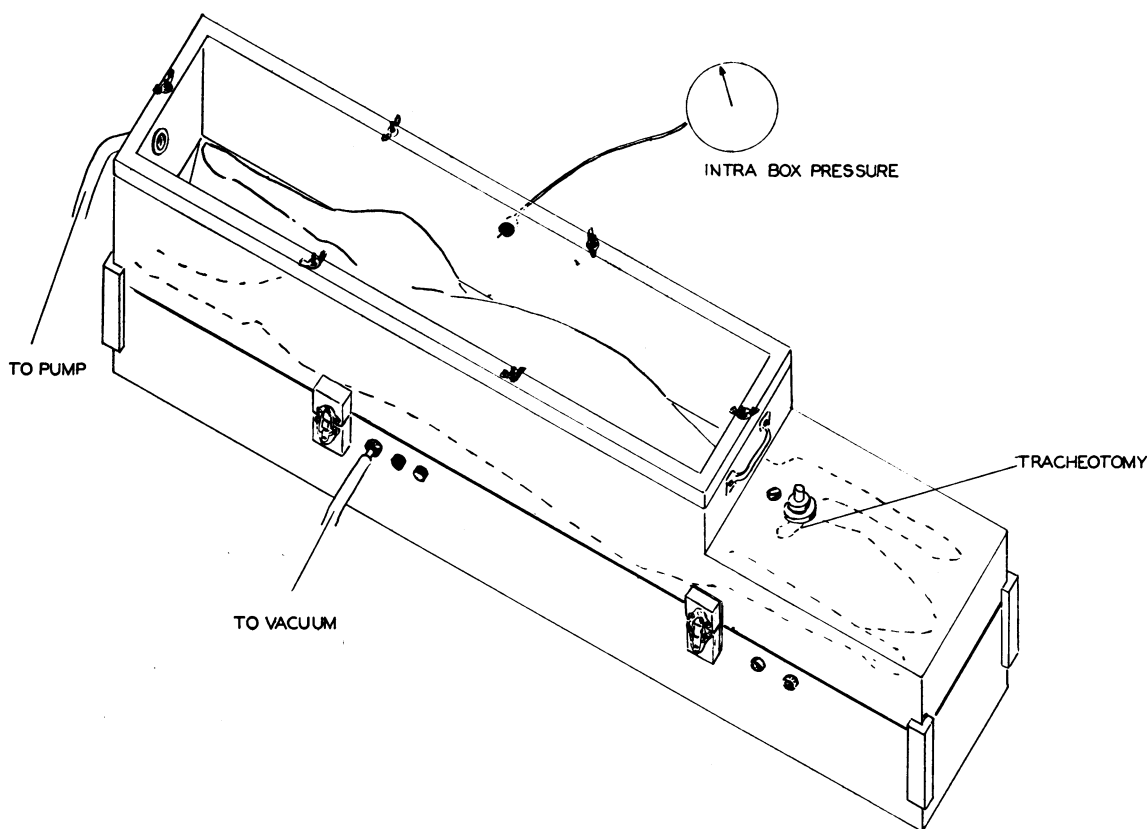


FIG. 2. WHOLE BODY NEGATIVE PRESSURE ANIMAL RESPIRATOR.

result of collapsing lung tissue. Since the Ca_{O_2} control is less than the true pulmonary end capillary blood oxygen content, Equation 2, which was used for the calculations to be reported, would give an underestimate of the total shunt present after atelectasis. However, if the oxygenation of pulmonary end capillary blood is the same during the control and test periods while breathing 100% oxygen, this equation does give a close approximation of the shunt resulting from the endobronchial occlusion.

To assess the magnitude of change in the oxygenation of end capillary blood from the control to the test periods (whether the intermittent use of 100% oxygen produced sufficient atelectasis in the nonoccluded portions of lung to affect the results), control experiments were performed on four intact dogs. The dogs were prepared for endobronchial occlusion as outlined above. One hundred per cent oxygen was administered to the four dogs for 20 minutes alternately with room air for 30 minutes for total periods of 200, 200, 250, and 200 minutes, respectively. Peripheral arterial and mixed venous blood samples were collected while the animals were breathing 100% oxygen at the end of the initial (Ca_{O_2} control) and final (Ca_{O_2} , $C\bar{v}_{O_2}$) 20-minute periods of oxygen breathing. The percentage of shunting of

blood past nonventilating alveoli was then calculated as in the experimental animals.

In the perfusion experiments, innervated left middle and lower lobes were perfused after opening the chest with a left fourth intercostal incision and while ventilating the lung with a Harvard positive pressure respirator. The perfusion cannula, directed towards the pulmonary arterial bifurcation, was tied into the left upper lobe artery. The left main pulmonary artery was ligated by an intrapericardial ligature. Thus the left middle and lower lobes could be perfused without manipulation of or interference with their nerve supply or bronchial circulation. The perfused pulmonary venous outflow drained normally into the left auricle and thence to the systemic circulation. Blood flow to the right lung was maintained by the animal's own heart (Figure 1) (17). Perfusion blood flow was kept constant with a modified Dale-Schuster pump (12) primed with heparinized blood (10 mg heparin per 100 ml blood) or dextran.³ Blood flow was continuously monitored and recorded on the Grass polygraph by a Shipley-Wilson rotameter inserted into the inflow side of the circuit. Perfusion was begun

³ Generously supplied by Abbott Laboratories, North Chicago, Ill.

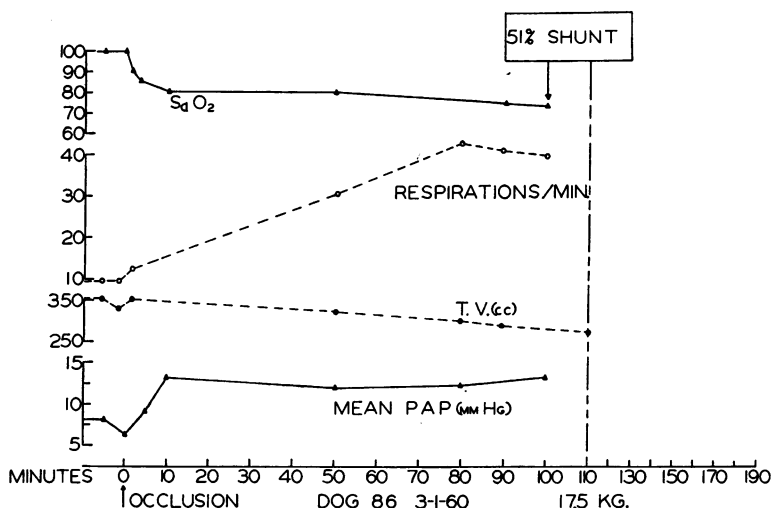


FIG. 3. ACUTE COLLAPSE OF THE RIGHT LOWER LOBE WHILE BREATHING ROOM AIR (DOG 86). In this and all subsequent figures, Sa_o₂ = peripheral arterial oxygen saturation while ventilating noncollapsed lung with 100% oxygen. TV = tidal volume; mean PAP = mean pulmonary arterial pressure. Endobronchial occlusion at time "O." Anatomic shunt calculated at the arrow.

before tying the intrapericardial ligature about the left main pulmonary artery so that blood flow to the perfused area was uninterrupted. In all perfusion experiments ventilation was maintained without interruption of ventilation or perfusion by a box respirator (Figure 2) with the trachea opened to the atmosphere, the

lung being ventilated with rhythmic changes of negative pressure within the box (11). Catheters for measuring carotid arterial, pulmonary arterial, left auricular, and perfusion blood pressures as well as the balloon-tipped single lumen endobronchial catheter were brought out through rubber stoppers inserted into openings in the

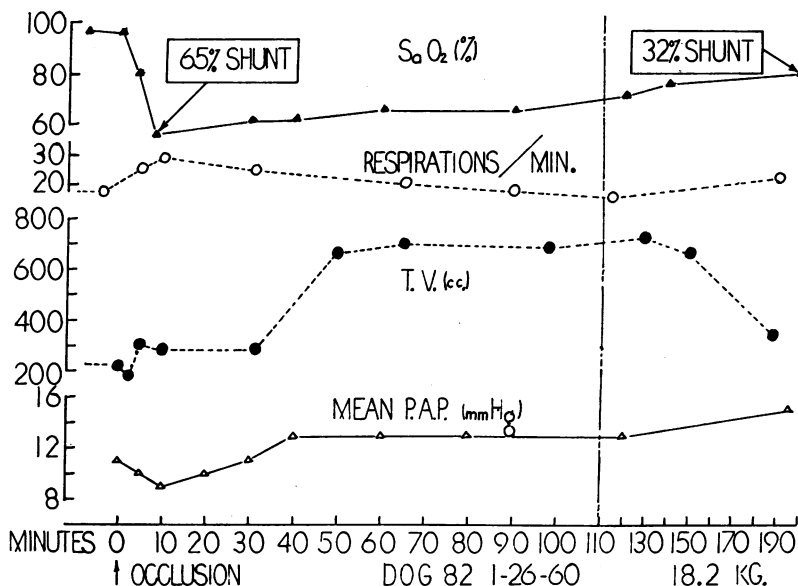


FIG. 4. ACUTE COLLAPSE OF LEFT LOWER LOBE WHILE BREATHING ROOM AIR (DOG 82). Note the reduction in anatomic shunt after 3 hours and 10 minutes.

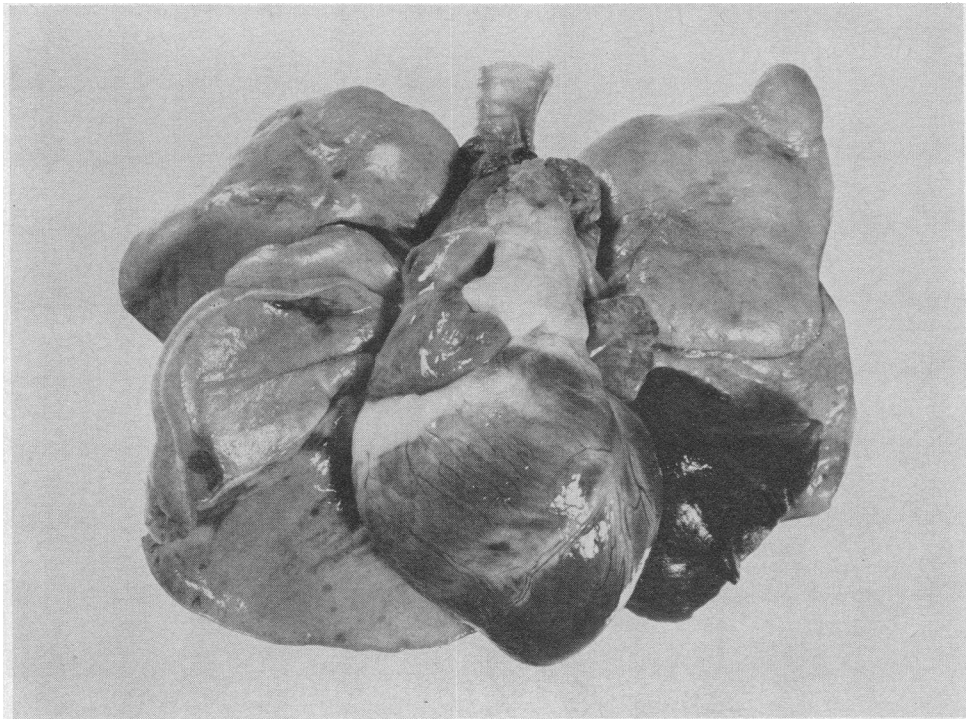


FIG. 5. TYPICAL AUTOPSY FINDINGS (DOG 109) 4 HOURS AND 20 MINUTES AFTER ENDOBRONCHIAL OCCLUSION OF LEFT LOWER LOBE BRONCHUS REVEALING COMPLETE ATELECTASIS OF LEFT LOWER LOBE.

TABLE I
Acute atelectasis versus percentage of blood shunted in intact dogs

Dog no.	Lung collapsed*	Duration collapsed <i>minutes</i>	% Lung collapsed	% Shunt
79	Segment left lower lobe	120	15	40†
80	Segment left lower lobe	30	15	30†
81	Right lung	30	55	83
82	Left lower lobe	10	30	65
	Left lower lobe	200	30	32
84	Right lung or less‡	45	55 or less	63
85	Right lower and middle lobes	100	40	51
86	Right lower lobe	110	30	51
87	Right lower lobe	20	30	40
	Right lower lobe (100% O ₂)§	25	30	50.5
99	Left lung	45	45	49
101	Left lung	25	45	36.5
	Left lung (100% O ₂)§	25	45	35
109	Left lower lobe	260	30	50
	Left lower lobe (100% O ₂)§	15	30	40
115	Left lung or less‡	10	45 or less	47
123	Left lung	20	43	53
	Left lung (100% O ₂)§	20	41	63
129	Segment left lower lobe	35	15	36

* Lungs collapsed while breathing room air unless otherwise noted.

† No mixed venous sample. a-v O₂ gradient assumed to be 5 vol per 100 ml.

‡ Balloon broke after blood determinations. Maximal possible percentage of lung collapsed estimated by position of balloon at autopsy (terminal portion of lower lobe bronchus).

§ Lung collapsed after ventilation with 100% O₂.

|| Determined from percentage of ventilation to each lung with bronchspirometer tube.

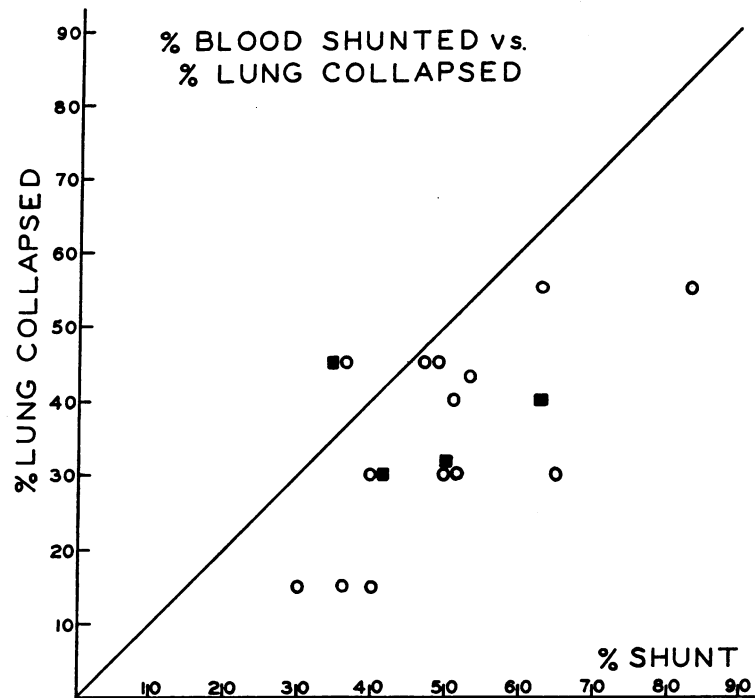


FIG. 6. SUMMARY OF ACUTE ATELECTASIS IN INTACT DOGS. ○ = endobronchial occlusion after ventilation with room air. ■ = endobronchial occlusion after ventilation with 100% oxygen. All points below the diagonal line indicate a greater percentage of anatomic shunting than percentage of lung tissue collapsed.

box. After a 15- to 30-minute control period, occlusion of the left middle and lower lobe bronchi was produced by inflation of the balloon at the tip of the endobronchial catheter. The extent of atelectasis was directly visualized through a clear plastic window in the respirator box.

All intact dogs were autopsied (the chest being opened with the trachea occluded) immediately after blood gases were obtained. The extent of atelectasis was noted grossly and the lung photographed. The lung was removed with trachea occluded and fixed in formalin. Both the overdistended and collapsed lung tissues were then sectioned and stained with hematoxylin and eosin for examination with the light microscope.

Results

Acute pulmonary atelectasis in the intact dog.

The over-all response to atelectasis by endobronchial occlusion of portions of the lung (segment, lobe, or whole lung) was observed in fourteen intact dogs for periods of from 20 minutes to 4 hours and 20 minutes. With endobronchial obstruction there was a fall in peripheral arterial oxygen saturation beginning within 1 to 2 minutes

and reaching a low value (47 to 89.5% while breathing 100% oxygen) within 10 to 20 minutes. This was accompanied regularly by an immediate slight fall in mean pulmonary arterial blood pressure that was usually but not always followed by a moderate increase in pressure. Respiratory minute volume increased two- to fourfold as a result of an increase in respiratory rate or tidal volume or both (Figures 3, 4).

The calculated percentage of blood flow shunted through nonventilating alveoli as a result of the occlusion ranged between 30 and 83%. Except for one dog (no. 101), the percentage of blood flow shunted was equal to or greater than the amount of lung tissue collapsed, as ascertained at autopsy (Figure 5). The extent of atelectasis was sharply outlined and limited to anatomic segments or lobe(s). The data are summarized in Table I and Figure 6. One dog (no. 82) observed over a protracted period of time showed a change in the percentage of blood shunted from an initial 65 to 32% at 3 hours and 20 minutes

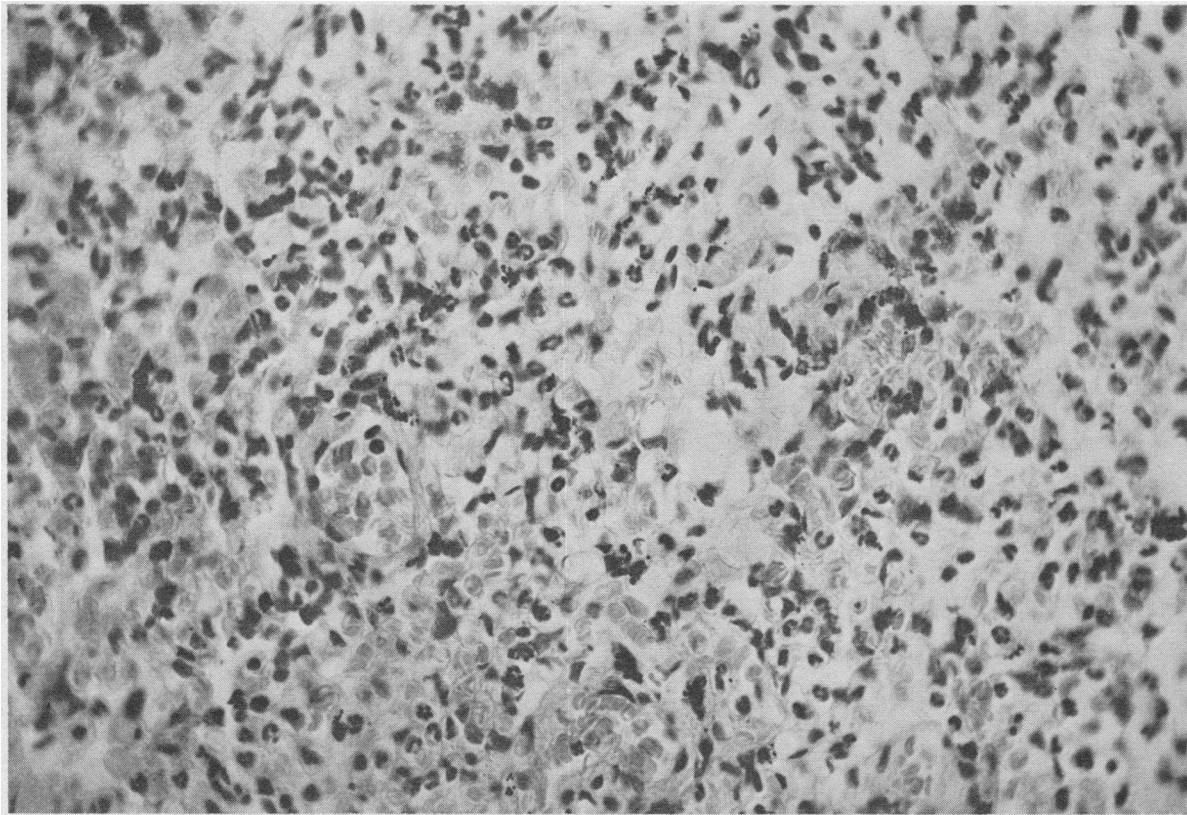


FIG. 7. TYPICAL HISTOLOGIC APPEARANCE OF THE ACUTELY ATELECTATIC LUNG (RIGHT LOWER AND MIDDLE LOBES, DOG 85) 1 HOUR AND 40 MINUTES AFTER COLLAPSE. Note dilated vascular bed filled with red blood cells ($\times 500$).

after collapse of the left lower lobe (approximately 30% of the lung) (Figure 4).

In one dog (no. 109) intrapleural pressure was measured through a Harvard pleural cannula. Mean intrapleural pressure was -9.0 cm H_2O before and -14.0 cm H_2O after collapse of left lower lobe.

With acute atelectasis the a-v oxygen gradient across the lung while breathing 100% oxygen (16 determinations) ranged between 4.43 and 9.80 vol per 100 ml oxygen, with an average value of 7.27. The oxygen gradient while ventilating one lung with 100% nitrogen (six determinations) ranged between 7.88 and 10.43, with an average of 9.01 vol per 100 ml oxygen.

The histologic appearance of the acutely atelectatic lung revealed, in addition to complete atelectasis of the alveoli, marked congestion of the pulmonary vascular bed with dilated arterioles and capillaries filled with red blood cells. A typical microscopic section is shown in Figure 7.

Acute pulmonary atelectasis in the intact dog while breathing 100% O_2 . In four dogs the effect of acute bronchial obstruction while breathing room air was compared to that while breathing 100% oxygen (Figures 6, 8; Table I). Except for the delay of 4 to 8 minutes before a fall in peripheral arterial oxygen saturation with the dogs breathing 100% oxygen, there was no difference in response.

This venous admixture, greater than predicted from the percentage of lung tissue collapsed while breathing room air or 100% oxygen, could have resulted from *a*) atelectasis in the dependent portions of nonoccluded lung as a result of anesthesia and 100% oxygen or *b*) the opening of anatomic shunts in the noncollapsed lung as a consequence of overdistention or *c*) the decreased pulmonary vascular resistance in the acutely collapsed lung because of hypoxia, hypercapnea, neurogenic stimuli, and/or mechanical effects. Further experiments were designed to determine the mecha-

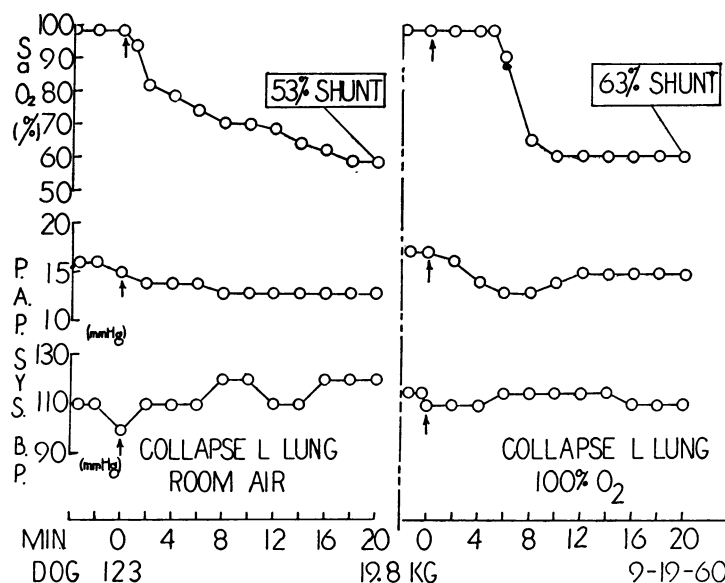


FIG. 8. ACUTE ATELECTASIS OF LEFT LUNG (DOG 123). Lung filled with room air before collapse compared to lung filled with 100% oxygen before collapse. Sys. BP = peripheral arterial blood pressure.

nism of this early increased venous admixture in acute pulmonary atelectasis by endobronchial occlusion.

Intermittent 100% oxygen to control dogs. Alternate administration of 100% oxygen for 20 minutes and room air for 30 minutes to four anesthetized dogs for 200, 200, 250, and 200 minutes, respectively, produced a calculated shunt of pulmonary blood flow through nonventilated alveoli ranging between 0 and 6% (Table II).

Local hypoxia and hypercapnea in the intact dog without atelectasis. To ascertain whether the local effect of capillary or venous blood gas changes (hypoxemia and hypercapnia) in the atelectatic lung tissue could account for the apparent increase in blood flow through an acutely atelectatic lung, ventilation of one lung with 100% nitrogen either alone or with 7.5% carbon dioxide was compared to acute atelectasis. Utilizing a bronchspirometer tube to separate the left lung from the right, ventilation of the left lung with nitrogen, either alone or with 7.5% carbon dioxide, produced less shunting of blood through this lung than acute collapse of the left lung in two dogs (Table III, Figure 9). Since oxygen is actually removed from blood flowing past alveoli being ventilated with 100% nitrogen, the calculated

percentage of blood shunted under these circumstances is an overestimate of the true shunt. Thus the local effects of hypoxemia and hypercapnia could not account for the increased shunting of blood through acutely collapsed lung.

Acute pulmonary atelectasis in the innervated lung perfusion. To measure directly changes in vascular resistance in the atelectatic lung, constant flow perfusions of innervated left middle and lower lobes were performed in six dogs. Acute collapse of these lobes perfused at a constant flow resulted in an immediate fall in perfusion pressure in five of the six dogs tested with either no change or more often a slight rise in pulmonary

TABLE II
Effect of intermittent ventilation with 100% oxygen on the shunting of blood

Dog no.	Total time	Total duration 100% O ₂	% Shunt*
	minutes	minutes	
251	200	80	6
253	200	80	0
255	250	100	4
257	200	80	4

* Assuming 0% shunt after 20 minutes of ventilation with 100% oxygen [time of first (control) blood samples]. See text for details.

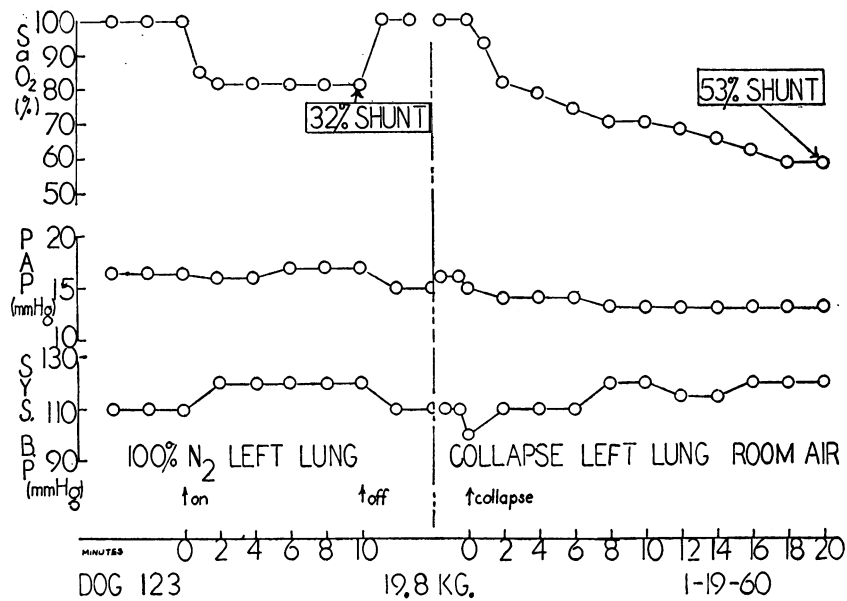


FIG. 9. COMPARISON OF ACUTE COLLAPSE OF LEFT LUNG WITH UNILATERAL VENTILATION WITH 100% NITROGEN (DOG 123).

arterial pressure of the noncollapsed lobes whose blood supply came from the animal's own heart. There was no change or a slight increase in the left atrial pressure. Re-expansion of the collapsed lung resulted in immediate return of pressures to the control level (Figures 10, 11). Sympathectomy (removal of thoracic sympathetic ganglia 2 through 6) in four dogs and bilateral vagotomy alone or in combination with sympathectomy in two dogs did not alter the type of response (Figure 10).

In one experiment, blood flow through the left lower and middle lobes was measured directly by collecting the outflow from the left lower lobe vein and that from the left middle lobe vein. The left lower and middle lobes were perfused in the

usual manner from a single pump at a constant flow while the lung was ventilated in the negative pressure animal respirator. Collapse of the left lower lobe alone resulted in an increase in left lower lobe venous outflow with an equal decrease in left middle lobe venous outflow, over-all flow through the two lobes being maintained constant by the perfusion pump.

Discussion

Acute pulmonary atelectasis by endobronchial occlusion in the intact dog results in an increased venous admixture of the peripheral arterial blood out of proportion to the amount of lung tissue collapsed. Constant-flow innervated lobe perfusions suggest that this is on the basis of an initial decrease in pulmonary vascular resistance in the atelectatic lobes. Sympathectomy alone or combined with vagotomy does not alter the response. When compared to the effect of acute atelectasis, unilateral ventilation with 100% nitrogen or 92.5% nitrogen and 7.5% carbon dioxide in the same dog reduces the amount of blood flow to the affected lung, indicating that the decreased vascular resistance in acute atelectasis cannot be ascribed to the associated alveolar hypoxia and hypercapnea or to either separately.

TABLE III

Acute atelectasis versus ventilation with 100% nitrogen to left lung

Procedure	% Total ventilation, left lung	% Blood shunt
100% N ₂ , left lung	41	32
Room air, collapse left lung	43	53
100% O ₂ , collapse left lung	41	63

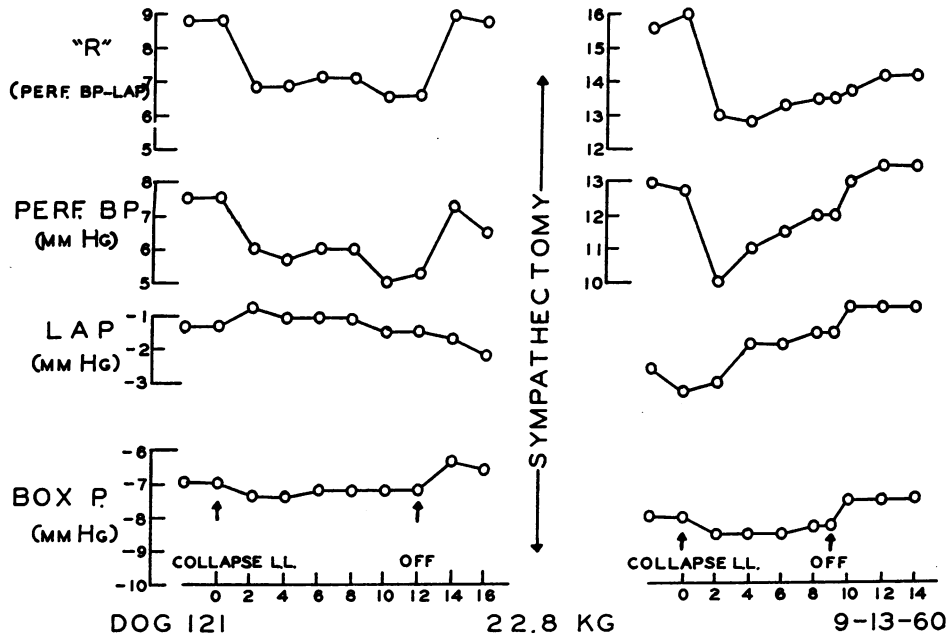


FIG. 10. ACUTE ATELECTASIS OF THE INNERVATED PERFUSED (CONSTANT FLOW) LEFT MIDDLE AND LOWER LOBES BEFORE AND AFTER SYMPATHECTOMY (DOG 121). R = perfusion arterial blood pressure minus left atrial blood pressure, a measure of vascular resistance when blood flow is constant. Perf. BP = perfusion arterial blood pressure. LAP = left atrial pressure. Box P = intrabox pressure of the negative pressure whole animal respirator, i.e., "intrathoracic" pressure.

The histologic observations of the acutely collapsed lung reveal a dilated capillary bed filled with red blood cells. These findings agree with the physiologic findings indicating a decreased pulmonary vascular resistance. Passive congestion

cannot, however, be differentiated from an increased blood flow on the basis of histologic appearance. In contrast, chronic atelectatic lung has a reduced vascular bed histologically as well as a reduced blood flow physiologically (18, 19).

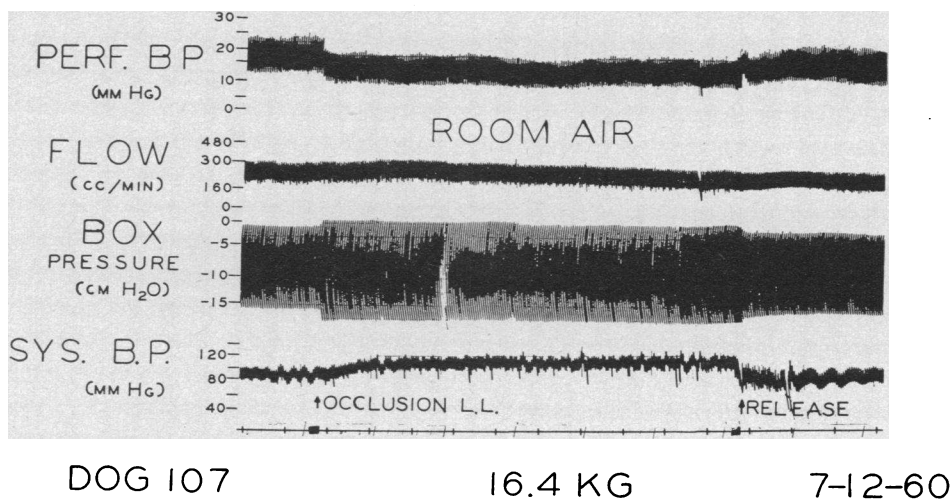


FIG. 11. ACTUAL TRACING FROM AN INNERVATED LEFT MIDDLE AND LOWER LOBE PERFUSION (DOG 107).

Several technical problems are apparent in a study of this type. First, despite careful placement by bronchoscopy of the balloon-tipped catheter, it is impossible to collapse a predetermined amount of lung tissue with certainty. Thus performing routine autopsies immediately after the collection of blood samples is essential to ascertain the actual extent of atelectasis and the position of the balloon. In all cases the area of atelectasis was sharply defined and limited to anatomic segments or lobes. Second, endobronchial occlusion is used to produce atelectasis to eliminate any possible injury to the nerve supply, to the bronchial circulation of the collapsed lobes, or to both, which may occur with the use of a bronchial ligature. Third, cannulation for the constant flow perfusions of the left middle and lower lobes is important. This approach eliminates manipulation of and injury to the vessels and nerves of the perfused lobes, which frequently occur when direct cannulation of the perfused lung is employed. Finally, as indicated by the results, the oxygen a-v gradient across the lung in acute abnormal cardiopulmonary conditions such as acute lung collapse may be increased above the normal average of 4.2 vol per 100 ml [2.3 to 6.3 in dogs anesthetized with Nembutal (20, 21)]. Therefore, assumption of a fixed a-v gradient under such circumstances is invalid; a mixed venous blood sample is necessary to determine accurately the percentage of blood shunted. The reasons for the increase in a-v oxygen gradient in these experiments are not clear. Chloralose anesthesia, hypoxemia, and hyperventilation may have induced an increase in oxygen consumption or a decrease in cardiac output, or both. Neither of these parameters was measured.

From the results, at least initially, there is apparently little difference between the blood flow through a partially collapsed lobe and through a completely collapsed lobe after endobronchial occlusion. Although the lobes filled with room air at the time of the endobronchial obstruction did not completely collapse for a few hours because of the nitrogen present, the lung filled with 100% oxygen became completely atelectatic within 10 minutes (22). Despite this, there was no difference between the shunting observed after endobronchial occlusion while breathing room air and

while ventilating with 100% oxygen, except for the earlier appearance of peripheral arterial oxygen desaturation with the former (Figures 6, 8; Table I). The delayed appearance of arterial hypoxemia after obstruction of the oxygen-filled lungs is understandable. The partial pressure of oxygen in this lung remains high until all the oxygen is absorbed and alveoli completely collapse. In contrast, with nitrogen present in the lobes filled with room air, the partial pressure of oxygen begins to decrease immediately as oxygen is removed, resulting in an almost immediate arterial desaturation after obstruction of those lobes.

Although the hemodynamic effects in the ventilated lung were not extensively investigated in the present study, the marked peripheral arterial hypoxemia noted after bronchial occlusion of one or more lobes of the lung could have resulted from changes in the noncollapsed lung. Possible causes of desaturation of blood leaving the ventilated lung are the maintenance or increase of blood flow past poorly ventilated alveoli (physiologic shunting), the spontaneous development of atelectasis in the dependent portions of the ventilated lung secondary to anesthesia and oxygen breathing, and the opening of a-v shunts in the ventilating lung. For the following reasons, none of these mechanisms is believed to be of major importance in these experiments: *a*) Ventilating the noncollapsed lung with 100% oxygen before blood oxygen determinations should have eliminated the effects of any physiologic shunting that might have been induced by overdistention of the ventilating lung. *b*) Since continuous ventilation with 100% oxygen in an anesthetized animal is apt to induce atelectasis of dependent portions of lung, it was necessary to determine whether the intermittent use of 100% oxygen at the time of blood sampling might have produced enough atelectasis in the ventilated lung to produce venous admixture. For the following reasons it is unlikely that atelectasis in the non-obstructed lung contributed significantly to the observed venous admixture: 1) acuteness of the response, 2) the lesser degree of venous admixture with 100% nitrogen to one lung compared to collapse of the same lung, 3) the marked hyperventilation noted in the ventilated lung secondary to acute atelectasis (this would tend to minimize the

development of hypostatic atelectasis), and most important, 4) the minimal degree of shunting observed in the control animals ventilated with 100% oxygen for long periods of time (Table II). *c*) The possibility that some of the venous admixture noted was a result of the opening of a-v shunts in the ventilated lung, which may open with pulmonary embolism (17) and with certain drugs (23), cannot be ruled out on the basis of the data available. However, the perfusion studies revealed an increase in the pulmonary arterial pressure in the noncollapsed lung supplied by blood from the animal's own heart, whereas there was a fall in the vascular pressure of the collapsed lobes perfused at a constant blood flow. This increase in pulmonary arterial pressure in the noncollapsed lung supplied by the dog's own heart does not suggest opening of a-v shunts but could have resulted from an increase in cardiac output secondary to blood gas changes, an increase in pulmonary vascular resistance secondary to blood gas changes, or overdilatation of the noncollapsed lung. There was no systematic change in left auricular pressure.

Regardless of the above, hemodynamic changes in the nonobstructed lung cannot be the sole cause of the marked venous admixture of peripheral blood noted in these experiments. Direct measurements in the perfused innervated lung unequivocally demonstrate a fall in vascular resistance after bronchial occlusion of that lung. In addition, when over-all blood flow through the left lower and middle lobes is kept constant, endobronchial obstruction of the left lower lobe results in an increase in flow through the collapsed lobe as measured directly by collecting venous outflow. At the same time, a concomitant decrease in blood flow occurs in the noncollapsed left middle lobe.

There are several possible explanations for this increase in blood flow through and decrease in vascular resistance of the collapsed lung. These include neurogenic stimuli, the local effects of hypoxemia and hypercapnia, the effects of surface tension alterations, and mechanical factors.

Denervation failed to alter the response. Induced local hypoxia and hypercapnea without collapse resulted in reduced rather than augmented blood flow through the affected lung. No at-

tempt was made to evaluate the possible effect of surface tension changes on pulmonary vascular resistance in the acutely atelectatic lung. Although surface forces may play a part, it has been shown to be insignificant compared to the effects of geometrical factors over the course of negative pressure inflation or deflation (24). Thus the increased blood flow through and reduced vascular resistance in the atelectatic lung are apparently the result of passive geometric alterations secondary to lung volume and pressure changes.

Simple anatomic shortening and widening of the capillary bed with pulmonary collapse (25) could account for a significant reduction in pulmonary vascular resistance, since a major portion of the total pulmonary vascular resistance is located in the intra-alveolar vessels (26). In addition, after endobronchial occlusion, intra-alveolar pressure is gradually reduced until, with complete collapse, the intra-alveolar pressure in the atelectatic lung approaches the intrathoracic pressure, and the transpulmonary pressure (the difference between airway pressure and the pressure surrounding the lungs) approaches zero. The reduction in intra-alveolar pressure in the collapsed lung lowers perivascular pressure in this area, resulting in an increase in transmural pressure (the difference between intravascular and perivascular pressures). Both of these changes, a decrease in transpulmonary pressure and an increase in transmural pressure, have been shown to lower pulmonary vascular resistance (27, 28).

Although the above pressure alterations would occur with or without intrathoracic pressure changes, the reduced intrapleural pressure noted with acute endobronchial obstruction in an intact animal might preferentially accentuate the initial vascular changes in the collapsed lung, possibly dilating the larger blood vessels that might normally collapse with deflation (25). The decrease in intrathoracic pressure would also tend to overdilate the ventilating lung. This would increase the pulmonary vascular resistance in the noncollapsed lung (29), further enhancing the shunting of blood through the collapsed lung.

Present results agree with those of Björk (4, 5) and with the findings of Aviado in some open chest dogs (10). On the other hand, numerous

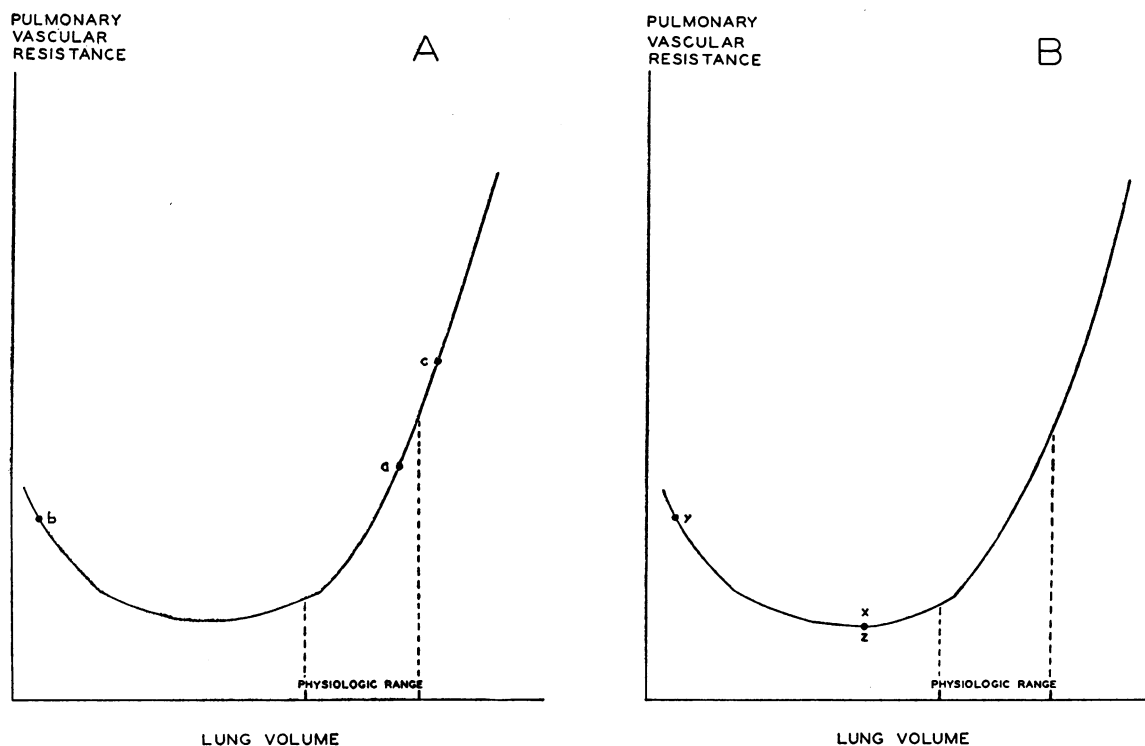


FIG. 12. SCHEMATIC VASCULAR RESISTANCE-LUNG VOLUME CURVE. Drawn from Figure 6B, Thomas, Griffo, and Roos (29). Physiologic lung volume from personal observations in intact dogs; see text.

investigators have demonstrated only an increase in pulmonary vascular resistance in and a reduced blood flow through the acutely collapsed lungs of dogs ventilated with chest open and intermittent positive pressure (see Berggren for earlier references, 7, 11). In view of the findings of Thomas, Griffo, and Roos (29), it may be possible to reconcile these seemingly divergent results.

These authors (29) have demonstrated that in the excised dog lung, vascular resistance during negative pressure deflation is volume dependent. They also showed that with negative pressure inflation or deflation, resistance falls to a minimum at moderate inflation of the excised lungs and rises with further inflation or deflation. Thus the initial state of the lung at the time of collapse would affect the direction of change in vascular resistance (28, 29). Assuming that the intact lung will respond similarly to excised lungs in this respect, we can draw a schematic lung volume-vascular resistance curve based on the observations of Thomas and colleagues (29) (Figure 12). If the physiologic lung volume in the intact dog is at point *a*

(Figure 12A), then with bronchial obstruction, the vascular resistance in the collapsed lung will fall to point *b* and in the overdistracted ventilating lung will rise to point *c*. This is compatible with observations noted here. On the other hand, in the open chest dog, the lung volume might be less than the physiologic lung volume (for example, at point *x*, Figure 12B). In this case, the vascular resistance in the atelectatic lung would increase to point *y* (Figure 12B), whereas the nonobstructed lung would not change in size, and its vascular resistance would remain at point *z* (Figure 12B). This would explain the increased resistance and decreased blood flow noted in some of the open chest experiments. The lung volume of the intact dog breathing spontaneously may be assumed to be normal. Unfortunately, lung volumes of the open chest dog are not available in these experiments, nor have they been reported in other studies of atelectasis.

Although acute bronchial obstruction in the intact dog results in a reduced vascular resistance in and an increased blood flow through the col-

lapsed lung, there is little doubt that pulmonary vascular resistance is increased in and blood flow markedly reduced through the chronically atelectatic lung. The mechanism of this transition in vascular resistance has not been studied. In one dog (no. 82) this transition was already occurring at 190 minutes (Figure 4). Possible mechanisms for the reduction in blood flow in chronically collapsed lung are *a*) neurogenic effects, *b*) further alterations in surface tension forces, *c*) return of intrathoracic pressure to normal after a gradual reduction in chest volume or a decrease in compliance of the overdistended lung, *d*) further geometric changes assuming that the lung does not become completely atelectatic for several hours, and *e*) chronic organic vascular changes. Organic vascular changes apparently do occur, since a marked increase in vascular resistance persists even after 3 weeks following re-expansion of a chronically collapsed lung (3). The hemodynamic changes that occur with time in atelectatic lung warrant further investigation.

Summary

The response to acute pulmonary atelectasis was studied in fourteen lightly anesthetized dogs breathing spontaneously with chest wall intact. Portions of lung were made atelectatic by endobronchial occlusion.

Acute atelectasis produced a two- to fourfold increase in respiratory minute volume, a decrease in intrathoracic pressure, and an initial fall in pulmonary arterial pressure usually followed by a slight rise. The percentage of cardiac output shunted during acute atelectasis was greater than the percentage of lung tissue collapsed. In contrast, unilateral ventilation with 100% nitrogen or 92.5% nitrogen and 7.5% carbon dioxide reduced the amount of blood flow through the affected lung. Except for a variation in the time of response, there was no difference whether the lung was filled with room air or 100% oxygen before acute collapse.

Constant flow perfusions of innervated pulmonary lobes (negative intrathoracic pressure breathing) revealed a sudden fall in perfusion pressure with acute collapse of the perfused area in five of six preparations. Vagotomy and sympathectomy did not eliminate the response. Di-

rect measurement of pulmonary venous outflow confirmed the increase in blood flow through the acutely collapsed lobe.

After acute endobronchial occlusion in the intact dog, blood flow is initially increased through atelectatic lung as a result of mechanical factors. Mechanisms of this effect are discussed.

Acknowledgments

The author is indebted to Dr. Benjamin Burrows for his suggestions and criticisms and is grateful to William Pitts and David Tidaback for their technical assistance and to Joan Denne for the blood gas analyses.

References

1. Berggren, S. M. The oxygen deficit of arterial blood caused by non-ventilating parts of the lung. *Acta physiol. scand.* 1942, **4** (suppl. 11).
2. Benfield, J. R., R. W. Harrison, J. F. Perkins, Jr., E. T. Long, G. P. Herman, and W. E. Adams. The reversibility of chronic atelectasis. *Surg. Forum* 1958, **8**, 473..
3. Benfield, J. R., E. T. Long, R. W. Harrison, J. F. Perkins, Jr., G. P. Herman, and W. E. Adams. Should a chronic atelectatic lung be reerated or excised? *Dis. Chest* 1960, **37**, 67.
4. Björk, V. O., and E. F. Salén. The blood flow through an atelectatic lung. *J. thorac. Surg.* 1950, **20**, 933.
5. Björk, V. O. Circulation through an atelectatic lung in man. *J. thorac. Surg.* 1953, **26**, 533.
6. Keeley, J. L., and J. G. Gibson II. Experimental atelectasis in dogs; its effect on plasma volume, hemoglobin, hematocrit, blood gases, circulation time, and pulmonary blood flow. *Surgery* 1942, **11**, 527.
7. Peters, R. M., and A. Roos. The effects of atelectasis on pulmonary blood flow in the dog. *J. thorac. Surg.* 1952, **24**, 389.
8. Rosenberg, M. Z. Effects of unilateral collapse of the lung. *Yale J. Biol. Med.* 1952, **25**, 51.
9. Wilson, R. H., R. V. Ebert, C. W. Borden, R. T. Pearson, R. S. Johnson, A. Falk, and M. E. Dempsey. The determinations of blood flow through nonventilated portions of the normal and diseased lung. *Amer. Rev. Tuberc.* 1953, **68**, 177.
10. Aviado, D. M. Effect of acute atelectasis on lobar blood flow. *Amer. J. Physiol.* 1960, **198**, 349.
11. Woodson, R. D., D. E. Raab, and D. J. Ferguson. Pulmonary hemodynamics following acute atelectasis. *Amer. J. Physiol.* 1963, **205**, 53.
12. Niden, A. H., C. Mittman, and B. Burrows. Pulmonary diffusion in the dog lung. *J. appl. Physiol.* 1962, **17**, 885.

13. Van Slyke, D. D., and J. M. Neill. The determination of gases in blood and other solutions by vacuum extraction and manometric measurement. *I. J. biol. Chem.* 1924, **61**, 523.
14. Wyeth, J., P. Ecker, and B. D. Polis. Spectrophotometric determination of blood oxygen saturation. Report No. NADC-MA-5408 U. S. Naval Air Development Center, Johnsville, Pa., 1954.
15. Lategola, M. T., and J. A. Schilling. Modifications of "George Wright," canine tracheal divider. *Proc. Soc. exp. Biol. (N. Y.)* 1958, **99**, 507.
16. Comroe, J. H., Jr., R. E. Forster, A. B. Dubois, W. A. Briscoe, and E. Carlsen. *The Lung*, 2nd ed. Chicago, Yearbook Medical Publishers, 1962, pp. 343-345.
17. Niden, A. H., and D. M. Aviado, Jr. Effects of pulmonary embolism on the pulmonary circulation with special reference to arteriovenous shunts in the lung. *Circulat. Res.* 1956, **4**, 67.
18. Adams, W. E., L. Hrdina, and L. E. Dostal. Vascular changes in experimental atelectasis: morphological, physiological and biochemical. *J. thorac. Surg.* 1935, **4**, 377.
19. Coryllos, P. N., and G. L. Birnbaum. The circulation in compressed, atelectatic and pneumonic lung. *Arch. Surg.* 1929, **19**, 1346.
20. Goodale, W. T., M. Lubin, J. E. Eckenhoff, J. H. Hafkenschiel, and W. G. Banfield, Jr. Coronary sinus catheterization for studying coronary blood flow and myocardial metabolism. *Amer. J. Physiol.* 1948, **152**, 340.
21. Eckenhoff, J. E., J. H. Hafkenschiel, E. L. Foltz, and R. L. Driver. Influence of hypotension on coronary blood flow, cardiac work, and cardiac efficiency. *Amer. J. Physiol.* 1948, **152**, 545.
22. Coryllos, P. N., and G. L. Birnbaum. Studies in pulmonary gas absorption in bronchial obstruction; behavior and absorption times of oxygen, carbon dioxide, nitrogen, hydrogen, helium, ethylene, nitrous oxide, ethyl chloride, and ether in lung, with some observations on pleural absorption of gases. *Amer. J. med. Sci.* 1932, **183**, 326.
23. Niden, A. H., B. Burrows, and W. R. Barclay. Effects of drugs on the pulmonary circulation and ventilation as reflected by changes in the arterial oxygen saturation. *Circulat. Res.* 1960, **8**, 509.
24. Thomas, L. J., Jr., A. Roos, and Z. J. Griffo. Relation between alveolar surface tension and pulmonary vascular resistance. *J. appl. Physiol.* 1961, **16**, 457.
25. Howell, J. B. L., S. Permutt, D. F. Proctor, and R. L. Riley. Effect of inflation of the lung on different parts of pulmonary vascular bed. *J. appl. Physiol.* 1961, **16**, 71.
26. Schleier, J. *Der Energieverbrauch in der Blutbahn.* *Pflügers Arch. ges. Physiol.* 1918, **173**, 172.
27. Burton, A. C., and D. J. Patel. Effect on pulmonary vascular resistance of inflation of the rabbit lungs. *J. appl. Physiol.* 1958, **12**, 239.
28. Permutt, S., J. B. Howell, D. F. Proctor, and R. L. Riley. Effect of lung inflation on static pressure-volume characteristics of pulmonary vessels. *J. appl. Physiol.* 1961, **16**, 64.
29. Thomas, L. J., Jr., Z. J. Griffo, and A. Roos. Effect of negative-pressure inflation of the lung on pulmonary vascular resistance. *J. appl. Physiol.* 1961, **16**, 451.