

THE REJECTION OF SKIN HOMOGRAFTS IN THE NORMAL HUMAN SUBJECT. PART II. HISTOLOGICAL FINDINGS

Laurence Henry, ... , Gustave J. Dammin, John P. Merrill

J Clin Invest. 1962;41(3):420-446. <https://doi.org/10.1172/JCI104496>.

Research Article

Find the latest version:

<https://jci.me/104496/pdf>



THE REJECTION OF SKIN HOMOGRAFTS IN THE NORMAL HUMAN SUBJECT. PART II. HISTOLOGICAL FINDINGS

BY LAURENCE HENRY, DAVID C. MARSHALL, ELI A. FRIEDMAN, GUSTAVE J. DAMMIN AND JOHN P. MERRILL

(From the Departments of Surgery, Medicine, and Pathology, Peter Bent Brigham Hospital and Harvard Medical School, Boston, Mass.)

(Submitted for publication September 7, 1961; accepted October 30, 1961)

Part I of this paper describes the gross changes occurring in the human skin autograft and in the homografts undergoing "first-set," "accelerated," and "white-graft" rejections. Biopsies were taken of each graft at varying intervals; the microscopic appearance of the skin autografts has been described in a separate communication (1). The second part of this paper will give in detail the histological sequence of events in the skin homografts during the various stages of rejection. Thus far these changes have not been described in detail in the healthy, human subject; studies have been carried out in burned patients (2), in uremics (3), and in patients with lymphomas (4), and criteria have been laid down for the acceptance of skin grafts in man (5). However, most recent studies on human skin grafts have been controlled by gross observation with a stereomicroscope rather than by histological methods (6-8). This present work, therefore, arose from a need for such information to control further investigation in the human subject and in the assessment of patients being considered for transplantation surgery.

METHODS

Wedge biopsies of the thickness of the graft were taken at intervals, and in some cases the adjacent host tissues were also included. The material was fixed in 10 per cent buffered formalin, embedded in paraffin, and sectioned at 5 μ thickness. Staining was by hematoxylin and eosin, Verhoeff's elastic stain counterstained with Van Gieson's, periodic acid-Schiff (PAS), and methyl green pyronin methods.

RESULTS

The autograft. For a period of 1 to 2 days after the skin autograft has been placed in position, it has no vascular connections and depends for its nutrition and oxygenation upon a "plasmatic" circulation from the graft bed. In all but a few cases in this study, such a circulation is insufficient to

maintain completely the integrity of the full-thickness graft, and in the first few days changes of varying severity are seen which are related to an impaired circulation and, possibly, to the absence of a neural supply. The efficiency of the plasmatic circulation is governed by the thickness of the graft, the density of the dermal collagen, and the extent of the fibrin clot at the junction of the autograft and graft bed. These factors will also affect the revascularization of the graft and hence the rate of recovery from the earlier ischemic changes.

The capillaries in the upper dermis collapse and the nuclei of the endothelial cells degenerate, although the capillary basement membrane remains intact. Revascularization commences on the second or third day with the appearance of patent blood vessels in the deeper layers of the graft. The superficial capillaries become dilated with blood and this feature persists for a few days until the endothelial cells are reconstituted and the vessels become patent. By Day 6 or 7 the graft has become fully vascularized, but these dilated capillaries can still be seen in isolated areas where the process of vascularization has been delayed.

When the circulation is re-established rapidly, the ischemic changes in the graft are confined to a mild spongiosis and isolated cell necrosis in the epidermis with slight degeneration of the dermal appendages, particularly the sebaceous glands. These changes regress rapidly and by the third or fourth day the graft is normal, apart from a few dead epidermal cells in the stratum spinosum. When revascularization is delayed, however, more extensive damage occurs, which may be severe enough to produce total necrosis and separation of the epidermis on the third or fourth day, and considerable degeneration of the appendages. The damage to the epidermis varies between these two extremes in individual grafts, but even those

showing complete necrosis will recover as revascularization proceeds. A layer of flattened cells arising from surviving epidermis or appendages spreads over the surface of the dermis, and by Day 6 or 7 the basal layer is reconstituted. Thereafter, the epidermis is rapidly reformed and the overlying dead epidermis is gradually shed. The appendages return to normal and by Day 8 recovery is complete.

The dermal collagen remains normal, but during the first few days after grafting there is considerable basophilic debris, possibly nuclear in origin, in the upper dermis. A marked polymorphonuclear leukocytic infiltrate develops, at first in the deeper layers, but later concentrated around necrotic appendages or foci of degeneration in the epidermis. Although this infiltrate may vary in intensity, it is present to some extent in every graft. As the circulation is re-established these leukocytes disappear, and by the sixth day there are few cells present in the dermis.

The epidermal "basement membrane" remains intact. As a structure this membrane seems to be more intimately associated with the dermis than with the epidermis. In areas where the epidermis is elevated from the remainder of the graft this membrane may not be demonstrable, but in most

cases it can still be identified on the denuded surface of the dermis.

The elastic tissue pattern is likewise well maintained, but in those grafts showing severe ischemic damage the fine pattern of subepidermal fibers may be disrupted to a minor extent in some areas.

The graft bed was not studied in every case, but it seems that the nonspecific cellular response can no longer be seen after 4 days. The fibrin clot is resorbed or organized, and by Day 9 newly formed capillaries and fibroblasts may be seen in the deeper layers of the graft, firmly uniting the graft to the bed. By Day 12 all the autografts examined were indistinguishable from normal skin.

Thus, although there is great variation in the extent and duration of the degenerative changes in the autografts, by the sixth day all show evidence of recovery. Subsequent to the eighth day all are fully revascularized with a normal epidermis, although the stigmata of the ischemic episode may persist for a few more days.

First-set homograft. In both animal and human studies it has been shown that the first-set homograft becomes vascularized and that for the first few days the changes are identical with those in an autograft. Two grafts proved to be surgical

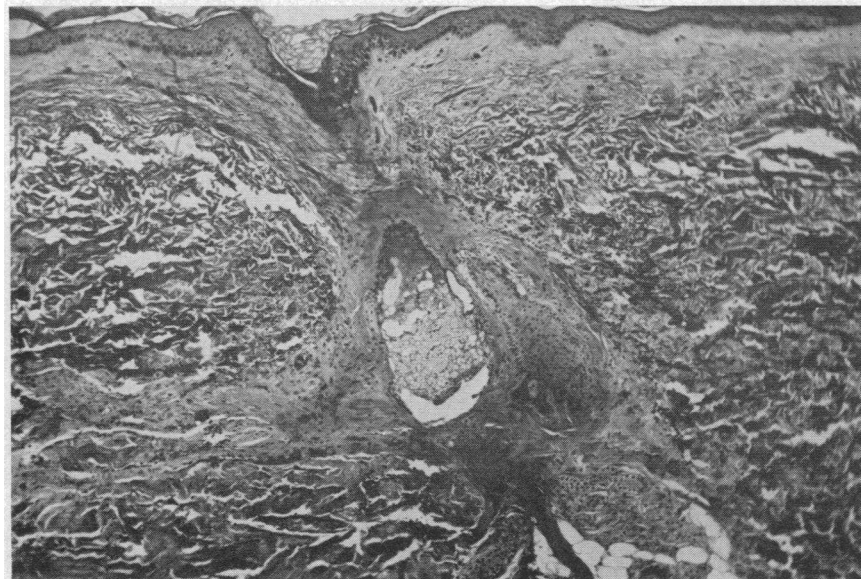

FIG. 1. MR. H.; FIRST-SET HOMOGRAFT; DAY 4. The epidermis is intact but the dermal appendages show mild degenerative changes. There is a diffuse infiltrate of polymorphonuclear leukocytes into the dermis. (H & E $\times 40$)

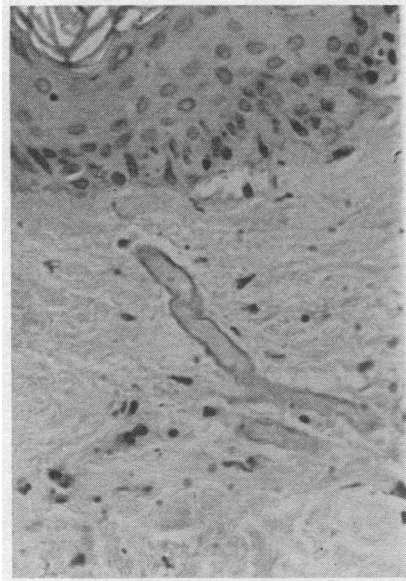


FIG. 2. MR. B.; FIRST-SET HOMOGRIFT; DAY 2. The epidermis shows early degenerative changes but the epidermal basement membrane is intact. The endothelial cells of the capillary in the upper dermis have disappeared but the capillary basement membrane is still present. (PAS $\times 320$)

failures due to an underlying clot which prevented revascularization. These grafts showed rapid necrosis and separation of the dermis with degeneration of the appendages, and will be considered in a later paragraph.

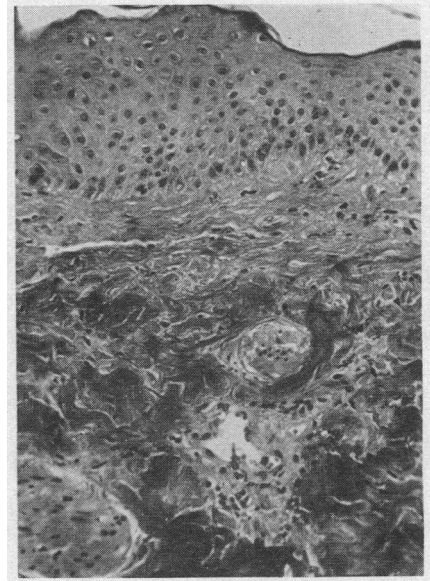


FIG. 3. MR. H.; FIRST-SET HOMOGRIFT; DAY 6. The epidermis is intact. The graft has become revascularized but a few small lymphocytes are present around a small venule in the dermis, constituting the first sign of homograft rejection. (H & E $\times 160$)

The factors affecting the autograft will also modify, in the homograft, the severity and duration of the ischemic changes occurring prior to the re-establishment of the circulation. Thus, in one series of biopsies this damage was minimal and, apart from the necrosis of a few individual cells,

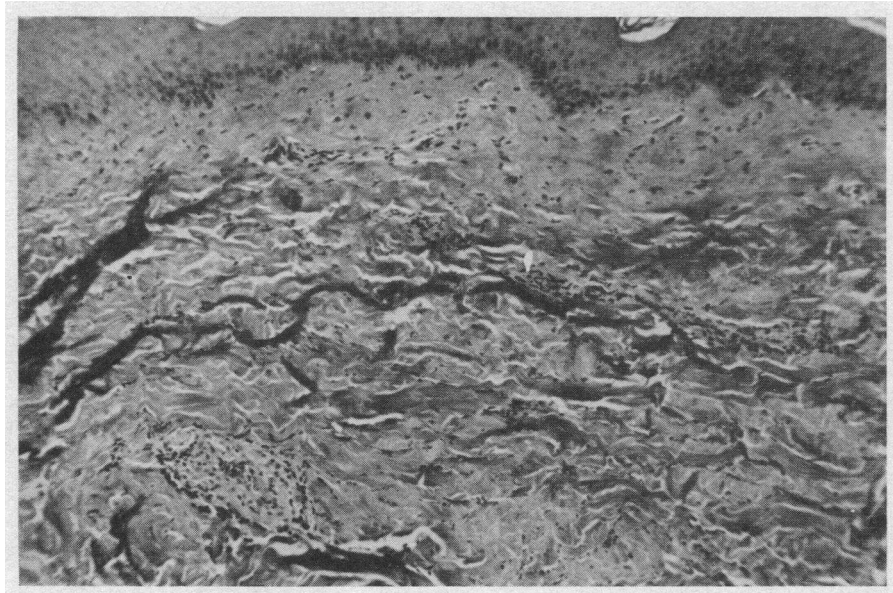


FIG. 4. MR. H.; FIRST-SET HOMOGRIFT; DAY 7. There is now a slightly larger collection of lymphocytes around the small venule in the lower dermis. (H & E $\times 80$)

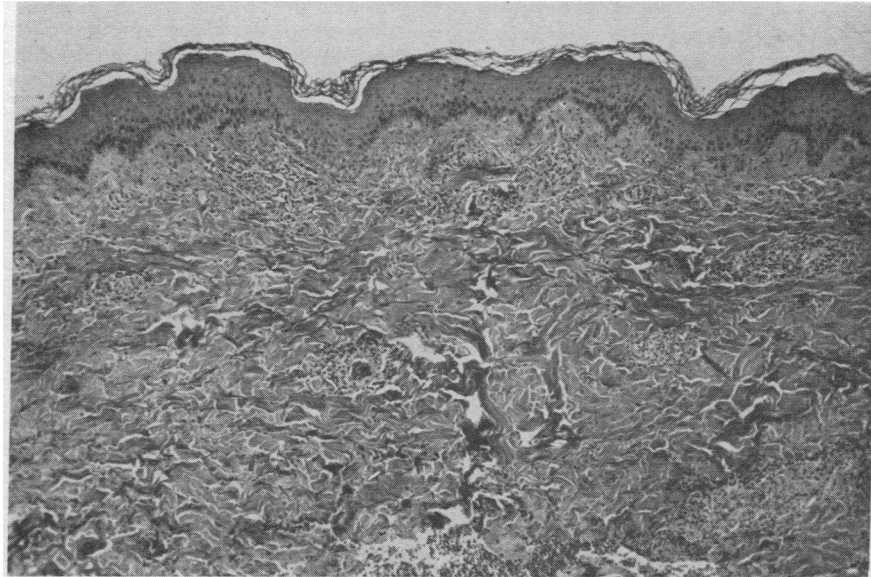


FIG. 5. MR. H.; FIRST-SET HOMOGRAFT; DAY 8. More blood vessels show a cuff of lymphocytes which are spreading into the surrounding dermis. (H & E $\times 40$)

the epidermis was consistently normal. In another series, where the vascular supply was poor, the altered epidermis did not recover and later was encompassed by the specific homograft reaction. However, the majority of biopsies during this period showed focal areas of epidermal degeneration with spongiosis, acantholysis, and vacuolation or

dyskeratosis of individual cells. There was no widespread necrosis of the epidermis, and the basement membrane remained intact. All grafts showed degenerative changes in the dermal appendages, particularly the sebaceous and sweat glands (Figure 1). Here the necrosis was accompanied by a polymorphonuclear leukocytic

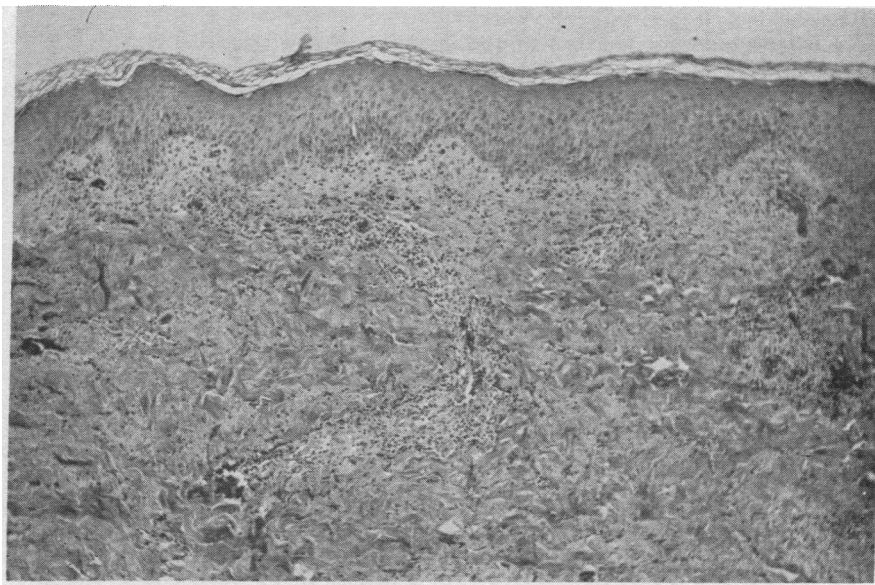


FIG. 6. MR. H.; FIRST-SET HOMOGRAFT; DAY 9. The lymphocytic infiltration has extended into the upper dermis and is approaching the epidermis which is, however, still intact. (H & E $\times 40$)

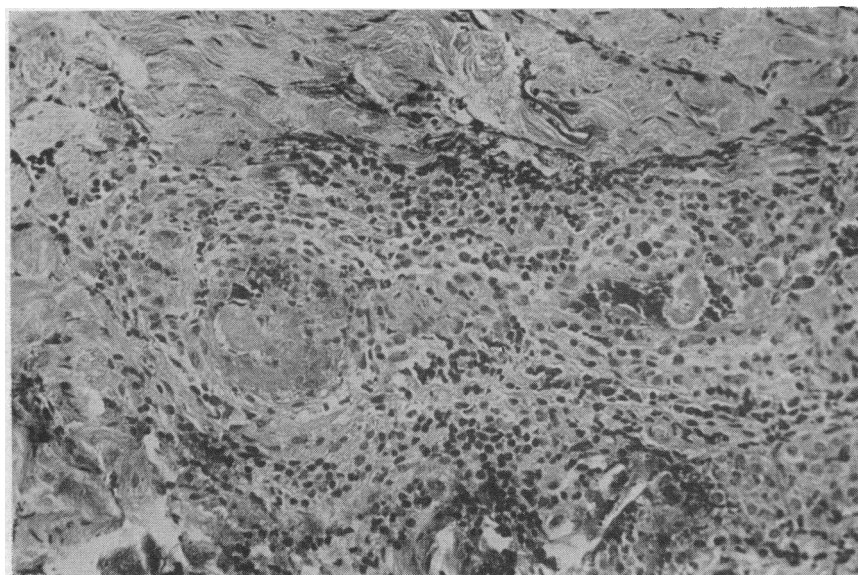


FIG. 7. MR. H.; FIRST-SET HOMOGRAFT; DAY 10. A large venule in the deeper layers of the graft, showing perivascular infiltration with lymphocytes and thrombotic occlusion of the lumen. (H & E $\times 160$)

(PMN) response, often within the limits of the glandular basement membrane but also in the surrounding dermis. The smooth muscle bundles exhibited pyknotic nuclei and separation of the fibers by basophilic material, but with little PMN response. The hair follicles largely reflected the epidermal changes, and the collagen of the dermis remained normal. In addition to the localized collections of PMNs in response to necrosis of the epidermis or appendages, there was invariably a diffuse PMN infiltrate in the dermis. The density of this varied; in general it reached a maximum on the third or fourth day and resolved as the circulation was re-established. There was much debris in the upper dermis and many of the PMNs contained PAS-positive granules.

As in the autografts, the blood vessels in the graft were dilated with blood during the second and third days and, although the capillary basement membrane remained intact, the endothelial nuclei were pyknotic or altogether absent (Figure 2). Revascularization commenced on Day 3 or 4 and was complete on Day 6, except for a few dilated capillaries in the superficial dermis. In these areas the recovery of the epidermis might be delayed but, in general, the epidermis was essentially normal by Day 6, except in one series discussed below. The small blood vessels became

patent and the endothelial cells reappeared, but at this stage no new blood vessels were seen. Up to this point the changes were believed to be related to the ischemia, with no evidence of a specific

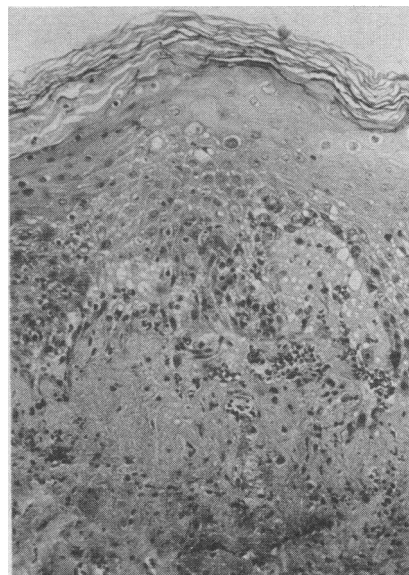


FIG. 8. MR. H.; FIRST-SET HOMOGRAFT; DAY 11. The epidermis shows considerable damage, with spongiosis, nuclear pyknosis, cell vacuolation, and lymphocytic infiltration. Separation from the dermis has occurred. (H & E $\times 160$)

homograft rejection pattern. The first sign of rejection appeared in the deeper layers of the graft, where a few lymphocytes were noted around the small venules (Figures 3 and 4) and the blood vessels supplying the sweat glands. These cells were first seen on Day 6 in three of the grafts and on Days 7 and 9 in two others. In these last two the epidermis had completely recovered from the earlier ischemia, but where the onset of rejection was earlier the epidermis still showed signs of damage. In the remaining graft there was considerable difficulty in revascularization. The epidermis never recovered fully and was still abnormal when the lymphocytic infiltrate appeared, even though this was delayed until the tenth day. Thus it seems that poor vascularization delays the onset of rejection, although not preventing it altogether.

During the days following the appearance of these cells the perivascular infiltration became more pronounced (Figure 5). The smaller vessels in the superficial layers were involved, and the cells extended into the surrounding dermis and dermal papillae to come into contact with the epidermal basement membrane (Figure 6). The

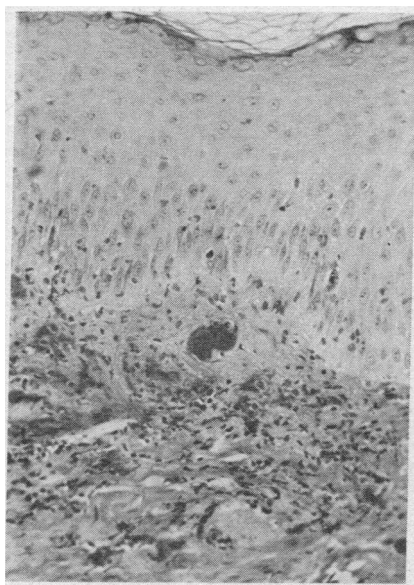


FIG. 9. MR. H.; FIRST-SET HOMOGRAFT; DAY 10. Vascular thrombosis has occurred in the lower layers of the graft. The blood vessels in the upper dermis are distended with blood. There is ecchymosis and lymphocytic infiltration of the surrounding dermis. The epidermis shows some cellular infiltration but is still intact. (H & E $\times 160$)

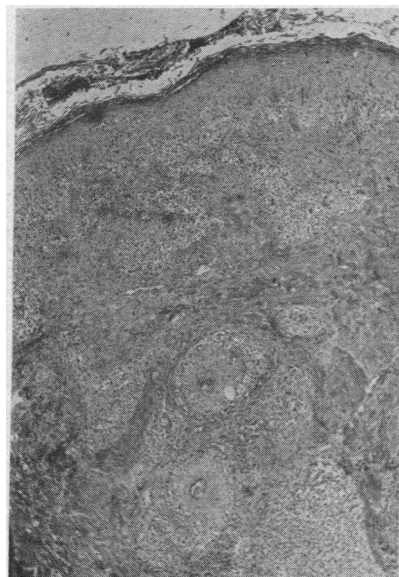

FIG. 10. MR. B.; FIRST-SET HOMOGRAFT; DAY 12. Vascular thrombosis has not yet supervened and the lymphocytic infiltration has increased, involving the epidermis and the hair follicles. (H & E $\times 40$)

sweat glands were surrounded by a dense infiltrate as were the hair follicles in a lesser fashion, but the sebaceous glands and smooth muscle bundles seemed to attract little attention. The cell population was mainly lymphocytic but some histiocytes and eosinophilic leukocytes were seen. Plasma cells were present in very small numbers. Once begun, the development of the infiltrate was progressive, but it was not uniform throughout the whole graft or between grafts on different subjects. Thus, in one series perivascular infiltration was seen on Day 7 but not on Day 8 or 9, although it was present in the biopsy on Day 9 from the duplicate graft on the same volunteer. The lymphocytes continued to accumulate in the dermis, which became edematous, but subsequently the pattern was modified by the onset of vascular thrombosis which occurred at the ninth day or later (Figure 7). Once this occurred, rejection was rapid as far as the epidermis was concerned; this became necrotic, with pyknotic nuclei and eosinophilic cytoplasm, and separated from the dermis (Figure 8). The appendages likewise degenerated. The dermal collagen was less severely affected, but the superficial capillaries once more dilated and there might be considerable ecchymosis in the upper layer of the dermis (Fig-

ure 9). By Day 12 the rejection of the epidermis was complete and the graft became infarcted. Should the vascular thrombosis be delayed, as in the graft on Mr. B., lymphocytes proceeded to invade the epidermis, and by Days 11 and 12 this showed considerable cellular infiltration with spongiosis, cell vacuolation, and areas of subepidermal vesicle formation (Figure 10). However, death of the epidermis did not occur "en bloc," as mitoses were still seen even at this stage. Presumably this pattern represents the logical development of the reaction of the sensitized lymphocytes against the "antigen" in the epidermal cells. In only two of the grafts, however, was this infiltration seen to any extent. In the remainder the specific homograft reaction was abruptly terminated by the thrombosis of the vessels in the deeper layers of the graft.

During the phases of both ischemia and rejection, the epidermal basement membrane retained its integrity remarkably well. Even in areas of marked cellular infiltration it could still be identified and, as in the autografts, when epidermal separation occurred the basement membrane remained on the dermal surface (Figure 11). In the late stages of rejection the membrane disappeared in the presence of severe dermal necrosis

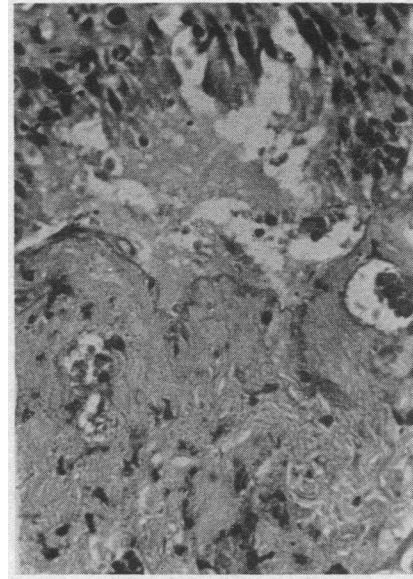


FIG. 11. MR. H.; FIRST-SET HOMOGRAFT; DAY 11. Epidermal separation has occurred but the basement membrane can still be identified on the dermal surface. (PAS $\times 320$)

and hemorrhage, but on the whole it was remarkably resistant.

The elastic tissue likewise survived until a very late stage (Figure 12). In the biopsy on Day 12

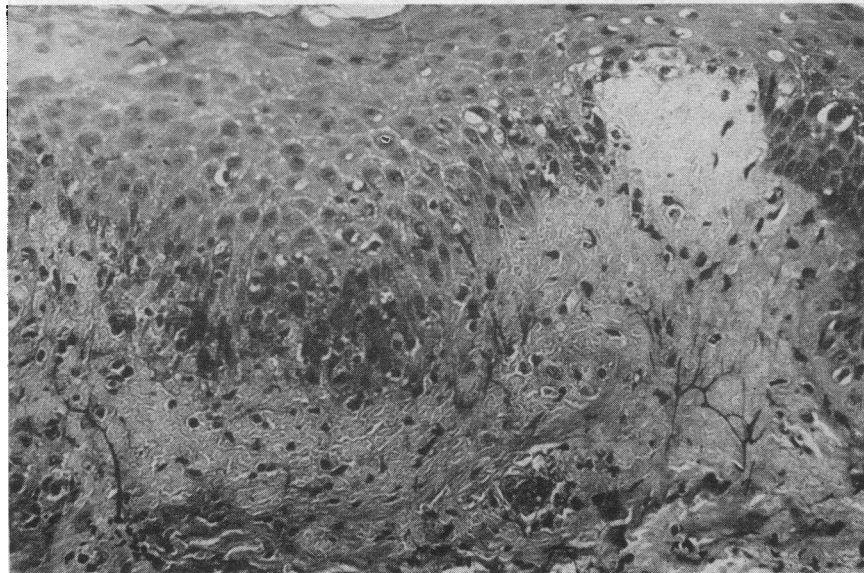


FIG. 12. MR. H.; FIRST-SET HOMOGRAFT; DAY 10. The epidermis shows considerable damage, and separation from the dermis is occurring. There is ecchymosis into the upper dermis, but the fine pattern of elastic fibers is still maintained. (Verhoeff's elastic stain $\times 160$)

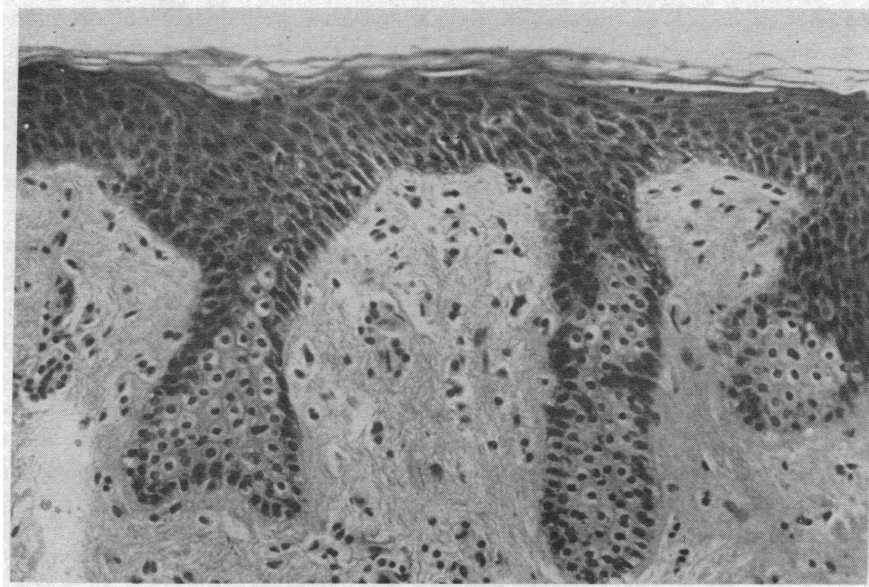


FIG. 13. MR. J.; ACCELERATED REJECTION; DAY 1. Ischemic changes are seen in the rete pegs. (H & E $\times 160$)

from Mr. B. there was a dense cellular infiltrate in the upper dermis and epidermis, but the fine fiber pattern was still maintained. It was not until actual destruction of the dermis had occurred that the pattern became disrupted. During this acute phase of rejection, the elastic tissue in the lower dermis remained normal.

The fibrin clot beneath the graft became invaded by polymorphs in the first few days, but by the fourth day this resolved. As revascularization proceeded, capillary buds must have traversed the graft, but a clear line of separation between the graft and its bed could still be distinguished. It was not until Days 7 to 9 that new blood ves-

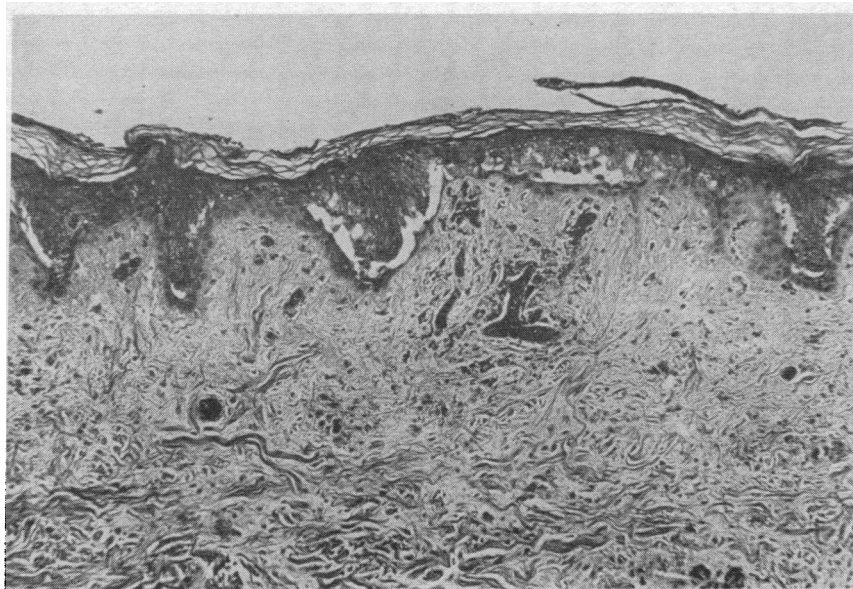


FIG. 14. MR. J.; ACCELERATED REJECTION; DAY 4. The superficial epidermis is dead and separating from the intact basal layer. Dilated blood vessels are present in the upper dermis. (H & E $\times 80$)

sels carrying a loose meshwork of fibroblasts invaded the base of the graft. Thus, before rejection occurred, the graft was firmly united to the host. Islands of squamous epithelium developed at the junction, presumably arising from appendageal remnants in the graft bed. Giant cells were seen, but it is difficult to say whether these are a part of rejection or are a foreign-body reaction.

Thus "rejection" is a combination of two factors: the specific lymphocytic reaction against the cellular elements of the graft, and then a vascular element producing thrombosis. The terminal phases therefore involve ischemia, but before this occurs the pattern and cellular constituents of the dermal infiltrate are quite characteristic for this type of rejection.

Accelerated rejection. The histological findings cover only four examples of typical accelerated rejection. As mentioned in Part I of this paper, the third set of grafts on the last pair of volunteers were rejected as white grafts, which are described in the next section. Biopsies of the graft bed were taken only in this latter series, and thus observations were made only on the deeper dermis during accelerated rejection.

In the first 3 days, however, the grafts themselves were similar to the autograft and the first-set homograft. The epidermis and appendages

showed varying degrees of degeneration. In the biopsies of the graft of Mr. J. this damage was confined to a mild spongiosis and cell vacuolation on the first and second days (Figure 13). The superficial layers of the epidermis were dead by the third day and on the fourth they were separating from the intact basal layer (Figure 14). There were a few PMNs in relation to this dead tissue but, although there was a slight PMN reaction in the dermis around necrotic appendages, this was not well marked. Vascularization commenced on the second day with the appearance of dilated blood vessels in the epidermis (Figure 14). The PMN infiltrate resolved and the epidermis and appendages recovered to some extent, but this was not yet complete when the blood supply was cut off on the fifth day. Thereafter the epidermis underwent "infarct" necrosis, with eosinophilic cytoplasm, pyknosis and "ghosting" of the nuclei, but with no spongiosis and little tendency toward epidermal separation. There was practically no PMN infiltrate in the epidermis and none in the dermis when rejection was complete, on Day 8 (Figure 15).

The biopsies taken from Mr. B. revealed an almost identical pattern. The epidermal damage was minimal on the first day, but on the second there was cell vacuolation, spongiosis and, in this

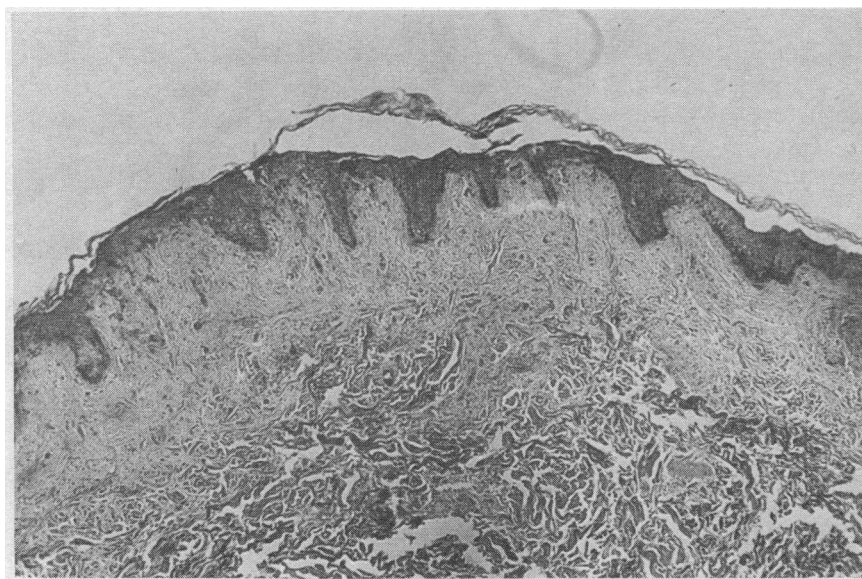


FIG. 15. MR. J.; ACCELERATED REJECTION; DAY 8. The epidermis is dead but remains attached to the dermis. Note the absence of cellular infiltration in the graft. (H & E $\times 40$)

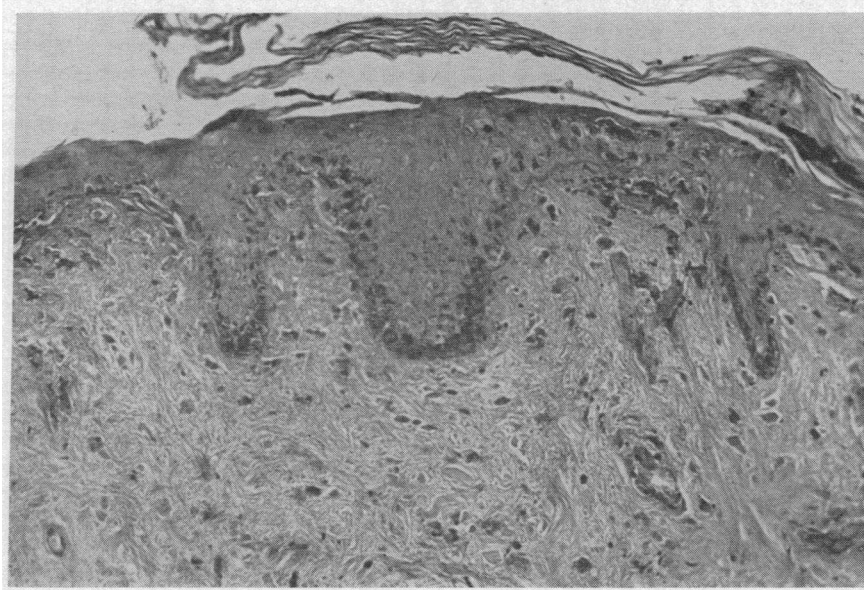


FIG. 16. MR. J.; ACCELERATED REJECTION; DAY 8. The epidermis is dead but the epidermal basement membrane is still intact. (PAS $\times 160$)

series, localized areas of epidermal separation. The superficial layers of dead epidermis separated from the basal layer, as before, on Day 4. There were a few PMNs in the epidermis at this stage, but there was a considerable PMN infiltration of the dermis, especially in the lower layers and around degenerating sebaceous and sweat

glands. The hair follicles and smooth muscle were relatively unaffected. Vascularization again commenced on the second day but, as above, the recovery of the epidermis and resolution of the infiltrate were only partial before rejection supervened. The blood flow ceased on Day 5 and the epidermis rapidly died. There was considerable

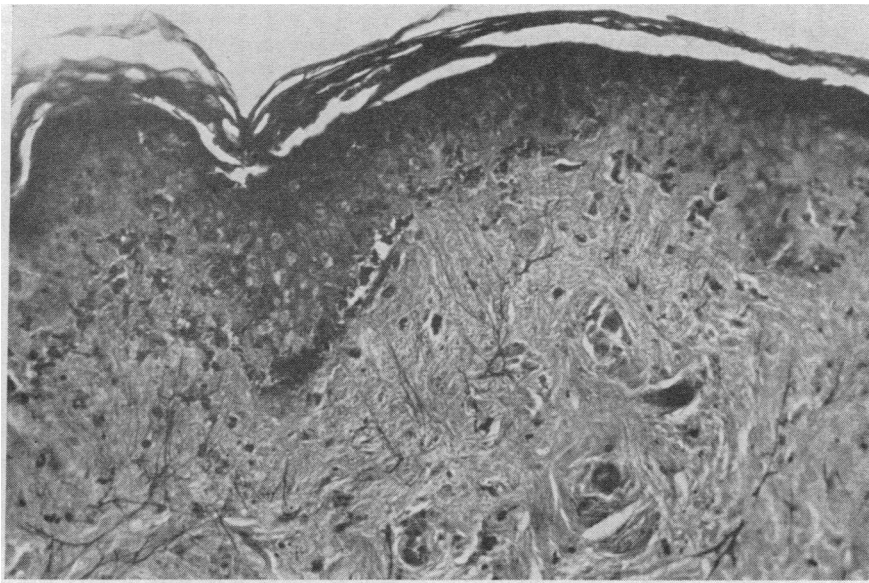


FIG. 17. MR. J.; ACCELERATED REJECTION; DAY 8. The epidermis is dead but the pattern of subepidermal elastic fibers is still well maintained. (Verhoeff's elastic stain $\times 160$)

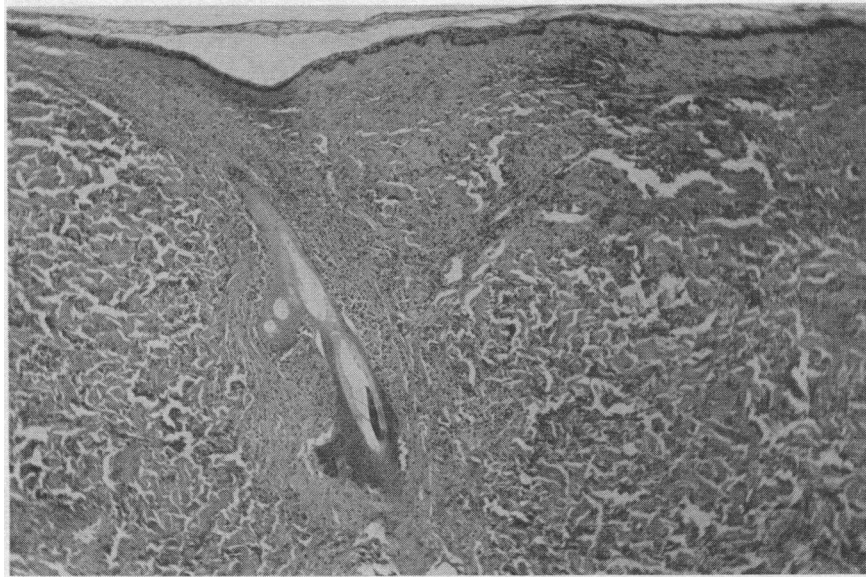


FIG. 18. MR. R. H.; WHITE-GRAFT REJECTION; DAY 6. The dermis is diffusely infiltrated with polymorphonuclear leukocytes. The dermal collagen shows considerable smudging. (H & E $\times 80$)

vascular dilatation in the dermis and much ecchymosis, but no PMNs remained except for a few in the basal layer of the epidermis. Rejection was complete by Day 7.

The biopsies from the other two volunteers showed a somewhat different pattern, since vascularization was more complete. In the graft on Mr. H. there were no epidermal changes in the first two days. On the third day there was cell vacuolation and spongiosis in some areas, with a few isolated PMNs present. There was, however, an intense, diffuse PMN infiltrate in the dermis as is seen in some white grafts, but as the circulation was restored this resolved almost completely. By Day 5 the graft had a normal appearance, apart from a broadened stratum corneum and a focal loss of degenerate superficial epidermis. Subsequently, the blood supply terminated abruptly and by Day 8 rejection was complete.

In Mr. R. there was no epidermal damage in the first three days, vascularization proceeding rapidly after the second day. The few PMNs in the dermis disappeared, except from the lower layers of the graft, and the appendages remained normal. On the fourth day, however, the blood supply was reduced. The epidermis, although still intact, showed a mild spongiosis and there was focal hemorrhage in the lower dermis. The

changes were more marked on the fifth day and on the sixth there was a marked spongiosis, and every epidermal cell was vacuolated. However, the tissue pattern was maintained and there was no separation from the dermis. The appendages

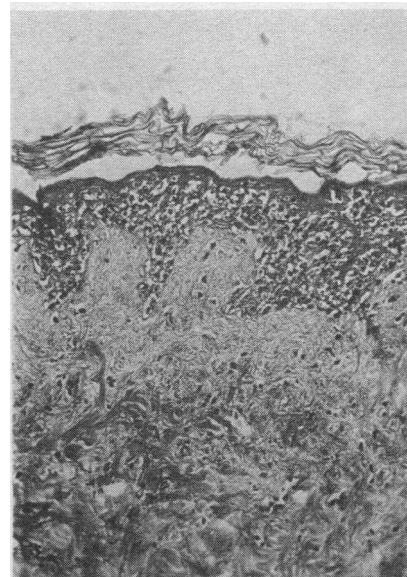


FIG. 19. MR. H.; WHITE-GRAFT REJECTION; DAY 7. There is a diffuse infiltration of the epidermis with polymorphonuclear leukocytes, but few can be seen in the dermis. (H & E $\times 160$)

also showed early degenerative changes, but there was no PMN response in either the dermis or epidermis. No further biopsies were taken, but gross rejection had occurred by Day 7.

Thus the initial epidermal changes and PMN response vary in severity. All the grafts became vascularized and during this process the superficial capillaries were dilated with blood (Figure 14). This finding is not seen in the white graft which never acquires a circulation. The blood supply is maintained for 1 or 2 days, during which partial or complete recovery of the epidermis ensues and the PMN infiltrate resolves. The circulation is then reduced and the graft is infarcted. The epidermis dies but remains *in situ* with little tendency to separate from the dermis. The PMN response in the dermis is slight or absent at this stage, but a few cells may be found in the basal layer of the epidermis. The appendages degenerate, particularly the sebaceous and sweat glands; the hair follicles follow the epidermal changes, and the smooth muscle is not affected until later. Vascularization begins on the second day and reaches a maximum by the fifth day, when it is terminated. Once the blood flow ceases, rejection is rapid and is complete by the eighth day.

The epidermal basement membrane remains intact throughout, but in the later stages becomes

thickened and stains more diffusely with PAS (Figure 16). The elastic tissue pattern is well maintained and on Day 8, when the epidermis is dead, the fine pattern of subepidermal fibers is still present (Figure 17). This stresses the resistance to ischemia of both the basement membrane and the elastic tissue. It is not until actual dissolution of the graft occurs that these are destroyed.

The lower layers of the graft show an infiltrate of PMNs, lymphocytes, eosinophils, and a few plasma cells. No fibroblasts, giant cells, or squamous epithelium are seen.

"White-graft" rejection. As in the previous types of rejection the changes in the first two days are nonspecific in nature, with epidermal necrosis, a dermal PMN infiltrate, and collapse of the superficial capillaries with loss of the endothelial cells. Since the circulation is never re-established these early changes do not regress but, after the third day, become more severe.

The capillaries in the upper dermis do not show the marked dilatation seen in the other grafts during revascularization. The capillary basement membrane remains intact but there is no regeneration of endothelial cells. The epidermis shows an increasing degree of ischemic necrosis, which may resemble that seen in the later

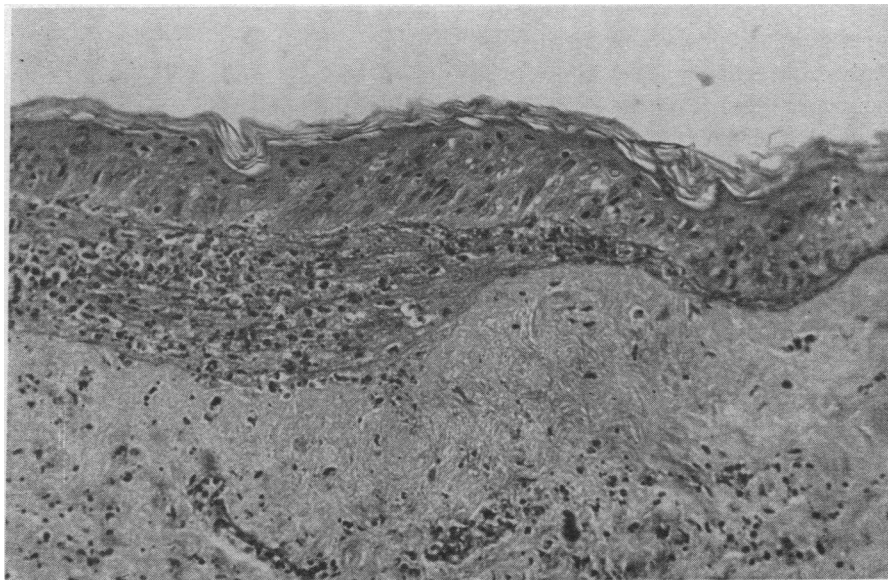


FIG. 20. MR. J.; WHITE-GRAFT REJECTION; DAY 5. There is a collection of polymorph leukocytes dissecting along the plane of the dermoepidermal junction. There is also a diffuse dermal infiltrate of the same type of cell. (H & E $\times 160$).

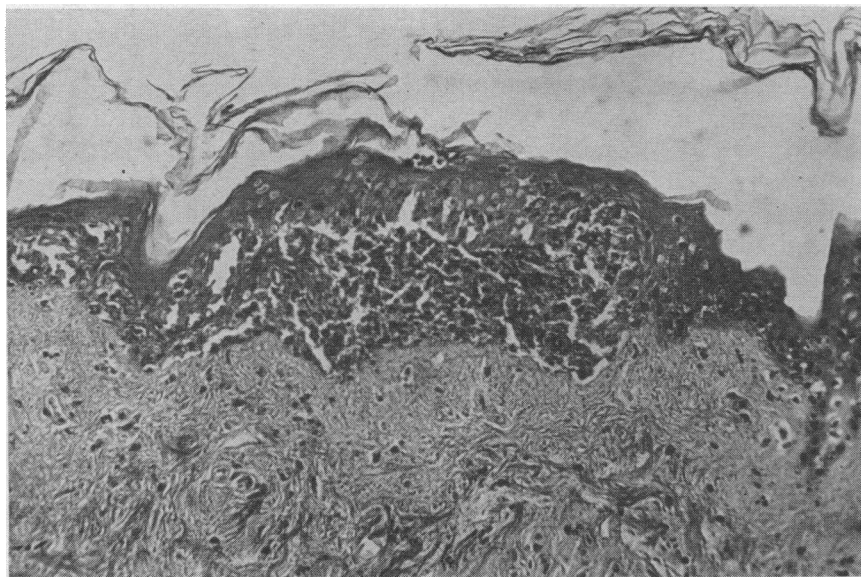


FIG. 21. MR. H.; WHITE-GRAFT REJECTION; DAY 5. A collection of polymorphonuclear leukocytes is present at the dermoepidermal junction. (H & E $\times 160$)

stages of accelerated rejection, but shows more spongiosis, isolated cell necrosis, and vacuolation in the first few days. Subepidermal vesicles are also seen at this time.

A characteristic feature of the white graft is the PMN infiltrate which is always present, even after the fourth day when it is resolving in the other grafts. The extent of this varies among different white grafts, but is always more marked than in accelerated rejection. The infiltrate is first seen in the deeper dermis on the second day, but extends to involve all layers in a patchy, but often intense fashion. The cells may be evenly distributed in the dermis (Figures 18 and 25) or may congregate around necrotic appendages (Figure 27) but have no relation to the blood vessels. The development of the infiltrate is variable; it may rise to a maximum on Day 5 or 6, resolving as rejection progresses, or may persist even until Day 9. A few eosinophils and plasma cells can be identified but no lymphocytes are seen.

The PMNs involve the epidermis in a variety of patterns. There may be a diffuse infiltration, with the PMNs separating the individual cells, producing marked spongiosis, and giving rise to the epidermal softening observed grossly. In the white graft on Mr. H., by Days 4 and 5 there was a diffuse infiltrate, with accumulations of cells in

the upper dermis. By Day 7 the epidermis was dead, with an intense invasion by PMNs and almost complete resolution of the dermal component (Figure 19).

Instead of involving the epidermis itself, the PMNs may collect at the dermoepidermal junction (Figure 26) and spread laterally, dissecting along this plane in a linear fashion (Figure 20). These collections may be focal (Figure 21) but often coalesce and produce the complete separation of the epidermis which is so often noted during the biopsy procedure. This epidermal separation is not seen to any extent in accelerated rejection, where the dead epidermis, or at least the basal layers, tends to remain in contact with the dermis.

These accumulations of PMNs may fail to spread laterally but enlarge locally and produce a type of "microabscess" extending deep into the dermis, with destruction of the overlying epidermis. These lesions contain a mass of PMNs with many strands of basophilic necrotic material (Figure 22). They are seen at some stage in four of the six white grafts and may appear as early as the fourth day. No bacteria can be identified, and it is not considered that these lesions are infective in origin. The microabscesses are not seen during accelerated rejection.

These four patterns of epidermal damage—

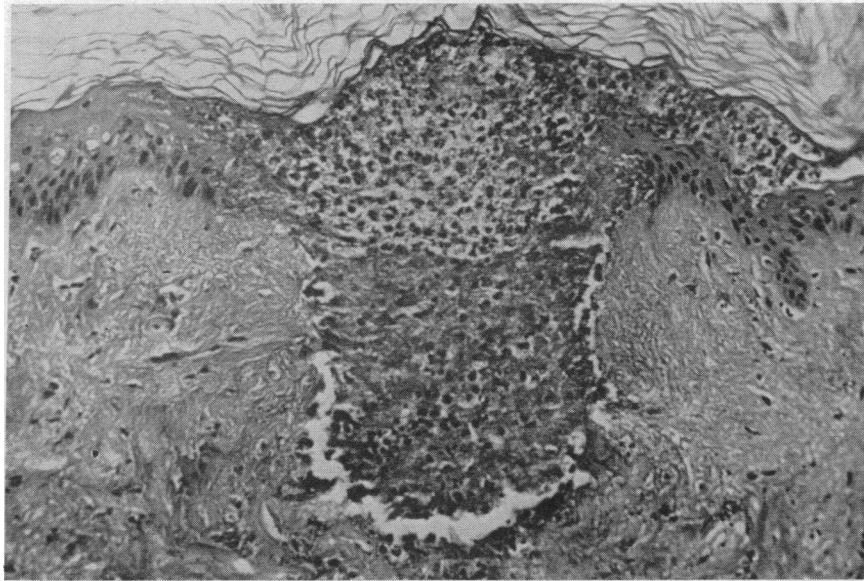


FIG. 22. MR. H.; WHITE-GRAFT REJECTION; DAY 4. A collection of polymorphs with local destruction of both dermis and epidermis forming a "microabscess." (H & E $\times 160$)

pure ischemic necrosis, diffuse cellular infiltration, subepidermal collections of PMNs, or microabscesses—are seen in varying proportions. They may be present in different areas of the graft at the same time or during different stages of the rejection.

At about the sixth day the dermis begins to show smudging and hyalinization of the collagen bundles (Figure 18). This seems to be on an ischemic basis and may excite only a minimal PMN response, the cells tending to accumulate around necrotic appendages. Rejection is pro-

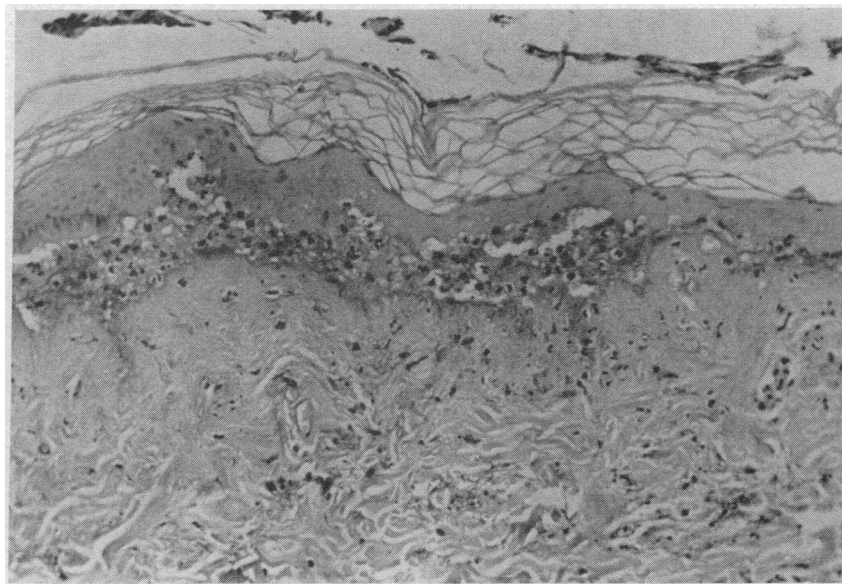


FIG. 23. MR. S.; WHITE-GRAFT REJECTION; DAY 9. The epidermis is dead and is separated from the dermis by polymorph leukocytes. The basement membrane is still intact on the surface of the dermis. (PAS $\times 80$)

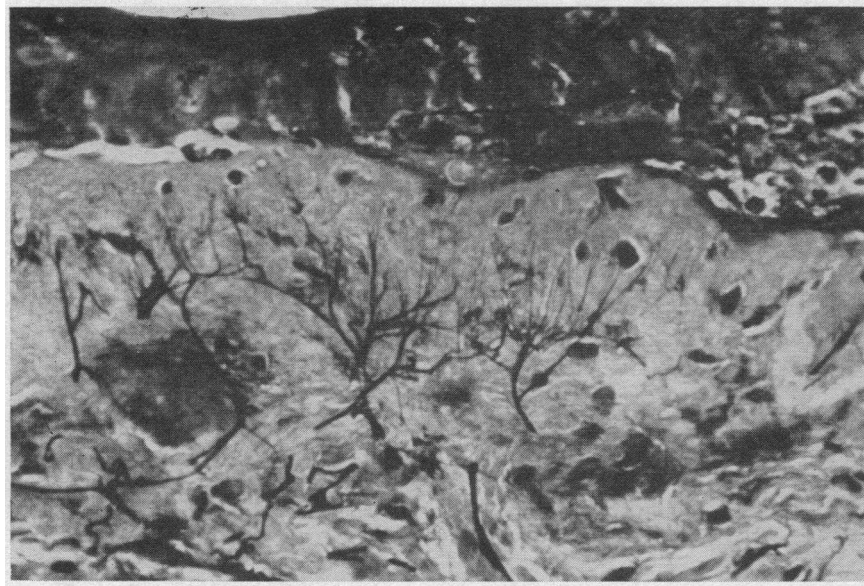


FIG. 24. MR. S.; WHITE-GRAFT REJECTION; DAY 7. The epidermis is dead and the dermal structures undergoing necrosis. The fine pattern of subepidermal elastic fibers is still well preserved. (Verhoeff's elastic stain $\times 320$)

gressive from the second day and is complete by the ninth day when the whole graft is necrotic. There appears to be a more active destruction of tissue than in accelerated rejection where the graft

becomes infarcted with little cellular response in the acute phase.

The epidermal basement membrane remains intact even in the presence of severe PMN infiltra-

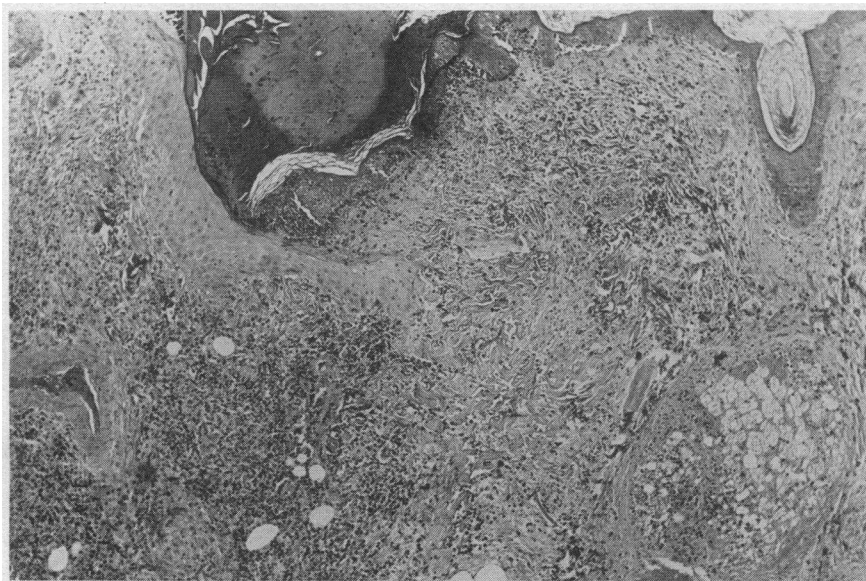

FIG. 25. MR. S.; WHITE-GRAFT REJECTION; DAY 8. The biopsy is taken from the junction of host (to the left) and graft (to the right) tissues. The graft has been rejected, and there is a diffuse polymorph infiltrate in the dermis and in relation to the epidermis and sebaceous glands. No lymphocytes are present in the graft, but there is an intense mononuclear cell reaction in the surrounding host tissues. (H & E $\times 40$)

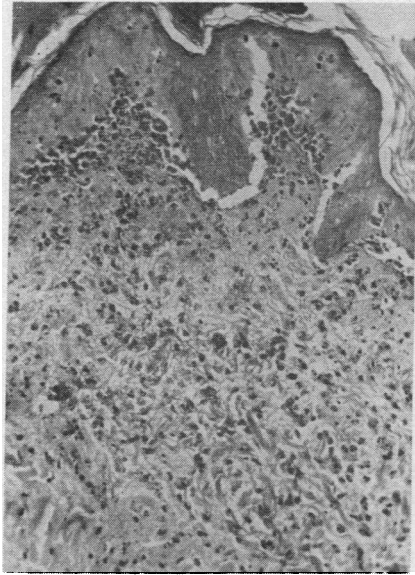


FIG. 26. MR. S.; WHITE-GRAFT REJECTION; DAY 8. The graft shows a diffuse infiltrate of polymorphs which are also accumulating beneath the epidermis. (H & E $\times 160$)

tion. As in the other grafts it is still seen on the dermal surface when epidermal separation occurs (Figure 23). During the later stages of rejection it stains more diffusely with PAS but is not destroyed until dermal necrosis supervenes.

The elastic tissue pattern is likewise well maintained, and when the dermal collagen shows ischemic damage or PMN infiltration, the fine pattern of subepidermal fibers is unaffected (Figure 24). In relation to a microabscess there is localized disruption of the elastic tissue, but the fibers in the deeper dermis remain intact.

Up to the fourth day the graft bed shows little cellular reaction. The fibrin clot contains many PMNs, but there is no attempt to bridge the junction with blood vessels or fibroblasts. There are a few scattered lymphocytes in relation to the smaller blood vessels and the sweat glands, and occasional PMNs can be seen. By Day 8 an intense infiltrate is present in the graft bed (Figure 25), which may surround the graft completely but in other cases may be patchy, leaving areas of the graft bed uninvolved. The relationship to blood vessels is not clear, but the reaction may extend into the surrounding host dermis, where it is mainly perivascular in distribution. The infiltrate is predominantly lymphocytic, but there are many eosinophils and large mononuclear cells, whose nature is in doubt (Figure 28). Plasma cells are present in greater numbers than in the other types of rejection, but still do not form a significant proportion of the cell population.

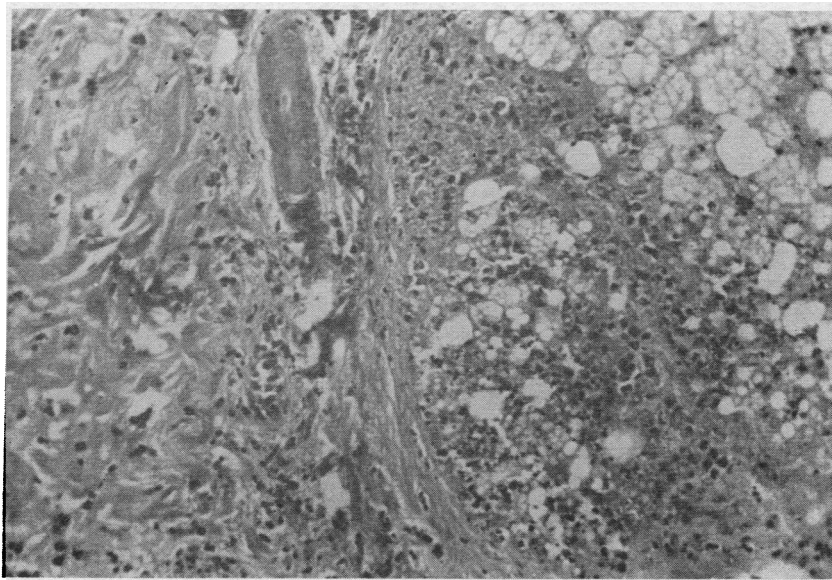


FIG. 27. MR. S.; WHITE-GRAFT REJECTION; DAY 8. A sebaceous gland and sweat duct in the graft show necrosis. There is a polymorph infiltrate in the gland and in the surrounding dermis. (H & E $\times 160$)

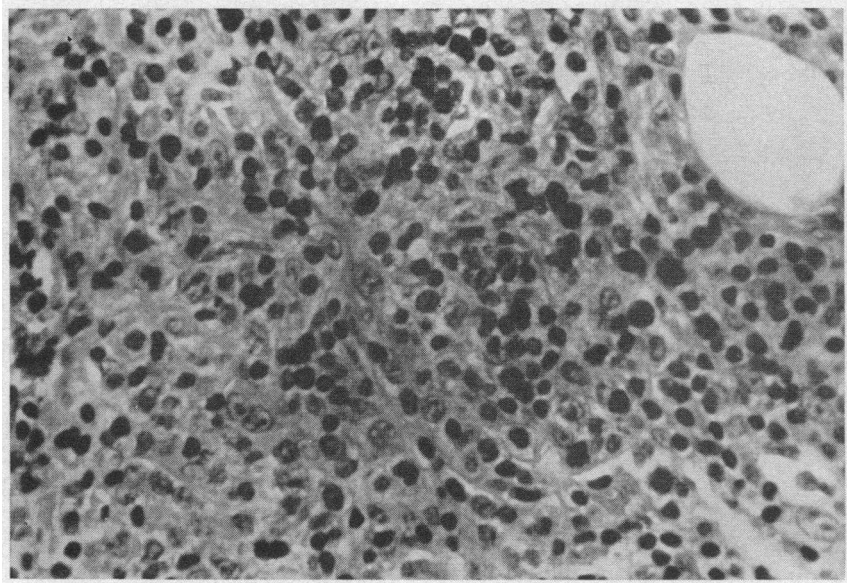


FIG. 28. MR. S.; WHITE-GRAFT REJECTION; DAY 8. Dermal infiltrate in the host tissues in the graft bed. "Reticulum" cells, lymphocytes, eosinophils, and a few plasma cells can be identified. (H & E $\times 480$)

Giant cells are seen rarely, but are not specific for a white graft.

In biopsies of the graft bed in two volunteers, one on the fourth and the other on the eighth day, a medium-sized vein was included. This showed a marked proliferation of endothelial cells, which occluded the lumen, and an infiltration of all layers

of the vessel wall with lymphocytes (Figure 30). There was no thrombosis in the lumen and no necrosis of the vessel wall. The arterioles remained unaffected and could be seen to pass through an area of dense cellular infiltrate without any evidence of arteritis (Figures 25 and 29).

As rejection proceeded, areas of squamous epi-

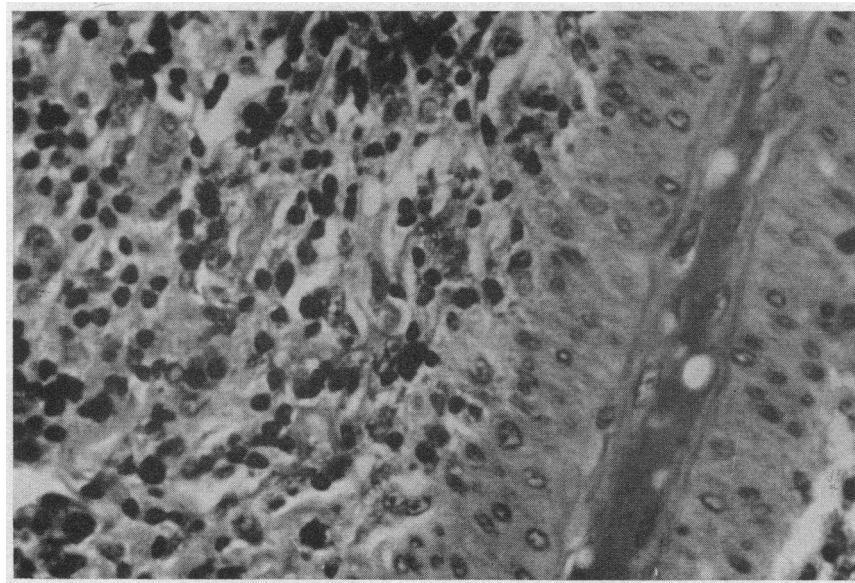


FIG. 29. MR. S.; WHITE-GRAFT REJECTION; DAY 8. A host arteriole is seen passing unaffected through the dermal infiltrate in the graft bed. (H & E $\times 480$)

thelium grew into the graft, presumably arising from appendages in the graft bed. Biopsies were not taken after the ninth day, and the subsequent fate and significance of these areas were not clear. They were not seen in accelerated rejection, but their presence may serve to anchor the white graft to the bed, preventing the scarring and contraction which is less marked than in accelerated rejection.

Although the white graft never becomes vascularized, the necrotic changes are not solely to be explained on a basis of ischemia. The degeneration in the first few days is more marked than in the other grafts and cell death is more rapid. Biopsies of the junction of graft and host epidermis taken on the eighth day showed a sharp delineation between the normal host epithelium and the necrotic tissue of the graft. If ischemia were the sole factor, a surviving rim of graft epidermis might be seen, but this is not the case. This, and the intense PMN response in the early stages have led us to postulate a humoral toxic substance in the circulation. This point will be discussed later.

Thus the white graft never becomes revascularized and shows early epidermal necrosis. There is a diffuse dermal PMN infiltrate and involve-

ment of the epidermis by PMNs in a variety of patterns, with a tendency to separate from the dermis.

Intermediate forms. Although the histological patterns of accelerated and white-graft rejection are characteristic, it was found in fact that occasional grafts showed some features of each, these being termed "intermediate" forms. One of the third-set grafts appeared grossly to undergo accelerated rejection but, although the histology showed that vascularization was in progress, this was never carried to completion, and other features were typical of a white graft.

On the second day the graft showed ischemic changes of the epidermis with a slight PMN reaction in the lower layers of the dermis. The superficial blood vessels were dilated and the endothelial nuclei flattened, indicating the commencement of revascularization. However, on the third day, although vascularization was proceeding in some areas, in other parts of the graft the cellular infiltrate was very marked, with accumulations of PMNs in the upper dermis and destruction of the overlying epidermis. On the fourth day the epidermis showed pure ischemic changes. The blood vessels were still dilated, and revascularization was still incomplete. There were no localized collec-

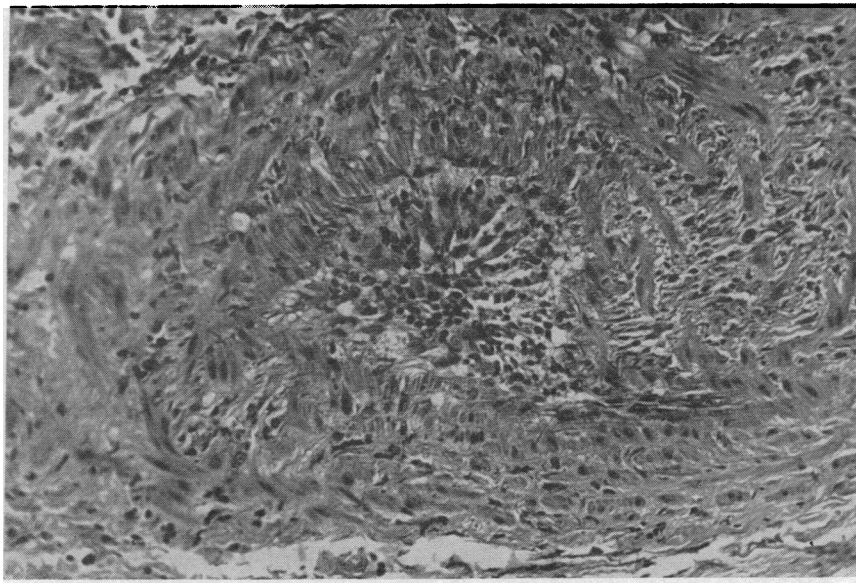


FIG. 30. MR. S.; WHITE-GRAFT REJECTION; DAY 4. A medium-sized vein in the host tissues in the graft bed showing proliferation of the endothelial cells and infiltration of the wall with lymphocytes. The lumen is occluded but there is no evidence of thrombosis. (H & E $\times 160$)



FIG. 31. MR. R. H.; INTERMEDIATE TYPE OF REJECTION; DAY 8. There is a diffuse polymorph infiltrate in the graft dermis and a microabscess in relation to the epidermis. The graft bed shows a mononuclear cell response in the host tissues. (H & E $\times 40$)

tions of cells, but a moderate PMN infiltrate was present in the dermis. By the sixth day the circulation, never adequate, was reduced further, and the graft showed ischemic necrosis of the epidermis, subepidermal PMNs, microabscesses, and an intense diffuse PMN infiltrate in the dermis; i.e., the typical histological features of a white graft (Figure 31).

The graft bed showed also an intense cellular reaction with lymphocytes, eosinophils, large mononuclear cells, and a few plasma cells. In a small vein there was endothelial proliferation and a lymphocytic infiltration in its walls, but no thrombosis.

Although vascularization took place—a characteristic of accelerated rejection—the histology resembled a white graft. The question is raised as to whether a white graft is qualitatively or only quantitatively different from accelerated rejection.

Note on surgical failures. In those grafts which failed to take, owing to an underlying fibrin clot, revascularization did not occur. The graft became infarcted, with necrosis of the dermis and epidermis, but with no PMN response in the graft. It may be that the PMNs were prevented from entering the graft by the fibrin clot, but it

would suggest that the intense infiltrate in the nonvascularized white graft is in response to some factor other than pure ischemic death of tissue.

DISCUSSION

The experience gained from these studies is of value both in human transplantation problems and in the biological questions raised. Owing to the unexpected finding of white-graft rejection in the third-set grafts in one pair of subjects, the graft bed has been most adequately studied in this type of rejection. The rate of progression of the histological changes varies among subjects and may differ in areas of the same graft. This is presumably governed by vascular factors and will be affected by the thickness of the graft, the trauma of repeated biopsies, and the extent of the underlying fibrin clot. Only the acute changes were studied—the first-set grafts up to Day 13, accelerated rejection to Day 8, and the white graft to Day 9.

In general, the various grafts described are indistinguishable from each other during the first two days, showing the epidermal, vascular, and cellular changes described above. The autograft, the first-set homograft, and the grafts showing accelerated rejection all become revascularized, commencing on the second or third day and complete by the fifth or sixth day. Thereafter the autograft returns to normal. After a few days the first-set graft shows perivascular lymphocytic infiltration, which spreads into the dermis and epidermis until vascular thrombosis supervenes, usually on the ninth or tenth day. In accelerated rejection, however, the blood supply is maintained for only 1 or 2 days before it is cut off abruptly, with rapid rejection of the graft thereafter. The white graft never becomes vascularized and the earlier ischemic changes progress, with no sign of the recovery seen in the other grafts.

The varying, and possibly severe ischemic changes seen in even the autografts during the first few days must be emphasized, since they make the interpretation of the biopsies difficult during this period. In two autografts the epidermis became completely necrotic by Day 4, although recovery took place by Day 7 or 8. In two grafts showing accelerated rejection, biopsy revealed an almost normal appearance by Day 5, although re-

jection was complete 3 days later. The specific appearance of first-set rejection is not seen until Day 6 at the earliest, and it is not until this time that the nonspecific changes have resolved, making it possible to identify the type of rejection. In practice, when studying grafts by nonserial biopsies, it is found that biopsies taken on the sixth and ninth days cover the characteristic changes most adequately.

When the cellular elements in the graft are dead, the dermis remains *in situ* for some days before it is destroyed and, except in the white grafts, dermal necrosis does not occur until the late stages. In some instances of chronic rejection it is thought that the dermal elements may persist, being overgrown by host epithelium in a process of "creeping substitution." Therefore the histological criterion of the end point of rejection rests upon the appearance of the epidermis, and rejection is considered to be complete when the epidermis is dead. The epidermal changes are governed by a combination of ischemic, cellular, and possibly toxic factors. In the first-set homograft there may be considerable lymphocytic infiltration of the epidermis, but the cytotoxic effect of these sensitized lymphocytes is slow in operation. The biopsy of the graft on Mr. B. shows mitotic activity in the epidermis on Day 12, even in the presence of considerable cellular infiltration. Rejection is largely vascular, producing spongiosis, cell vacuolation, and subepidermal vesiculation before complete death of the epidermis ensues. White-graft rejection is characterized by spongiosis and PMN infiltration of the epidermis with subepidermal collections of polymorphs. When epidermal separation occurs, it takes place at the dermoepidermal junction, and PMNs may be seen on the under surface of the isolated epidermis. In accelerated rejection the epidermal changes are more ischemic in nature. There is little cellular infiltration apart from a few scattered PMNs, and epidermal separation is less apparent, although some subepidermal vesicles may be present. The epidermis tends to remain *in situ*, and if separation occurs the basal layer is still left on the dermis.

The dermal appendages show a differing sensitivity to the rejection process. The sebaceous and sweat glands are affected at an early stage and the degenerating tissue attracts a degree of

PMN response. The hair follicles largely reflect the epidermal changes, but the smooth muscle bundles are preserved until the late stages of rejection although there may be nuclear pyknosis and separation of the muscle fibers.

The cell population of the graft differs in all types of rejection. The early PMN reaction in the autograft resolves as the circulation is restored, and thereafter there are few cells seen in the dermis until new capillaries and fibroblasts grow in from the graft bed after the first week. Both the first-set homograft and accelerated rejection show a similar resolution but, whereas the first-set graft subsequently shows a progressive perivascular lymphocytic response, the graft showing accelerated rejection is relatively acellular apart from a few scattered polymorphs. The exudate in the first-set graft contains some eosinophilic PMNs, and the possible importance of these has been studied by Rogers, Converse, Taylor and Campbell (9), who also noticed a circulating eosinophilia during rejection. Although there are reports of the role of the plasma cell in rejection (10), these cells are relatively few in number. In white-graft rejection the predominant cells in the graft are the neutrophilic PMNs, the accumulations of which may adopt a variety of patterns, but which are never perivascular in distribution. The cellular response in the graft bed is striking, with a dense infiltrate of lymphocytes, "reticulum" cells, eosinophils, and a moderate number of plasma cells.

The superficial capillaries in all grafts are collapsed immediately after grafting, with loss of the endothelial nuclei but preservation of the basement membrane. Vascularization commences on the second or third day and is complete on the fifth or sixth day, in accord with the findings of Converse and Rapaport (6), who observed the superficial vessels by stereomicroscopy. During this process the capillaries are dilated with stagnant blood. Medawar (11) suggests that these are "wound vessels," fragile capillaries growing in from the graft bed which later degenerate. However, they appear too early for this to be so, and they are more likely to be the original graft capillaries which link up with capillary loops from the bed by the ill defined process of "inosculation" (12). If only one end of a capillary loop is connected at first,

the vessel will fill with blood until the circulation is restored fully, and histologically the disappearance of such dilatation is taken to indicate the completion of vascularization. No empty "rings" of basement membrane can be seen during revascularization, and it is thought that the endothelial lining is reconstituted by growth along existing channels. Vascular thrombosis is seen in the first-set grafts subsequent to the ninth day and is presumably the effect of the rejection process which acts on the endothelial cells. The venous channels are predominantly affected, and this predisposes to the dermal hemorrhage seen in the later stages. The early perivenular response in the first-set graft and the reaction of the larger veins in the bed of the white graft would add to the growing realization of the importance of the venule in inflammatory states (13).

The epidermal basement membrane is well maintained throughout rejection. It remains intact even when the epidermis is completely dead or shows considerable cellular infiltration, although it may stain more diffusely. As a structure, it is to be regarded as a part of the dermis rather than the epidermis (14) and is only destroyed in the presence of dermal necrosis. Dammin, Couch and Murray (3) studied the prolonged survival of grafts in uremic patients and found a deficiency of the basement membrane at the junction of graft and host tissue, although the epidermis had grown over the junction.

The elastic tissue changes are less specific than had been expected. In the biopsies from both first- and second-set grafts taken from a patient being evaluated for renal transplantation and placed on his normal, nonidentical, twin brother (15), both showed considerable damage to the elastic tissue at an early stage. The fine pattern of subepidermal fibers was completely absent, leaving only the larger dermal fibers. These changes were not seen in the present study and the reason for the discrepancy is not obvious. The elastic tissue is resistant to both ischemia and cellular infiltration and, like the basement membrane, seems to require the destruction of the dermis before the pattern is lost. In the studies of Dammin and co-workers (3) on skin grafts in uremic patients, the grafts were rejected more slowly than in the present study. The elastic tissue was absent in

the junctional zone between graft and host tissues, but in the graft itself the pattern of elastic fibers was well maintained.

The gross and histological findings correlate well. The onset of vascularization and the cessation of blood flow can be followed with accuracy in the biopsies. The edema in the graft on the sixth or seventh day corresponds to the appearance of perivascular lymphocytes around the graft blood vessels. The white grafts are obvious grossly, and the lack of vascularization is confirmed microscopically. The softening of the epidermis correlates with the spongiosis and cellular infiltration, and it is probably the subepidermal collections of polymorphs that lead to epidermal separation, since there were no elastic tissue or basement membrane changes. The hardening of the epidermis during accelerated rejection is explained by the "coagulative" necrosis of the epidermis, and the superficial ecchymoses are demonstrable in the sections. In this survey the graft showing an intermediate form appeared grossly as an accelerated rejection, and microscopically as a white graft, but in other studies (16) it has also been shown that grafts may fall between accelerated and white-graft rejection, grossly as well as histologically. The white graft tends to remain *in situ* longer than in accelerated rejection and to heal with less scarring or retraction. This may be due to the anchoring effect of squamous epithelium growing in from the graft bed and the lesser degree of fibroblastic reaction, allowing the dermal elements to be replaced with a minimum of distortion.

Thus from a practical standpoint, the four types of graft can be distinguished histologically if one bears in mind the differing rates of progression of the changes and the range of findings, seen even in the same type of graft, as rejection proceeds.

The biological problems raised in this study are innumerable, and many of them can not be answered by observation of the histological changes alone. For the sensitization of the host there must be a transfer of "antigen" from the graft to the host during the first few days. The site of the antigen and the mechanism of its transfer are by no means clear. The studies of Billingham and Sparrow (17) and Lejeune-Ledant and Albert (18) prove that epidermal cells are antigenic in

the homotransplant system. If the bulk of the antigen is epidermal it must be released into the dermis either as necrotic debris or as a product of cell metabolism. There is, indeed, a great deal of nuclear debris in the dermis in the early stages and as Billingham, Brent and Medawar (19), Mann, Corson and Dammin (20), and others have shown, antigenic activity can be demonstrated in a cell-free tissue extract. However, living cells are a more potent source of antigen than are these extracts, since immunity resulting from a skin graft is still detectable after 240 days, whereas that following the injection of cell-free antigen fades in a matter of weeks (21). There is considerable damage to the graft epidermis while the circulation is being re-established, but this is not constant and seems to have no bearing on the subsequent rejection.

The transport of antigen from graft to host appears to be an active process and not one of mere diffusion. Merwin and Hill (22) found that nonvascularized grafts did not produce immunity in the host nor did grafts in Millipore chambers permitting fluid diffusion but not cellular passage (23-26). In some cases this failure to sensitize may be a dosage phenomenon, as a certain amount of antigen is necessary before immunity develops (27). Small skin grafts survive for longer periods than do large ones (11, 28), although massive skin grafts may show prolonged survival (29). The possibility of lymphatic transfer is raised by Scothorne and McGregor (30). Scothorne (31) emphasized the changes occurring in the regional lymph nodes after skin grafting, and these have a primary importance in the initial stages of sensitization. In skin grafts placed on burned areas, where the superficial lymphatics are destroyed, the onset of rejection is much delayed (2, 32); in one case the graft persisted for 32 weeks (33). Surgical ablation of the regional lymph nodes and lymphatics also prolongs survival (34). McGregor and Conway (35) were unable to detect lymphatic communications before 5 days after grafting, by which time a good degree of immunity has already developed (21). Thus the important lymphatics are those in the graft bed. Antigen may gain access to these by cellular transport. It may be that the polymorph leukocytes seen in the graft during the first few

days are active in this respect, explaining the non-antigenic nature of material in cell-impermeable chambers. Some of this antigen will remain in the graft bed and may produce the "recall flare" on subsequent grafting described by Rapaport and Converse (7).

Vascularization of the graft has been thought to be essential to the sensitization of the host (22) and Lawrence, Rapaport, Converse and Tillett (36) have shown that the nonvascularized white graft does not produce a high enough level of immunity to allow the transfer of this with leukocyte extracts. However, immunity can be detected before vascularization is complete, and McKhann and Berrian (37) found that daily severance of the vascular connections still allowed sensitization to develop. Neither is vascularization essential for rejection. Merwin and Hill (22) found that nonvascularized grafts are rejected in an immune animal, and Algire, Weaver and Prehn (25) showed that if sensitized lymphocytes are included in a Millipore chamber prompt destruction of the graft tissue ensues. In the first-set graft on Mr. J. (in the present study) difficulty in vascularization apparently delayed the onset of rejection. It seems, therefore, that while neither vascularization nor lymphatic drainage is essential, their full establishment facilitates both sensitization and rejection. In a vascularized organ transplant both processes should be rapid, and in a kidney homograft, reduction of function usually occurs on the third or fourth day.

The rejection of the first-set homograft follows a regular pattern. The lymphocytes invade the graft and produce effects on the cellular elements which lead to their eventual death. These elements, however, include the vascular endothelium, and the resulting thrombosis leads to the final ischemic changes. Presumably the delay in vascular occlusion allows the cellular content of the graft to be built up, whereas in accelerated rejection the pre-existing immunity is great enough to produce thrombosis before cellular infiltration of the graft can occur. In white-graft rejection almost no lymphocytes are seen in the graft at any time, in contrast to the intense lymphocytic response in the graft bed. This was also shown by Bauer in guinea pigs (38). The latter cells must be sensitized and reacting against the antigen, but

again the location of this is not easy to see. The lymphocytes never come into contact with the epidermis or appendages and it is doubtful that the dermal collagen is antigenic, although McKhann (39) suggests that the dermis as such is so. The reaction might be against antigen carried from the graft by polymorphs, but Lawrence and co-workers (36) have been unable to demonstrate this transfer in their studies. Possibly the cells are responding to "soluble" antigen diffusing from the graft and, while a certain minimal dose of antigen is necessary to initiate immunity, a lymphocyte, once sensitized, is capable of reacting against very small amounts of antigen.

The white graft is not a new finding, although it was given the name recently by Rapaport and Converse (7). In the study of Gibson and Medawar (2) a second set of grafts was placed on a burned patient before the first-set rejection was complete. These grafts remained white and soft and apparently did not become vascularized. The histology showed collections of "pus" at the dermoepidermal junction, and it is likely that these were true white grafts. Similar results were obtained in rats by Lehrfeld, Taylor and Converse (40). The question is raised whether these grafts are merely an extreme form of "accelerated" rejection or whether there is a qualitative difference. From the early and progressive necrotic changes of both the dermis and epidermis and the intense polymorph response it is felt that in a white graft, much more active destruction of tissue is occurring than in accelerated rejection, where the tissue death is mainly ischemic. This leads us to postulate that at the height of rejection of a first-set homograft a circulating factor is present in the serum, either preventing revascularization or exerting a toxic effect on the graft, or both.

Some parallels have been drawn between homograft rejection and delayed hypersensitivity (41, 42). Gell and Hinde (43) studied the history of the tuberculin reaction in rabbits and noted an early infiltrate of polymorph leukocytes, monocytes, "histiocytes," and a few lymphocytes. Later, the polymorphs disappear and the infiltrate becomes perivascular, mainly involving the small veins. The cell population at 22 hours consists of lymphocytes, monocytes, and large "activated" reticulum cells (44), which would correspond to the large

mononuclear cells seen in this study. Only a few immature plasma cells were seen. The time relationships of these changes are obviously different from those of a first-set rejection pattern, but the distribution of cells and the cell types involved produce a remarkably similar histological picture. This concept is further strengthened by the findings of Merrill, Friedman, Wilson and Marshall (45) that, in a human subject previously sensitized by a skin graft, the intradermal injection of leukocytes from the same donor will produce a reaction of the delayed-hypersensitivity type.

Gell and Hinde also studied the histology of the Arthus reaction (46). They describe an intense perivascular polymorph reaction at the site of injection, which is not necessarily related to tissue necrosis. This infiltration spreads into the dermis, reaches a maximum at 8 hours, and subsequently resolves. By 8 hours there is a perivascular mononuclear reaction at the periphery of the lesion, and by 24 hours these areas have coalesced to form a dense infiltrate of lymphocytes, histiocytes, "transitional" plasma cells, and eosinophils. From the third to the sixth day there is a remarkable transformation into mature and immature plasma cells. It would be interesting to speculate whether white-graft rejection might bear a relationship to the Arthus reaction similar to that between first-set rejection and the "delayed"-type hypersensitivity postulated above. The intense polymorph infiltrate in the white graft is not perivascular, since the graft never acquires a blood supply. However, combined with the mononuclear reaction in the surrounding host tissues with lymphocytes, histiocytes, plasma cells, and eosinophils, a histological pattern is presented not dissimilar to that described for the Arthus reaction. Once again, the development of these changes is slower in white-graft rejection than with soluble antigens, but this may be due to the peculiar mode of presentation of the transplant antigen, contained as it is within a skin graft. The transformation into plasma cells was not seen, but the graft beds were not examined after the eighth day.

Gell and Hinde (46) suggest a dual component to the Arthus reaction—an acute exudative phase mediated by circulating antibody, and a delayed mononuclear response dependent on sensi-

tized cells. The former can be passively transferred by serum and the latter by cells, although the authors could not entirely separate the two elements by this method. If the analogy is pursued, the first-set rejection would be a delayed-type hypersensitivity to an antigen not previously encountered. A circulating antibody produced simultaneously would cause an "Arthus-like" reaction to skin transplanted within a suitable time, the vascular damage preventing vascularization of the graft. The humoral component would cause the rapid tissue death and polymorph infiltration, and the "delayed" component the surrounding mononuclear reaction. When the postulated antibody has reached a low titer, a skin graft will be rejected in an "accelerated" fashion but with only a delayed-type mononuclear response in the graft bed. The intermediate forms would occur when there was a lesser, but still significant titer of antibody circulating. When both the humoral and delayed sensitivity had disappeared after a period of time, a skin graft would once more be rejected in a first-set manner. In other studies (16) it has also been found that some first-set grafts are rejected more slowly than normal, and that in some cases of accelerated rejection a small number of lymphocytes may enter the graft before the blood supply is cut off. These speculations would thus allow a spectrum of histological and gross changes in a graft, ranging from slow rejection of a first-set graft in an unsensitized recipient to the fully developed white graft at the height of immunity.

Circulating antibodies are readily evoked by tumors and by heterografts, but early efforts failed to demonstrate them in a homograft system. More recently a variety of such factors has been found by the use of more sensitive techniques. Antibodies to blood group substances (47), leukocyte agglutinins (48), hemagglutinins (49, 50), and hemolysins (51) have been identified. The presence of these factors is not in doubt, but their role in homograft rejection is less clear (52). Rauch and Favour (53) report success in transferring tuberculin allergy in guinea pigs with large amounts of serum, but similar efforts with homografts have been unsuccessful. Several workers have recently reported finding cytotoxic antibodies after skin grafting in several species (54-57). It

is possible that such a factor, acting on a graft at the height of immunity, might encompass the death of the graft with the failure of revascularization as a secondary phenomenon, although a cytotoxin might conceivably have a primary effect on blood vessels, preventing revascularization in the first place. Stetson and Demopoulos (58) showed that the transfer to a normal animal of hyperimmune serum from an animal given spleen cells in adjuvant could prevent vascularization of a graft from the spleen-cell donor. This would establish the existence of such a factor, but Brent, Brown and Medawar (41) have been unable to confirm these results so far. However, they remain very suggestive and it is possible that the vascular thrombosis even in a first-set graft may be owing to a circulating factor that acts on vascular endothelium rather than the effect of sensitized lymphocytes which have, after all, been passing through the vessel walls for some days before thrombosis occurs. The white graft is usually obtained only within a week or so of the completion of first-set rejection, and the long duration of the response in one pair of patients in this study is of interest.

Thus, this study has been useful, not only in the evaluation of patients for transplantation surgery, but in the light that it sheds upon possible basic mechanisms involved in skin-graft rejection as a biological phenomenon.

SUMMARY

Three sets of skin grafts were placed on normal, healthy, male human volunteers at time intervals designed to produce "first-set," "accelerated," and "white-graft" rejection. Biopsies were taken at appropriate intervals until rejection had occurred and were studied microscopically.

The first-set homograft becomes vascularized, and by the sixth day perivascular lymphocytes are seen around the venules in the lower layers of the graft. The cells spread into the dermis and epidermis until vascular thrombosis supervenes on Days 10 to 12. Rejection is complete shortly thereafter.

In accelerated rejection the second-set graft is vascularized, but the blood flow is maintained for only 1 or 2 days and by Day 8 the graft is rejected, with little evidence of cellular infiltration.

The white graft is never vascularized, and there is a constant but varying degree of infiltration of the dermis and epidermis with polymorphonuclear leukocytes. Phlebitis is seen in the host veins in the graft bed, accompanied by an intense infiltrate of lymphocytes, plasma cells, and eosinophils. The white appearance is seen on the second day and rejection is complete by Day 8.

"Intermediate" forms occur which fall between accelerated and white-graft rejection.

The epidermal basement membrane and the elastic tissue pattern are well maintained until dermal necrosis supervenes.

The biological significance of the various patterns of rejection is discussed, and parallels are drawn between known forms of skin hypersensitivity as seen in "delayed-type" and "Arthus" reactions.

The possible role of a circulating antibody is also considered, and it is thought that the interrelationship of the postulated humoral and cellular factors may explain the occurrence of intermediate forms which show features of both accelerated and white-graft rejection.

Many of these problems must await solution by other than histological means.

ACKNOWLEDGMENTS

Thanks are due to Miss Cynthia Wanstall for her meticulous work in the preparation and staining of the extremely small biopsies obtained in this study; and to Miss Barbara T. Hodges for typing the manuscript.

We are grateful to Ethicon, Incorporated, for assistance in the publication of this manuscript, particularly with reference to defraying the cost of the illustrations.

REFERENCES

- Henry, L., Marshall, D. C., Friedman, E. A., Goldstein, D. P., and Dammin, G. J. A histologic study of the human skin autograft. *Amer. J. Path.* 1961, **39**, 317.
- Gibson, T., and Medawar, P. B. The fate of skin homografts in man. *J. Anat. (Lond.)* 1943, **77**, 299.
- Dammin, G. J., Couch, N. P., and Murray, J. E. Prolonged survival of skin homografts in uremic patients. *Ann. N. Y. Acad. Sci.* 1957, **64**, 967.
- Green, I., and Corso, P. F. A study of skin homografting in patients with lymphomas. *Blood* 1959, **14**, 235.
- Dammin, G. J., and Murray, J. E. Criteria for the acceptance of skin grafts. *Transplant. Bull.* 1959, **6**, 429.
- Converse, J. M., and Rapaport, F. T. The vascularization of skin autografts and homografts. An experimental study in man. *Ann. Surg.* 1956, **143**, 306.
- Rapaport, F. T., and Converse, J. M. Immune response to multiple-set skin homografts: An experimental study in man. *Ann. Surg.* 1958, **147**, 273.
- Rapaport, F. T., Thomas, L., Converse, J. M., and Lawrence, H. S. The specificity of skin homograft rejection in man. *Ann. N. Y. Acad. Sci.* 1960, **87**, 217.
- Rogers, B. O., Converse, J. M., Taylor, A. C., and Campbell, R. M. Eosinophile in human skin homografting. *Proc. Soc. exp. Biol. (N. Y.)* 1953, **82**, 523.
- Darcy, D. A. A study of the plasma cell and lymphocyte reaction in rabbit tissue homografts. *Phil. Trans. B* 1952, **236**, 463.
- Medawar, P. B. The behaviour and fate of skin autografts and skin homografts in rabbits. *J. Anat. (Lond.)* 1944, **78**, 176.
- Thiersch, K. Über die feineren anatomischen Veränderungen bei Aufheilung von Haut auf Granulationen. *Arch. klin. Chir.* 1874, **17**, 318.
- Majno, G., Palade, G. P., and Schoeff, G. I. Studies on inflammation. II. The site of action of histamine and serotonin along the vascular tree: A topographic study. *J. biophys. biochem. Cytol.* 1961, **11**, 607.
- Selby, C. C. An electron microscope study of the epidermis of mammalian skin in thin sections. I. Dermo-epidermal junction and basal cell layer. *J. biophys. biochem. Cytol.* 1955, **1**, 429.
- Merrill, J. P., Murray, J. E., Harrison, J. H., Friedman, E. A., Dealy, J. B., Jr., and Dammin, G. J. Successful homotransplantation of the kidney between nonidentical twins. *New Engl. J. Med.* 1960, **262**, 1251.
- Friedman, E. A., Retan, J. W., Marshall, D. C., Henry, L., and Merrill, J. P. Accelerated skin graft rejection in humans preimmunized with homologous peripheral leukocytes. *J. clin. Invest.* 1961, **40**, 2162.
- Billingham, R. C., and Sparrow, E. M. Studies on the nature of immunity to homologous grafted skin with special reference to the use of pure epidermal grafts. *J. exp. Biol.* 1954, **31**, 16.
- Lejeune-Ledant, G. N., and Albert, F. H. Preparation of a transplantation antigen from epidermal cells. *Ann. N. Y. Acad. Sci.* 1960 **87**, 308.
- Billingham, R. E., Brent, L., and Medawar, P. B. The antigenic stimulus in transplantation immunity. *Nature (Lond.)* 1956, **178**, 514.
- Mann, L. T., Jr., Corson, J. M., and Dammin, G. J. Homotransplant antigens: Preparation of active cellular fractions. *Nature (Lond.)* 1960, **187**, 774.

21. Billingham, R. E., Brent, L., Brown, J. B., and Medawar, P. B. Time of onset and duration of transplantation immunity. *Transplant. Bull.* 1959, **6**, 410.
22. Merwin, R. M., and Hill, E. L. Fate of vascularized and nonvascularized subcutaneous homografts in mice. *J. nat. Cancer Inst.* 1954, **14**, 819.
23. Algire, G. H., Weaver, J. M., and Prehn, R. T. Growth of cells *in vivo* in diffusion chambers. I. Survival of homografts in immunized mice. *J. nat. Cancer Inst.* 1954, **15**, 493.
24. Prehn, R. T., Weaver, J. M., and Algire, G. H. The diffusion-chamber technique applied to a study of the nature of homograft resistance. *J. nat. Cancer Inst.* 1954, **15**, 509.
25. Algire, G. H., Weaver, J. M., and Prehn, R. T. Studies on tissue homotransplantation in mice, using diffusion-chamber methods. *Ann. N. Y. Acad. Sci.* 1957, **64**, 1009.
26. Woodruff, M. F. A. Cellular and humoral factors in the immunity to skin homografts: Experiments with a porous membrane. *Ann. N. Y. Acad. Sci.* 1957, **64**, 1014.
27. Mann, L. T., Jr., Corson, J. M., and Dammin, G. J. Method for the study of antigenicity of homologous whole spleen cells in mice. *Science* 1959, **130**, 1707.
28. Lehrfeld, J. W., and Taylor, A. C. The dosage phenomenon in rat skin homografts. *Plast. reconstr. Surg.* 1953, **12**, 432.
29. Zotikov, E. A., Budik, V. M., and Puza, A. Some peculiarities of the survival time of skin homografts. *Ann. N. Y. Acad. Sci.* 1960, **87**, 166.
30. Scothorne, R. J., and McGregor, I. A. Cellular changes in lymph nodes and spleen following skin homografting in the rabbit. *J. Anat. (Lond.)* 1955, **89**, 283.
31. Scothorne, R. J. Studies on the response of the regional lymph node to skin homografts. *Ann. N. Y. Acad. Sci.* 1957, **64**, 1028.
32. Longmire, W. P., Jr., Stone, H. B., Daniel, A. S., and Goon, C. D. Report of clinical experiences with homografts. *Plast. reconstr. Surg.* 1947, **2**, 419.
33. Kay, G. D. Prolonged survival of a skin homograft in a patient with very extensive burns. *Ann. N. Y. Acad. Sci.* 1957, **64**, 767.
34. Stark, R. B., Dwyer, E. M., and De Forest, M. Effect of surgical ablation of regional lymph nodes on survival of skin homografts. *Ann. N. Y. Acad. Sci.* 1960, **87**, 140.
35. McGregor, I. A., and Conway, H. Development of lymph flow from autografts and homografts of skin. *Transplant. Bull.* 1956, **3**, 46.
36. Lawrence, H. S., Rapaport, F. T., Converse, J. M., and Tillett, W. S. Transfer of delayed hypersensitivity to skin homografts with leukocyte extracts in man. *J. clin. Invest.* 1960, **39**, 185.
37. McKhann, C. F., and Berrian, J. H. Time relationships in the induction of transplantation immunity. *Transplant. Bull.* 1959, **6**, 428.
38. Bauer, J. A., Jr. Histocompatibility in inbred strains of guinea pigs. *Ann. N. Y. Acad. Sci.* 1958, **73**, 663.
39. McKhann, C. F. Studies of the dermis in skin homografts. *Ann. Surg.* 1960, **152**, 284.
40. Lehrfeld, J. W., Taylor, A. C., and Converse, J. M. Observations on the second and third set skin homografts in the rat. *Plast. reconstr. Surg.* 1955, **15**, 74.
41. Brent, L., Brown, J. B., and Medawar, P. B. Skin transplantation immunity in relation to hypersensitivity reactions of the delayed type *in Biological Problems of Grafting, A Symposium.* Oxford, Blackwell, 1959, p. 64.
42. Lawrence, H. S. Similarities between homograft rejection and tuberculin-type allergy: A review of recent experimental findings. *Ann. N. Y. Acad. Sci.* 1957, **64**, 826.
43. Gell, P. G. H., and Hinde, I. T. Histology of the tuberculin reaction and its modification by cortisone. *Brit. J. exp. Path.* 1951, **32**, 516.
44. Marshall, A. H. E., and White, R. G. Reactions of reticular tissues to antigens. *Brit. J. exp. Path.* 1950, **31**, 157.
45. Merrill, J. P., Friedman, E. A., Wilson, R. E., and Marshall, D. C. The production of "delayed type" cutaneous hypersensitivity to human donor leukocytes as a result of the rejection of skin homografts. *J. clin. Invest.* 1961, **40**, 631.
46. Gell, P. G. H., and Hinde, I. T. Observations on the histology of the Arthus reaction and its relation to other known types of skin hypersensitivity. *Int. Arch. Allergy* 1954, **5**, 23.
47. Amos, D. B., Gorer, P. A., and Mikulska, Z. B. An analysis of the antigenic system in the mouse (the H-2 system). *Proc. roy. Soc. B* 1956, **144**, 369.
48. Amos, D. B. The agglutination of mouse leucocytes by iso-immune sera. *Brit. J. exp. Path.* 1953, **34**, 464.
49. Gorer, P. A. The genetic and antigenic basis of tumour transplantation. *J. Path. Bact.* 1937, **44**, 691.
50. Gorer, P. A. The antigenic basis of tumour transplantation. *J. Path. Bact.* 1938, **47**, 231.
51. Hildemann, W. H. A method for detecting hemolysins in mouse isoimmune serums. *Transplant. Bull.* 1957, **4**, 148.
52. Hildemann, W. H., and Medawar, P. B. Relationship between skin transplantation immunity and the formation of humoral isoantibodies in mice. *Immunology* 1959, **2**, 44.
53. Rauch, H. C., and Favour, C. B. Passive transfer of allergic reactions to tuberculin with plasma protein fractions from hypersensitive guinea pigs. *Ann. N. Y. Acad. Sci.* 1960, **87**, 231.

54. Merrill, J. P., Hanau, C., and Hawes, M. D. A demonstration of a cytotoxic effect *in vitro* following the rejection of skin grafts by the rabbit. *Ann. N. Y. Acad. Sci.* 1960, **87**, 266.
55. Terasaki, P. I., Cannon, J. A., Longmire, W. P., Jr. and Chamberlain, C. C. Antibody response to homografts: V. Cytotoxic effects upon lymphocytes as measured by time-lapse cinematography. *Ann. N. Y. Acad. Sci.* 1960, **87**, 258.
56. Gorer, P. A., and O'Gorman, P. The cytotoxic activity of isoantibodies in mice. *Transplant. Bull.* 1956, **3**, 142.
57. Stetson, C. A., and Jensen, E. Humoral aspects of the immune response to homografts. *Ann. N. Y. Acad. Sci.* 1960, **87**, 249.
58. Stetson, C. A., Jr., and Demopoulos, R. Reactions of skin homografts with specific immune sera. *Ann. N. Y. Acad. Sci.* 1958, **73**, 687.

ANNOUNCEMENT OF MEETINGS

The Nineteenth Annual Meeting of THE AMERICAN FEDERATION FOR CLINICAL RESEARCH will be held in Atlantic City, N. J., on Sunday, April 29, 1962 at 9:00 a.m. at the Casino Theatre on the Steel Pier. On Sunday afternoon, April 29, 1962, joint sectional meetings with The American Society for Clinical Investigation will be held in rooms in Chalfonte-Haddon Hall; and on Sunday evening, additional meetings will be held under the auspices of The American Federation for Clinical Research, in Chalfonte-Haddon Hall.

The Fifty-fourth Annual Meeting of THE AMERICAN SOCIETY FOR CLINICAL INVESTIGATION, INC., will be held in Atlantic City, N. J., on Sunday afternoon, April 29, 1962, in Chalfonte-Haddon Hall in simultaneous programs sponsored in conjunction with The American Federation for Clinical Research; and on Monday, April 30, at 9:00 a.m. at the Casino Theatre on the Steel Pier.

THE ASSOCIATION OF AMERICAN PHYSICIANS will hold its Seventy-fifth Annual Meeting at Atlantic City, N. J., at the Casino Theatre on the Steel Pier on Tuesday, May 1, 1962, at 9:30 a.m., and in the Vernon Room, Chalfonte-Haddon Hall on Wednesday, May 2, 1962, at 9:30 a.m.