

The Dynamics of Swallowing. I. Normal Pharyngeal Mechanisms

Michael Atkinson, ... , Stanley M. Wyman, Franz J. Ingelfinger

J Clin Invest. 1957;**36**(4):581-588. <https://doi.org/10.1172/JCI103457>.

Research Article

Find the latest version:

<https://jci.me/103457/pdf>



THE DYNAMICS OF SWALLOWING. I. NORMAL PHARYNGEAL MECHANISMS

By MICHAEL ATKINSON, PHILIP KRAMER, STANLEY M. WYMAN, AND FRANZ J. INGELFINGER

(From the Evans Memorial, Massachusetts Memorial Hospitals and the Department of Medicine, Boston University School of Medicine, and the Massachusetts General Hospital, and the Department of Radiology, Harvard Medical School, Boston, Mass.)

(Submitted for publication October 5, 1956; accepted December 7, 1956)

Swallowing is a complex mechanism in which the functions of the central and autonomic nervous systems are integrated to produce a smooth and speedy transference of the bolus from the mouth to the stomach. The pharyngeal phase of deglutition is the most rapid, being usually of less than a second's duration, and for this reason has been difficult to analyze fully.

The forces involved in the propulsion of the bolus through the pharynx have been a source of controversy. Some have maintained that the bolus is advanced under positive pressure by the action of the muscles of the tongue and pharynx (1, 2); yet others have postulated negative intrapharyngeal pressures (3), in particular Barclay (4), who believed that, after preliminary elevation, the pharynx suddenly descended thereby sucking the bolus downward. Barclay's concepts have few adherents today, but transient negative pressures, uncertain as to origin and purpose, do appear during swallowing. Recently, for example, Fyke and Code (5) have recorded positive pressures from the upper pharynx and negative ones from the cricoid level on swallowing.

It is generally assumed that the pharynx in the resting state is closed off from the esophagus, and although the existence of an anatomical sphincter in this region is controversial, the lower part of the inferior constrictor and perhaps the adjoining circular muscle of the esophagus are believed to perform this function (6, 7).¹ A cricopharyngeal sphincter has been demonstrated radiographically by Templeton and Kredel (8) and its functioning has been illustrated by cinefluorography by Ramsey, Watson, Gramiak, and Weinberg (9). Whether the cricopharyngeus represents a true

sphincter with powers of active relaxation and contraction, or whether it functions in a passive manner, as some have assumed (8), is debatable. Radiographic techniques have been of limited value in deciding this question, as the area has been studied principally by observing the passage of barium, whereas many of the dynamics of swallowing precede the bolus. Also, radiography yields only indirect information about the forces concerned in the movement of the bolus.

To investigate the mechanism of swallowing and the nature and magnitude of the forces involved, we have recorded intraluminal pressures simultaneously from three levels in the pharynx and esophagus. At the same time rapid serial radiographs have been taken to enable interpretation of pressure records in terms of anatomical function and movement of the bolus. These observations form the basis of this report.

METHODS

Intrapharyngeal pressures were recorded through water-filled, open-ended polyethylene tubes attached to Sanborn electromanometers and a four-channel, direct-writing Sanborn recorder. For measuring resting pressures in the pharynx and upper esophagus, a single tube was used. This tube had an inside diameter of 1.7 mm. and was equipped with a metal tip to enable radiographic visualization. A small strip of lead was attached to the skin over the cricoid cartilage to act as a marker in the radiographic localization of the position of the tube. With the subject supine, the tube was inserted into the mid-esophagus to the 30 cm. mark. Then, under fluoroscopic control, it was withdrawn centimeter by centimeter, and intraluminal pressures were recorded in the esophagus and pharynx at each level.

For measuring swallowing complexes, three such tubes were fastened together so that the distance between the distal and middle tips was 2 cm., and that between the middle and proximal tips 4 cm. These tubes were inserted into the pharynx and esophagus through the nose.

Polyethylene tubes rather than nylon cardiac catheters were used because their flexibility permitted them to

¹The terms "cricopharyngeus" and "cricopharyngeal sphincter" are hereafter used to include the entire sphincteric mechanism.

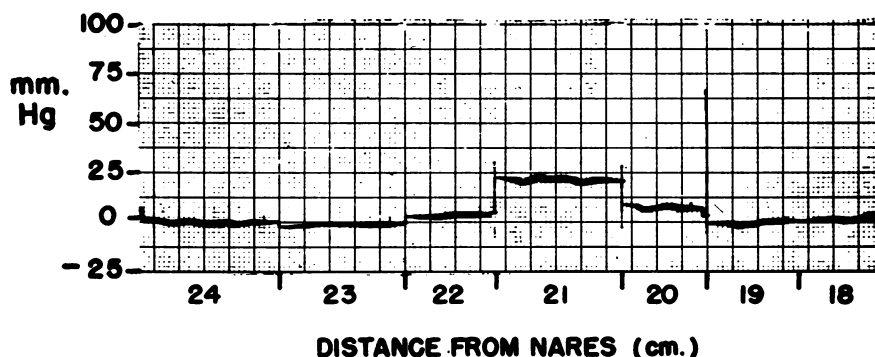


FIG. 1. RESTING INTRALUMINAL PRESSURES IN THE ESOPHAGUS AND PHARYNX OBTAINED BY INSERTING THE RECORDING TIP INTO THE UPPER ESOPHAGUS AND WITHDRAWING CENTIMETER BY CENTIMETER

The zone of high resting pressure at the cricoid level is demonstrated.

move up and down with the pharynx during swallowing. Hence, their tips remained in a relatively constant position with respect to the pharyngeal and esophageal wall. In addition, their flexibility greatly reduced discomfort from pharyngeal irritation. In preliminary experiments simultaneous recordings were made with a polyethylene tube and a nylon catheter fastened together with their tips at the same level. The records obtained were identical, and therefore the compressibility of the polyethylene tubing was not such as to alter the record.

Studies were made upon fasting subjects in both the sitting and supine positions. When the subject was supine, the posterior border of the cricoid cartilage was taken as the point of zero pressure. With the subject sitting, the zero points were adjusted to the heights of the recording tips. In this way absolute pressures were determined with sufficient accuracy to permit comparison

of pressures at the three recording sites. Swallows of 10 to 20 ml. of water, or barium suspension, or small quantities of chewed or unchewed bread were used.

Serial radiographs were taken in the anteroposterior and lateral planes at speeds of 6 to 12 per second by means of an Elema machine using 12-inch roll film. The following radiographic factors were employed: 300 ma, 110 Kv, 1/60 sec. A lead, taken from the primary winding of the transformer for the lateral X-ray tube and passed through a transformer resistance box, was fed into the fourth channel of the recorder. In this way, the exact times of exposure of the films in relationship to intraluminal pressure changes were recorded.

Pressure records from the pharynx and upper esophagus were obtained in 30 healthy male subjects; in 22, pressures alone were measured, and in 8, simultaneous pressure measurements and radiographic studies were made.

TABLE I

Resting intraluminal pressures (mm. Hg) at the junction of pharynx and esophagus

Subject	Esophagus			Pharynx	
	2 cm. below cricoid	1 cm. below cricoid	At cricoid	1 cm. above cricoid	2 cm. above cricoid
O. P.	-10	10	8	2	0
A. R.	-4	60	20	5	2
C. T.	2	22	30	7	2
V. G.	-8	-5	20	25	8
G. S.	-7	7	25	40	-3
M. A.	-2	0	40	8	0
R. S.	-7	10	28	0	0
A. H.	-3	12	30	2	2
R. M.	0	17	32	20	3
J. C.	-3	-3	27	12	0
S. A.	0	25	25	0	-2
T. H.	0	10	28	16	3
T. R.	-10	18	55	8	0
T. B.	-2	0	30	23	5
J. B.	3	10	60	21	2
A. B.	-4	5	45	30	5

RESULTS

Resting pressures in the pharynx and upper esophagus

Measurements were made in 16 subjects (Table I). In the upper part of the esophagus, resting pressure was usually a few millimeters below atmospheric, and respiratory fluctuations were slight and often absent. When the recording tip was withdrawn to the region of the cricoid cartilage, elevation of the resting intraluminal pressure was seen (Figure 1). At this point, further withdrawal of the tip was opposed by a sense of resistance; once through this zone, the tip could be returned to the esophagus only when the subject swallowed. The extent of this zone of elevated pressure varied considerably from subject to subject; in some it was only 1 cm. in length, and in these it was difficult to maintain the recording tip in the high pressure zone. Others showed an elevated resting pressure over a distance of 4 cm. with a step-like increase and decrease on either side of the point of maximal pressure, which usually corresponded with the level of the cricoid cartilage. The maximal elevation of resting pressure varied between 10 and 60 mm. Hg, with a mean of 35 mm. Hg.

The height of the elevation of pressure in the cricoid area varied considerably from subject to subject, and repeat measurements in the same subject did not always give the same results. This variability may be explained in part by the fact that the recording tip may not always have been placed in exactly identical positions. It seemed more likely, however, that resting pressures actually did change during the course of some studies; in fact, an increase or decrease in resistance to the passage of the tube could sometimes be appreciated by the intubator.

Radiographs confirmed that the zone of high resting pressure corresponded with the region of the cricopharyngeal sphincter. As shown in Figure 5, plate 4L, the distal tip, which was in the high pressure zone, may be seen just below the air-filled pharynx and at the level of the cricoid. The sphincter, outlined by a swallow of barium (Figure 4, plate 13A), corresponded with the position of the distal tip.

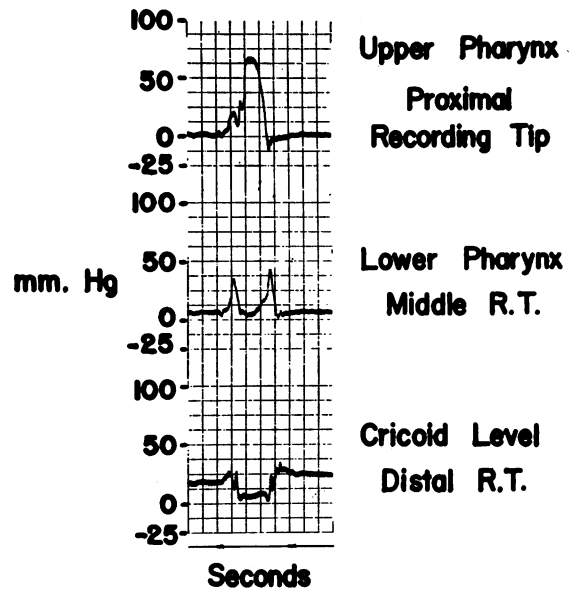


FIG. 2. SIMULTANEOUS SWALLOWING PRESSURES FROM THE UPPER AND LOWER PHARYNX AND THE LEVEL OF THE CRICOPHARYNGEUS

Pressure changes in pharynx and upper esophagus on swallowing

For descriptive purposes, four types of swallowing pressure complexes will be outlined: esophageal, cricopharyngeal, lower and upper pharyngeal. *Esophagus.* Deglutition pressure changes in

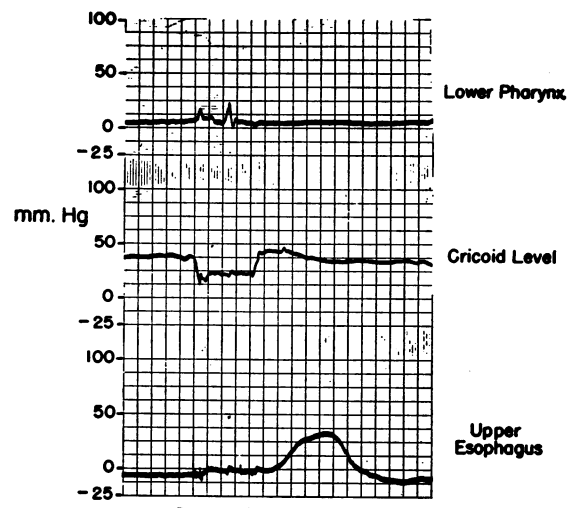


FIG. 3. SIMULTANEOUS SWALLOWING PRESSURES FROM THE LOWER PHARYNX, CRICOPHARYNGEAL LEVEL, AND UPPER ESOPHAGUS

Time intervals in seconds.

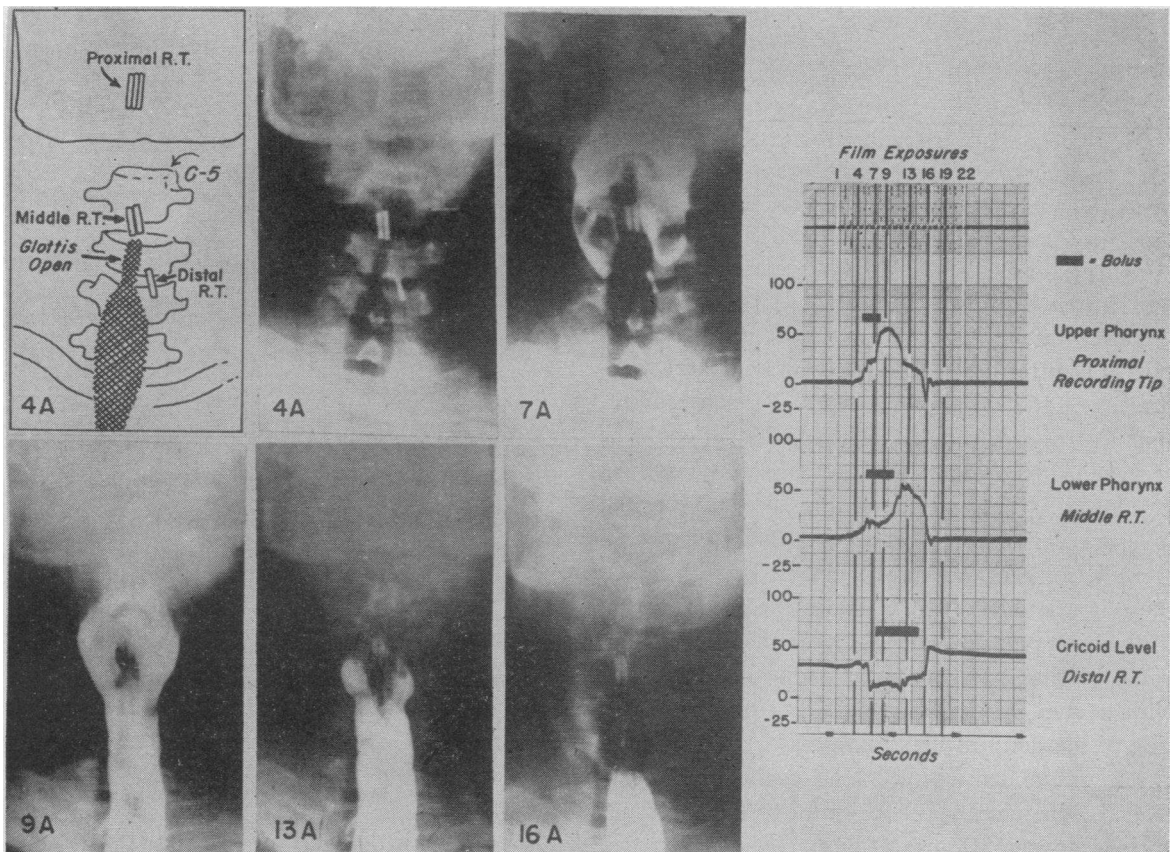


FIG. 4. RADIOGRAPHS TAKEN DURING THE RECORDING OF INTRAPHARYNGEAL PRESSURE CHANGES ON SWALLOWING BARIUM SUSPENSION

The corresponding pressure record is shown on the right, the vertical lines indicating the times of film exposure. The heavy horizontal bar indicates the passage of the bolus in relation to the tracing.

the upper esophagus (Figure 3) consisted of an initial transient negative deflection succeeded by a positive plateau and a final positive wave, the whole complex lasting about 4 to 5 seconds. These findings conform with previous descriptions (10, 11).

Cricopharyngeal level. In the zone of high resting pressure a completely different type of swallowing complex occurred. A rectangular downward deflection now became the basic pattern. On swallowing, the pressure fell abruptly to, or just above, the resting esophageal level, although occasionally a small positive wave preceded this fall. This drop in pressure coincided with the beginning of the positive plateau in esophageal records (Figure 3). After the downward dip, cricopharyngeal pressure either remained stationary or rose slightly for an interval of 0.5 to 1.2

seconds; thereafter, pressure rose, as abruptly as it had fallen, to a resting level, often higher (Figure 2) and sometimes lower than the initial level. This apparent change in resting pressure may have been caused by displacement of the recording tip during swallowing, but actual change in sphincteric tone may have occurred.

On occasions, a final slow positive wave, comparable in amplitude and duration with the final peristaltic pressure wave in the esophagus, was recorded after the rectangular downward complex. Simultaneous radiography, however, suggested that this was due to displacement of the recording tip downward into the upper esophagus.

Lower pharynx. Immediately above the zone of high resting pressure, double-peaked, purely positive swallowing complexes occurred. The relative height of the two peaks varied, but in gen-

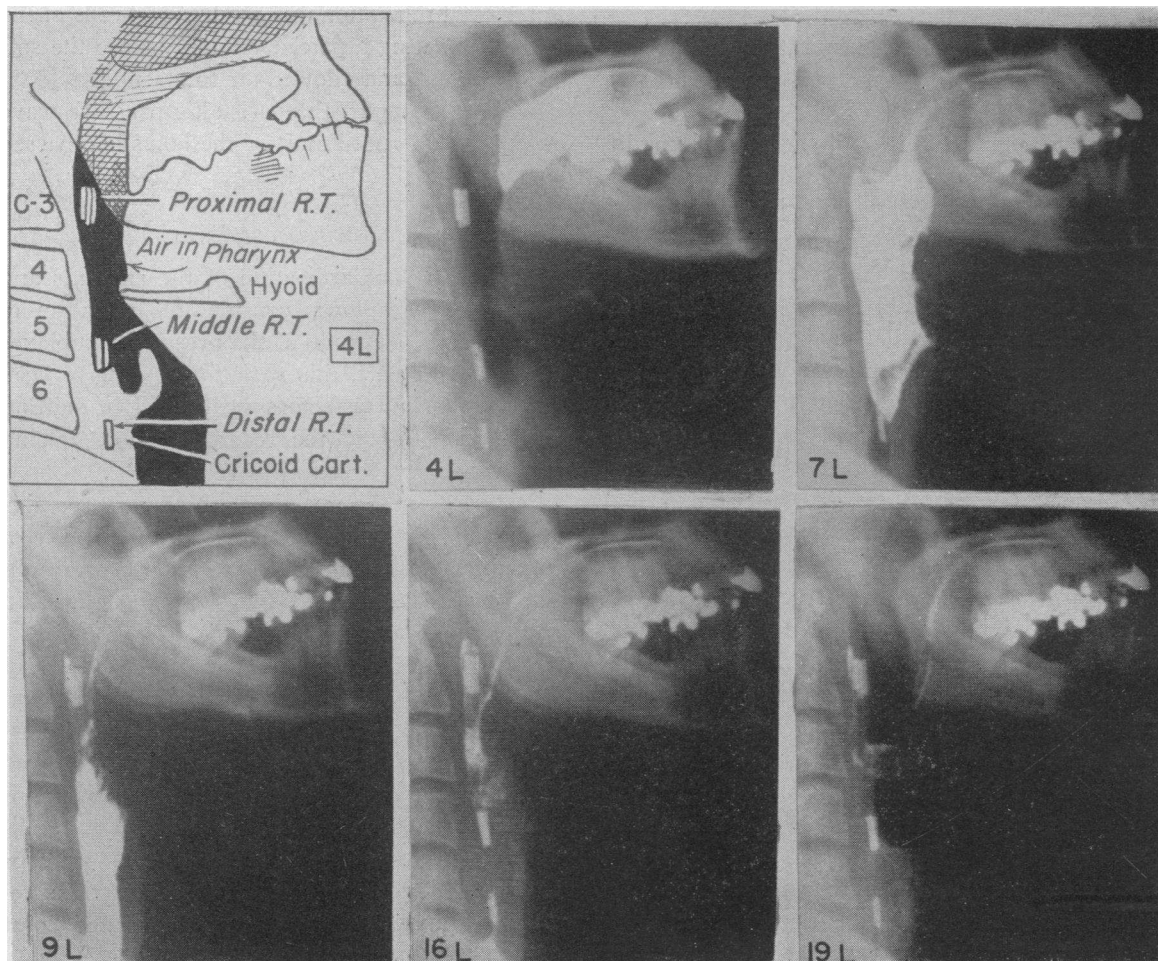


FIG. 5. LATERAL FILMS EXPOSED SIMULTANEOUSLY WITH THE ANTEROPOSTERIOR FILMS SHOWN IN FIGURE 4
R.T. = recording tip.

eral the second was the larger, ranging between 15 and 80 mm. Hg in amplitude. The time interval between these peaks was of the order of 0.4 to 1 second and differed from one swallow to another in the same subject. The second peak occurred immediately before the abrupt return to high resting pressure at the cricoid level (Figure 2).

Upper pharynx. There was no sharp demarcation between the pressure patterns seen in the upper and lower parts of the pharynx. The first pressure peaks corresponded in time and amplitude throughout the pharynx, but the higher the recording tip the closer did the second peak follow behind the first, until in the upper pharynx the two almost merged. Here the amplitude of the second peak usually was greater than the first.

Description of the swallowing act on the basis of correlated radiologic findings and pressure measurements

Upward pressure of the tongue, from the tip backwards, against the hard palate initiated swallowing by thrusting the bolus backward into the pharynx. At the same time, the nasopharynx was closed off by the soft palate, the larynx was elevated, and the vocal cords approximated. The initial negative pressure deflection in the upper esophagus corresponded with the elevation of the larynx, and hence might have represented stretching of the esophagus (12). However, simultaneous intragastric pressure records indicated that a sudden increase in intragastric pressure occurred at this instant, and it is, therefore, also possible

that the negative deflection in the esophageal record was due to the sudden inspiration (Schluckathembewegung) which has been recorded early in swallowing (3).

The movement backward of the bolus into the pharynx, which was now a closed cavity, corresponded with the first peak of the intrapharyngeal pressure record. However, immediately after the head of the bolus entered the pharynx, the cricopharyngeus appeared to open. This occurred synchronously with the abrupt fall in pressure at the cricoid level (Figure 5, plate 7L) and the commencement of the positive plateau in the upper esophagus (Figure 3). The bolus then passed down the pyriform sinuses into the esophagus (Figure 4, plates 7A and 9A) as intrapharyngeal pressure dropped to form the trough between the two peaks. The head of the bolus moved rapidly down the pharynx at a speed of 40 to 50 cm. per second but slowed down at the cricoid region and took longer to pass. This slowing probably took place because the esophageal lumen is narrower than that of the pharynx. It did not appear due to delay in relaxation of the cricopharyngeus as this occurred before the head of the bolus reached the cricoid level (Figure 4, plate 7A).

Successive contraction of the superior, middle and inferior pharyngeal constrictors then took place, rapidly forcing the remainder of the bolus into the esophagus (Figure 4, plate 13A; Figure 5, plates 9L and 16L). The wave of constrictor activity coincided with the second major peak of intrapharyngeal pressure. Radiography indicated that this wave of constriction passed down the pharynx in approximately 1 second. This corresponded with a rate of 5 to 10 cm. per sec., calculated for the wave of constriction on the basis of a time interval of 0.4 to 0.8 second between the second peaks of the upper and lower pharyngeal records.

The second pharyngeal pressure peak was followed immediately by closure of the cricopharyngeal sphincter, coinciding with the abrupt return to high resting pressure at the cricoid level. The larynx descended, the pharynx filled with air and respiration was resumed. The final brief negative wave in the upper pharyngeal record occurred immediately before the pharynx refilled with air (Figure 5, plates 16L and 19L). It may have

represented relaxation of the muscular walls of the pharynx creating a partial vacuum before the soft palate relaxed and allowed air to re-enter.

In the esophagus, the peristaltic pressure wave did not develop until most of the bolus had passed downward.

Variation in swallowing complexes

In spite of standardization of the amounts and frequency of swallows, considerable variation in duration and amplitude of the pressure complexes was seen. In part, this variation may have been caused by technical factors such as slight shifting of the apertures of the recording tubes during swallowing.

Posture. In the upright position, gravity aids the passage of the bolus. However, in not one of five subjects in whom pressure records were obtained both in the supine and sitting positions did posture cause appreciable change.

Type of bolus. In three subjects swallows of water were followed by swallows of chewed or unchewed bread. Although no appreciable difference in swallowing complex occurred with chewed bread as compared with water, swallowing lumps of bread usually caused an increase in the amplitude and duration of pressure complexes, perhaps representing powerful constrictor contractions required to force the bulky and unlubricated bolus through the pharynx.

Drinking without swallowing. Certain individuals have the faculty of pouring fluids down into the esophagus without swallowing. Pressure records were obtained from one such subject, who aided the flow by reducing his intrathoracic pressure by inspiration against a closed glottis. During a 4-second period he imbibed 8 oz. of water without concomitant increase in intrapharyngeal pressure. The pressures at the cricoid level decreased intermittently and thus allowed water to pass into the esophagus. It appears therefore that the cricopharyngeus, with training, can be brought under voluntary control.

DISCUSSION

Our findings indicate that propulsion of the bolus through the pharynx in many ways resembles that through the esophagus. In both instances the bolus, if liquid, is injected from above under

pressure and traverses the lumen of the organ under this impetus. The wave of constrictor contraction, like the peristaltic wave in the esophagus, follows the bolus and sweeps along its last remains, but the whole process is much faster in the pharynx. It is of interest that Kronecker and Meltzer (1) in 1883 found two peaks on balloon records of deglutition pressures in the pharynx and postulated that the first represented the appearance of the bolus, and the second, constrictor contraction. Since that time most investigators have described a single positive wave. Between the pharynx and the esophagus lies a zone in which motor activity is completely different. Our investigations confirm that this has the characteristics of a sphincter. As shown by Fyke and Code (5), resting pressures in this zone are high. In addition, our radiographs indicate that at this point the lumen is constricted, and the position of the sphincter is in accordance with the view that it is the cricopharyngeus. This sphincter relaxes in a coordinated fashion just before the bolus, and contracts again after the bolus has gone by. Although the sphincter normally functions in a reflex fashion, it apparently may be relaxed or dilated voluntarily in certain subjects who have the faculty of pouring fluid into the esophagus without swallowing. Conversely, Dail, Affeldt, and Collier (13) have shown that patients with respiratory paralysis can be taught to keep the cricopharyngeus closed and the glottis open during air "swallowing," thus inflating the lungs (glossopharyngeal breathing).

As no pressure below resting intraesophageal pressure was found, these results refute the suggestion that suction is concerned in swallowing. Resting intraesophageal pressure usually is a few millimeters Hg below that in the pharynx, and relaxation of the cricopharyngeus establishes a mild downward gradient, but this factor would appear to be of negligible importance in propelling the bolus.

A somewhat different type of swallowing pressure complex was described by Fyke and Code (5). At the cricopharyngeal junction, they found markedly negative deglutition pressures. Considerably below the resting pressure level in the esophagus, this negative deflection was followed by a final positive wave. Our results indicate that the pressure changes in this region represent a

tendency toward equalization of intraluminal pressure between the sphincteric zone and the esophagus. No pressures below resting esophageal levels occurred. In addition, in our experience the final positive wave was evident when it was likely that the tube had moved into the esophagus with the bolus. These discrepancies may be related to technical factors, in particular the difficulty that is experienced in maintaining the recording tip in a constant position in relation to the wall of the pharynx and esophagus during swallowing. In this connection, simultaneous radiography is of considerable value in detecting movements of the tube.

While it is not of importance in the normal mechanism of swallowing, suction can be used to facilitate the flow of liquids into the esophagus, as was the case in the subject who by relaxing his cricopharyngeus could pour fluids down. Here the larynx was elevated and closed off from the pharynx, but no impetus was imparted by the tongue or pharyngeal muscles. In certain dysphagias the cricopharyngeus may function normally, yet the pharyngeal constrictor muscles have lost their power (14). Voluntary relaxation of the cricopharyngeus, if it could be taught these patients, might help them in taking fluids.

SUMMARY

Resting intraluminal pressure was elevated at the pharyngo-esophageal junction in each of 30 normal subjects, the mean pressure being 35 mm. Hg. This zone of elevated resting pressure corresponded radiographically with the position of the cricopharyngeal sphincter.

During swallowing, intraluminal pressures were recorded simultaneously from three sites in the pharynx and esophagus while serial radiographs were taken at 12 per second. In the pharynx two peaks of pressure occurred, the first coinciding with the entry of the bolus and the second with constrictor contraction.

In the high pressure zone, at the cricoid level, an abrupt fall to, or to just above intraesophageal pressure occurred on swallowing, followed by an equally abrupt return to the high resting level after the passage of the bolus. These findings support the view that the cricopharyngeus is a true sphincter.

No pressures lower than esophageal pressures were recorded during the passage of the bolus; therefore, swallowing does not involve suction.

REFERENCES

1. Kronecker, H., and Meltzer, S., Der Schluckmechanismus seine Erregung und seine Hemmung. *Arch. Anat. Physiol., Phys. Abt. (Suppl.)*, 1883, p. 328.
2. Rushmer, R. F., and Hendron, J. A., The act of deglutition—A cinefluorographic study. *J. Applied Physiol.*, 1951, **3**, 622.
3. Kronecker, H., "Deglutition" in Richet, C. H., *Dictionnaire de Physiologie*, Paris, 1900, Vol. 4, p. 721.
4. Barclay, A. E., The mechanics of the digestive tract. *Lancet*, 1934, **1**, 11.
5. Fyke, F. E., and Code, C. F., Resting and deglutition pressures in the pharyngo-esophageal region. *Gastroenterology*, 1955, **29**, 24.
6. Killian, G., Über den Mund der Speiseröhre. *Ztschr. f. Ohrenh.*, 1908, **55**, 1.
7. Lerche, W., *The Esophagus and Pharynx in Action*. Springfield, Ill., Charles C Thomas, 1950.
8. Templeton, F. E., and Kredel, R. A., Cricopharyngeal sphincter—a roentgenologic study. *Laryngoscope*, 1943, **53**, 1.
9. Ramsey, G. H., Watson, J. S., Gramiak, R., and Weinberg, S. A., Cinefluorographic analysis of the mechanism of swallowing. *Radiology*, 1955, **64**, 498.
10. Butin, J. W., Olsen, A. M., Moersch, H. J., and Code, C. F., A study of esophageal pressures in normal persons and patients with cardiospasm. *Gastroenterology*, 1953, **23**, 278.
11. Sanchez, G. C., Kramer, P., and Ingelfinger, F. J., Motor mechanisms of the esophagus, particularly of its distal portion. *Gastroenterology*, 1953, **25**, 321.
12. Schreiber, J., Zur Lehre vom Schluckmechanismus. *Arch. f. exper. Path. u. Pharmakol.*, 1912, **67**, 72.
13. Dail, C. W., Affeldt, J. E., and Collier, C. R., Clinical aspects of glossopharyngeal breathing—report of use by one hundred postpoliomyelitic patients. *J. A. M. A.*, 1955, **158**, 445.
14. Kramer, P., Atkinson, M., Wyman, S. M., and Ingelfinger, F. J., The dynamics of swallowing. II. Neuromuscular dysphagia of pharynx. *J. Clin. Invest.*, 1957, **36**, 589.