

**TWO CASES OF CALCINOSIS RENIS, STUDIED BY MEANS OF
RENAL BIOPSY AND RENAL FUNCTION TESTS**

Mogens Bjørneboe, ... , Harald Gormsen, Flemming Raaschou

J Clin Invest. 1952;**31**(7):727-732. <https://doi.org/10.1172/JCI102656>.

Research Article

Find the latest version:

<https://jci.me/102656/pdf>



TWO CASES OF CALCINOSIS RENIS, STUDIED BY MEANS OF RENAL BIOPSY AND RENAL FUNCTION TESTS¹

By MOGENS BJØRNEBOE, CLAUS BRUN, POUL IVERSEN, HARALD GORMSEN,
AND FLEMMING RAASCHOU

(From Medical Department III of the Kommunehospital and the University Institute of Forensic Medicine, Copenhagen, Denmark)

(Submitted for publication January 29, 1952; accepted May 19, 1952)

Nephrocalcinosis may either be due to calcification of necrotic tubular epithelial cells and of precipitates such as occur in corrosive sublimate poisoning, in tubular nephritis (lower nephron nephrosis) (1) and rarely in chronic glomerulonephritis (1-3), or it may appear as part of a metastatic calcification due to mobilization of skeletal calcium in such conditions as hyperparathyroidism, hypervitaminosis D, osseous metastases (4), myelomatosis, osteomalacia, and long-term immobilization of bones (trauma, tuberculosis, and osteomyelitis). Finally, it may be seen following abnormalities of the blood chemistry (other than hypercalcemia) such as hyperchloremic acidosis and hypochloremic alkalosis.

A comprehensive review of nephrocalcinosis in human pathology has recently been given by Geraci, Harris, and Keith (5), and the literature concerning experimental metastatic calcification in the kidneys has been collected by Dick and Prior (6).

In the present paper two cases of calcinosis renis are reported. One patient suffered from a parathyroid adenoma with hyperparathyroidism, the other from calciferol poisoning. In both cases there was a secondary renal disease, and the renal biopsy method afforded essential information about its nature. Differentiated renal function studies were also made in these two patients; the results could be compared with the histological examination undertaken simultaneously.

Renal lesions in hyperparathyroidism

In a paper on renal complications in hyperparathyroidism based on 83 cases, Albright, Baird, Cope, and Bloomberg (7) have divided the renal changes in this disease into the following three groups: 1) deposition of calcium in the renal pelvis with secondary pyelonephritis, 2) deposition of

calcium in the tubules of the kidney with ensuing sclerosis, renal contraction and insufficiency, and 3) deposition of calcium in the kidney as well as in other organs, with a resulting acute renal insufficiency and death in the course of a few hours or days. These three types occurred in 27%, 23%, and 1%, respectively, of their series of hyperparathyroidism.

One of the cases reported here belongs to the second of these groups. This type of renal change will most frequently be localized chiefly in the medulla of the kidney. It consists of interstitial fibrosis, infiltration with lymphocytes and plasma cells, cystic tubular dilatation, thickening and, in some cases, calcification of tubular basement membranes, a relative absence of active glomerulitis or involvement of tubular epithelial cells and, as the fundamental lesion, interstitial deposition of calcium, according to Anderson (8), localized chiefly peritubularly. Bell (9), on the other hand, considers that the calcium, to some extent, is found within the tubules, partly because the calcium is found in cystic cavities which, he supposes, are dilated collecting tubules, and partly because it also is found in the form of deposits of the same shape and direction as collecting tubules (in which areas the tubular epithelium has either disappeared completely or has become calcified). Both authors agree that the impairment of the renal function is due to the obstruction of the tubules.

Hyperparathyroidism. Case report

In November, 1950, we had the opportunity of examining a case of hyperparathyroidism in a 30-year-old woman (E. N. R.).

The patient had been in good health until, in 1943, she became pregnant. In the course of pregnancy she developed a severe toxicosis which necessitated interruption of the pregnancy in the fifth to sixth month. On examinations made on this occasion, there was no proteinuria, and the specific gravity of the urine varied from 1,006 to 1,020. Since then the patient had been constantly ill,

¹ Aided by a grant from King Christian X's Foundation.

though her condition varied. The symptoms were pronounced fatigue and pain "all over the body." In addition, she had had periodical vomiting for months with great loss of weight, polydipsia and polyuria. In 1946 she had intense left-sided lumbar pain for a period of time. She had periodical headache and flickering before her eyes, and during recent years, dyspnoea on exertion. The patient had been in hospitals repeatedly, but the diagnosis was not established until the autumn of 1950.

On physical examination (November, 1950) the patient was pale, lean, and of a tired appearance. There were no palpable tumours of the neck. The thoracic column displayed a slight dextroconvex scoliosis. Intravenous pyelography showed somewhat coarse, but slightly dilated pyelograms and normal ureteral shadows. There were no visible calcifications in the soft parts, especially not in the kidneys, and no renal calculi.

On laboratory examination, the following was discovered: serum calcium 15.6 mg. %, serum phosphorus 1.1 mg. %, alkaline phosphatases 31.4 and 59.6 units (Buch's method; Normal Value 2.0-9.4 units). The urine contained traces of protein, the hemoglobin percentage was 78, blood pressure 125/80 mm. Hg, and serum creatinine 0.76 mg. %, NPN 24 mg. %, and blood urea 27 mg. %.

The results of the differentiated renal function test are shown in Table I. The glomerular filtration rate (expressed by the inulin clearance and the creatinine clearance) and the urea clearance, as well as the maximal tubular secretion (expressed by the para-aminohippuric acid-Tm [T_{mPAH}]) and the renal plasma flow (expressed by the para-aminohippuric acid clearance [C_{PAH}]) were reduced to a little more than half the normal. The

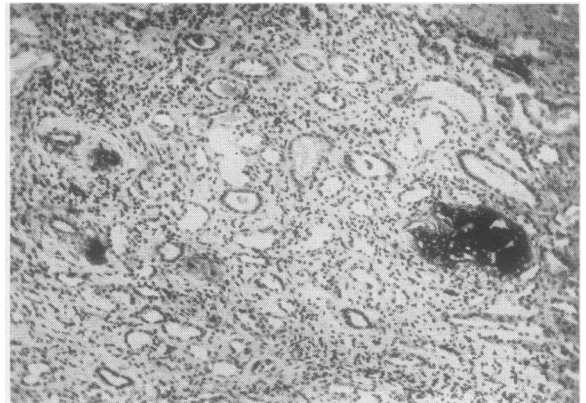


FIG. 1. SECTION OF KIDNEY BIOPSY FROM PATIENT WITH HYPERPARATHYROIDISM (CASE 1)

Medulla with calcium deposits, apparently both interstitially and intracanalicularly. Slight interstitial fibrosis and slight inflammatory cellular infiltration. ($\times 125$)

filtration fraction showed a very slight increase, the ratio between inulin clearance and para-aminohippuric acid-Tm (C_{IN}/T_{mPAH}) was normal and the ratio between para-aminohippuric acid clearance and the para-aminohippuric acid-Tm (C_{PAH}/T_{mPAH}) was a little below the normal.

Biopsy of the kidney (according to the technique described by Iversen and Brun [10]) was made three days before the examination of the renal function. The biopsy material measured about 13 mm. in length and consisted of equal parts of cortex and medulla. Histological examination

TABLE I

Differentiated kidney function examinations of two patients suffering from calcinosis renalis

The kidney function has been re-examined 12 and 18 months after the first examination. It has not been corrected for surface area.

No., initials, date	Diagnosis	Inulin clearance	Creatinine clearance	Urea clearance	PAH clearance	T_{mPAH}	Blood urea	Serum creatinine	C_{IN}/T_{mPAH}	C_{IN}/C_{PAH}	C_{PAH}/T_{mPAH}	Weight	Height
1. E. R. Nov., 27, 1950	Hyperparathyroidism	55.2	70.5	47.3	216	28.9	27	0.76	1.91	25.6%	7.5	48.4 Kg.	160 cm.
Dec. 5, 1951		42.8	58.7	25.2	251	—	52	1.32	—	17.1%	—	63.5 Kg.	—
2. G. Y. A. May 12, 1950	D_2 -poisoning	42.9	53.3	26.4	308	30.3	42	1.5	1.42	13.9%	10.2	56.8 Kg.	170 cm.
Nov. 11, 1951		75.6	68.6	39.3	397	—	43	1.37	—	19.1%	—	65.0 Kg.	—

showed quite large calcium deposits both in the cortex and medulla, especially in the latter (Figures 1-3). It was difficult to decide whether they were interstitial or intracanalicular, but some of them, at any rate those in the medulla (Figure 1), were unquestionably intracanalicular. In a single section the cortex contained about 15 glomeruli, of which three seemed to be completely intact. A few of the others were partly hyalinized (Figure 2), the rest were completely hyalinized (Figure 3). In five different sections 64 glomeruli were found. Thirty of these were completely hyalinized, 17 slightly to moderately hyalinized, and 17 were normal. There was a considerable fibrosis around the hyalinized glomeruli, and the fibrous tissue here displayed a rather intense diffuse infiltration with lymphocytes and histiocytes and very few plasma cells (Figure 3). In addition there was a slight diffuse interstitial fibrosis in the cortex and quite a number of atrophic tubules around the perishing glomeruli. Otherwise the tubules did not seem to display anything abnormal. The lumina of both the proximal and distal convoluted tubules were rather wide; there were no casts. There was quite a pronounced increase of connective tissue in the medulla with rather intense diffuse lymphocyte and histiocyte infiltration. The few vascular lumina found in the biopsy material did not seem to display anything unquestionably abnormal. However, in a few small arteries there was possibly a

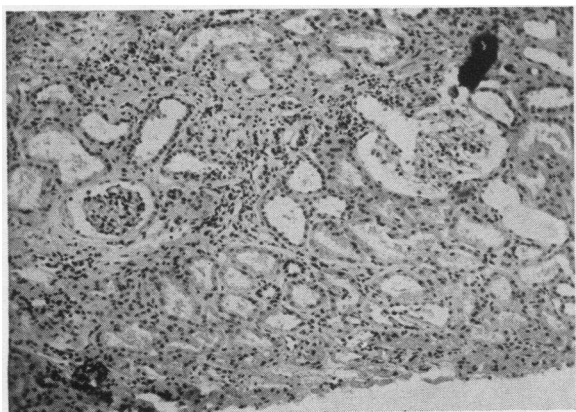


FIG. 2. SECTION OF KIDNEY BIOPSY FROM THE SAME PATIENT AS FIGURE 1

Cortex with a normal and a slight hyalinized glomerulus, interstitial calcium deposits, slight interstitial fibrosis, tubular atrophy and mild inflammatory cellular infiltration. ($\times 125$)

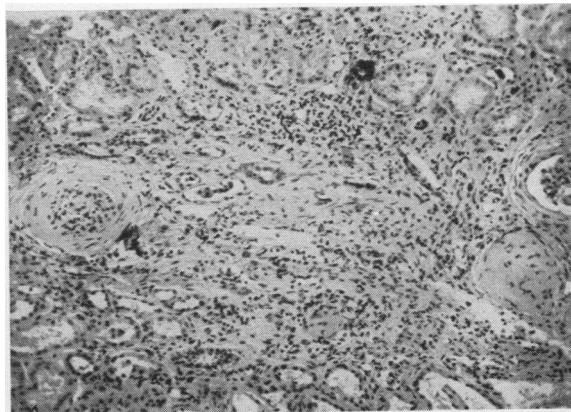


FIG. 3. SECTION OF KIDNEY BIOPSY FROM THE SAME PATIENT AS FIGURES 1 AND 2

Cortex with hyalinized glomeruli, interstitial calcium deposits, pronounced interstitial fibrosis, tubular atrophy and mild inflammatory cellular infiltration. ($\times 125$)

slight hyaline thickening. Phosphatase staining (by the method of Gomori) was distinctly positive in almost all lumina of the proximal convoluted tubules that were intact. There was undoubtedly also a positive phosphatase staining in a few Henle's loops, of which the biopsy material, however, contained very few. It is possible that the increased amount of calcium in the tissue may have contributed to the positive phosphatase test, as the latter depends on a precipitation of calcium.

Summary of the histological description. Quite considerable quantities of intracanalicular and interstitial calcium deposits were found both in the cortex and the medulla. Further, there were interstitial fibrosis and numerous hyaline glomeruli. In January, 1951, a parathyroid adenoma was successfully removed from the superior thoracic aperture. Microscopic diagnosis revealed eosinophilic adenoma of the parathyroid gland.

Re-examination of the kidney function about one year later (see Table I) showed that the glomerular filtration (inulin and creatinine clearance) had been reduced to 75-80% of what it had been in November, 1950. The blood urea and serum creatinine were increased to pathological values (52 and 1.32 mg. %), while the para-aminohippuric acid clearance was unchanged.

Renal lesions in calciferol poisoning

It has been demonstrated by numerous authors (11), in various experimental animals, that cal-

cium deposits and calculus formation occur in the kidneys in hypervitaminosis-D. It has been shown by Guldager (12) that the calcium deposits were found in particular in the convoluted tubules and in the small vessels and capillaries of the cortex, whereas the glomeruli remained unaffected. Goormagtigh and Handovsky (13) have found hypertrophy of the tunica media of the arterioles and injury of the tubules which might lead to uremia.

In human beings, too, a prolonged treatment with vitamin D₂ may cause a progressive renal disorder with proteinuria, hematuria, casts in the urine, and a decrease of the renal function, possibly with hypertension (11). Corcoran, Taylor, and Page (14) have made a differentiated renal function test in two patients with reduced kidney function from intoxication with irradiated ergosterol. In the cases examined, the histological changes in the kidney occurred in the form of calcium deposits in the medulla, chiefly localized in the lumina of the collecting tubules. Mention is also made, by Bauer and Freyberg (15), of calcium deposits in the vessels and of "arteriosclerotic nephropathy."

Calciferol poisoning. Case report

In April, 1950, a 28-year-old woman was admitted to the Medical Department III of Kommunehospital, for nephritis and observation for uremia.

In 1936 the patient had been treated for non-toxic struma with subtotal strumectomy. As the struma recurred with compression of the trachea, another strumectomy was made in 1940; it was extremely difficult because of severe adhesions. After the operation the patient was given calcium and A.T. 10 because of parathyroprival tetany.

In 1942 the patient had been given Ultranol ultraconcentrate, 50,000 i.u. and four calcium tablets (2 g.) per day. In the beginning her serum calcium was controlled every month, later every six months; during the last two years it had not been controlled at all. During the same period her ultranol intake had varied.

In April, 1949, the patient was feeling tired and poorly. Her doctor found that the sedimentation rate had increased (58 mm.), the hemoglobin percentage had fallen (66%), and further ascertained the presence of proteinuria of slight degree, normal blood pressure, and slightly increased blood urea (48 mg. %). Her condition has fluctuated considerably since then. In January, 1950, she felt ill again with nausea, vomiting, anorexia, and fatigue. On examination her doctor found the following: slight anemia (72%), increased sedimentation rate (180 mm.), increased blood urea (54 mg. %), greatly increased se-

rum calcium (18.4 mg. %), and slightly increased serum phosphorus (5.1 mg. %).

The physical examination showed that the patient was pale and lean, but otherwise nothing abnormal was found. Intravenous pyelography showed a rapid and intense excretion in normal pyelograms in both kidneys. No calcification of the renal parenchyma and no renal calculi were observed. Roentgen examination of the femur and the humerus showed normal osseous structure without any signs of decalcification.

Laboratory examinations in April, 1950, revealed the following: blood pressure 130/80-110/70 mm. Hg, hemoglobin percentage 67, blood urea 42 mg. %, serum creatinine 1.5 mg. %, alkaline phosphatases 4.3 units (Buch), serum calcium 11.8 mg. %, serum CO₂ 35.6 mmol., serum chloride 98.0 meq./L. The urine contained no protein on repeated examination, and several microscopic examinations showed it to be normal.

The differentiated renal function tests showed that the inulin clearance, the para-aminohippuric acid clearance and the para-aminohippuric acid-Tm were reduced to about half the normal. The inulin clearance/para-aminohippuric acid-Tm (C_{IN}/T_{MPAH}) and the filtration fraction showed low normal or slightly reduced values, whereas the ratio between the para-aminohippuric acid clearance and the para-aminohippuric acid-Tm (C_{PAH}/T_{MPAH}) was normal.

The concentration capacity of the kidneys (determined according to Addis-Shevky's method) was impaired (specific gravity: 1.014).

Biopsy of the kidney was made twice with an interval of three weeks (Figures 4-5). At the first biopsy, a specimen measuring about 6 mm. in

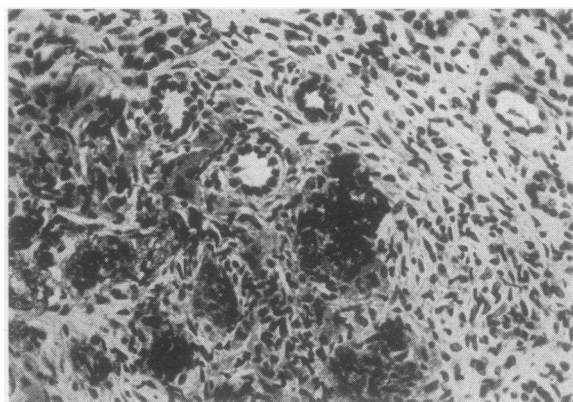


FIG. 4. SECTION OF KIDNEY BIOPSY FROM PATIENT WITH D₂ POISONING (CASE 2)

Medulla with calcium deposits, apparently mainly intracanalicularly. Slight interstitial fibrosis and mild inflammatory cellular infiltration. ($\times 140$)

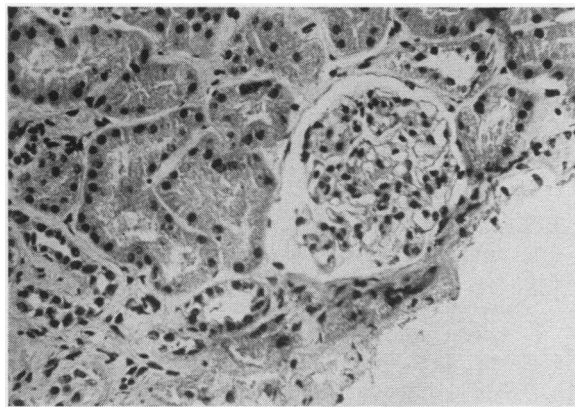


FIG. 5. SECTION OF KIDNEY BIOPSY FROM THE SAME PATIENT AS FIGURE 4

Normal cortex. ($\times 280$)

length was removed. It consisted chiefly of medulla. This contained a number of large calcium deposits, localized, as far as could be determined, mainly within the canaliculi (Figure 4). There was a slight increase of connective tissue and a slight diffuse interstitial lymphocyte and histiocyte infiltration; otherwise nothing abnormal was found.

At the second biopsy, three weeks later, a piece of cortex, measuring about 6 mm. in length was removed. It contained 12-14 glomeruli and displayed no definite abnormalities. There were no calcium deposits and the glomeruli were normal (Figure 5). In a "differential count" in four different sections of about 50 glomeruli, a single completely hyalinized glomerulus was found, whereas all other glomeruli were normal. There were tall, granular cells of normal appearance in the proximal convoluted tubules. At the border of the medulla, there was a slight increase of connective tissue, a slight diffuse infiltration with lymphocytes and histiocytes, and many cellular remnants. Phosphatase staining (Gomori's method) showed a faintly positive reaction in parts of the proximal convoluted tubules.

During the patient's stay in the hospital, the renal function improved considerably, as the 24-hour creatinine clearance rose from 34 to 59 ml./min. in the course of three weeks.

The kidney function was re-examined 18 months later (see Table I). The glomerular filtration (inulin, creatinine, and urea clearance) had in-

creased considerably. The para-aminohippuric acid clearance had also increased, while the blood urea remained unchanged and the serum creatinine had decreased.

DISCUSSION

In both these cases of calcinosis renis, the histological findings in biopsy of the kidney correspond exactly to previously published findings in autopsy of patients who had died of hyperparathyroidism and D_2 poisoning. As far as we know, differentiated renal function tests have been reported previously only in cases of D_2 poisoning (13), not in cases of hyperparathyroidism. In both patients in this study, about 50% reduction of both the glomerular filtration and maximal tubular secretion was found. It was possible in both cases to compare the function and the amount of pathological and normal glomeruli. In the case of hyperparathyroidism, about half the 64 glomeruli examined had presumably been completely destroyed. On the assumption that the renal tissue examined is representative of the histology of the entire kidney, it must be said that in this case, there was quite good conformity between glomerular filtration rate and the number of uninjured glomeruli (even if some of these also displayed slight pathological changes).

On the other hand, in the case of D_2 poisoning, only one single hyalinized glomerulus was found, whereas all other glomeruli were normal and, in spite of this, the same reduction in glomerular filtration rate was found as in the case of hyperparathyroidism.

It cannot be settled on the basis of the present conditions, whether this discrepancy between decreased kidney function and normal histological findings is due to functional alterations, which cannot be observed in the histological preparations, or whether it is due to the fact that the biopsy was not representative of the histological changes in the kidneys. From the literature it seems reasonable to suppose that D_2 poisoning will cause diffuse kidney injuries. The fact that the kidney function in this case has improved considerably might also indicate that the injuries were functional, or possibly due to a reversible and not too extensive nephrocalcinosis. The various degrees of glo-

merular destruction which have been found in these two patients, in spite of the identical reduction in their kidney function, correspond very well to the changes which have later been found in their kidney function, after treatment of the underlying diseases. The kidney function of the first patient, whose glomeruli were mainly hyalinized, has decreased. In the other patient, whose glomeruli were histologically normal, the kidney function has increased.

SUMMARY

A case of hyperparathyroidism in a 30-year-old woman, and one of vitamin D₂ poisoning in a 28-year-old woman are reported. In the first patient, biopsy of the kidney showed considerable calcium deposits in the cortex and the medulla, interstitial fibrosis and numerous hyaline glomeruli. In the second patient, biopsy of the kidney showed calcium deposits in the medulla only, localized in the collecting tubules, and normal glomeruli. In renal function tests, the glomerular filtration rate and the maximal tubular secretion were reduced by about 50% in both patients. At the re-examination, one and 1½ years later, respectively, the kidney function of the first patient had decreased, while in the second patient, it had increased. This finding might indicate the prognostic value of the kidney biopsy.

ACKNOWLEDGMENT

The technical assistance of Miss B. Anger, Mrs. K. Jörgensen, Miss H. Rydahl, and Mrs. B. Stadel is gratefully acknowledged.

REFERENCES

1. Rosenbaum, D., Coggeshall, W., and Levin, R. T., Chronic glomerulonephritis with severe renal tubular calcification. *Am. J. M. Sc.*, 1951, **221**, 319.
2. Lubarsch, O., Die Kalkablagerungen in der Niere. Henke und Lubarsch: Hdb. d. spez. path. Anat. u. Histol., 1925, VI/1, 564.
3. Vaughan, J. H., Sosman, M. C., and Kinney, T. D., Nephrocalcinosis. *Am. J. Roentgenol.*, 1947, **58**, 33.
4. Fulton, R. M., and Paget, G. E., Hypercalcemic uraemia with nephrocalcinosis due to carcinomatosis. *Lancet*, 1951, **1**, 886.
5. Geraci, J. E., Harris, H. W., and Keith, N. M., Bilateral diffuse nephrocalcinosis; report of two cases. *Proc. Staff Meet., Mayo Clinic*, 1950, **25**, 305.
6. Dick, H. J., and Prior, J. T., Experimental acute metastatic calcification in the kidney of rats. *Am. J. Clin. Path.*, 1951, **21**, 409.
7. Albright, F., Baird, P. C., Cope, O., and Bloomberg, E., Studies on the physiology of parathyroid glands; renal complications of hyperparathyroidism. *Am. J. M. Sc.*, 1934, **187**, 49.
8. Anderson, W. A. D., The renal lesion in hyperparathyroidism. *Endocrinology*, 1939, **24**, 372.
9. Bell, E. T., *Renal Diseases*. Henry Kimpton, London, 1946, p. 388.
10. Iversen, P., and Brun, C., Aspiration biopsy of the kidney. *Am. J. Med.*, 1951, **11**, 324.
11. Sonne, L. M., Calciferol in the Treatment of Lupus Vulgaris. Thesis, 1950, E. Munksgaard, Copenhagen.
12. Guldager, A., Hypervitaminosis D. Thesis, 1936, Copenhagen.
13. Goormagtigh, N., and Handovsky, H., Effect of vitamin D₂ (calciferol) on the dog. *Arch. Path.*, 1938, **26**, 1144.
14. Corcoran, A. C., Taylor, R. D., and Page, I. H., Functional patterns in renal disease. *Ann. Int. Med.*, 1948, **28**, 560.
15. Bauer, J. M., and Freyberg, R. H., Vitamin D intoxication with metastatic calcification. *J. A. M. A.*, 1946, **130**, 1208.