

IL-4 gene therapy for collagen arthritis suppresses synovial IL-17 and osteoprotegerin ligand and prevents bone erosion

Erik Lubberts,¹ Leo A.B. Joosten,¹ Martine Chabaud,² Liduine van den Bersselaar,¹ Birgitte Oppers,¹ Christina J.J. Coenen-de Roo,³ Carl D. Richards,⁴ Pierre Miossec,² and Wim B. van den Berg¹

¹Rheumatology Research Laboratory, Department of Rheumatology, University Hospital Nijmegen, Nijmegen, The Netherlands

²Department of Immunology and Rheumatology, Hôpital Edouard Herriot, Lyon, France

³Department of Pharmacology, NV Organon, Oss, The Netherlands

⁴Department of Pathology, McMaster University, Hamilton, Ontario, Canada

Address correspondence to: Erik Lubberts, University Hospital Nijmegen, Department of Rheumatology, Rheumatology Research Laboratory, Post Office Box 9101, 6500 HB Nijmegen, The Netherlands. Phone: 31-24-3616464; Fax: 31-24-3540403; E-mail: E.Lubberts@reuma.azn.nl.

Received for publication July 1, 1999, and accepted in revised form May 2, 2000.

Bone destruction is the most difficult target in the treatment of rheumatoid arthritis (RA). Here, we report that local overexpression of IL-4, introduced by a recombinant human type 5 adenovirus vector (Ad5E1mIL-4) prevents joint damage and bone erosion in the knees of mice with collagen arthritis (CIA). No difference was noted in the course of CIA in the injected knee joints between Ad5E1mIL-4 and the control vector, but radiographic analysis revealed impressive reduction of joint erosion and more compact bone structure in the Ad5E1mIL-4 group. Although severe inflammation persisted in treated mice, Ad5E1mIL-4 prevented bone erosion and diminished tartrate-resistant acid phosphatase (TRAP) activity, indicating that local IL-4 inhibits the formation of osteoclast-like cells. Messenger RNA levels of IL-17, IL-12, and cathepsin K in the synovial tissue were suppressed, as were IL-6 and IL-12 protein production. Osteoprotegerin ligand (OPGL) expression was markedly suppressed by local IL-4, but no loss of OPG expression was noted with Ad5E1mIL-4 treatment. Finally, in *in vitro* studies, bone samples of patients with arthritis revealed consistent suppression by IL-4 of type I collagen breakdown. IL-4 also enhanced synthesis of type I procollagen, suggesting that it promoted tissue repair. These findings may have significant implications for the prevention of bone erosion in arthritis.

J. Clin. Invest. **105**:1697–1710 (2000).

Introduction

Bone is a dynamic tissue, composed of cells, collagenous matrix, and inorganic elements. The growth, development, and maintenance of bone is a highly regulated process (1). It undergoes continuous remodeling with a balance between bone resorption and formation under normal conditions, involving coordinate regulation of bone-forming cells (osteoblasts) and bone-resorbing cells (osteoclasts) (2, 3). These cells arise from hematopoietic precursors by physiologically controlled processes that involve cytokines, growth factors, and hormones (3, 4). Osteoclasts are rarely seen under normal conditions, however, increased osteoclast activity is seen in many pathological disorders, including Paget's disease, lytic bone metastases, postmenopausal osteoporosis, or rheumatoid arthritis (RA), leading to net loss of bone.

RA is a chronic inflammatory joint disease, and bone erosion is a major complication (5, 6). In areas of pannus infiltration, erosion of calcified cartilage and subchondral bone is common, leading to charac-

teristic marginal erosions seen radiographically in this disease. The area of contact between pannus and cartilage/bone represents an erosive front, and the role of osteoclasts in erosion of bone in arthritis has been documented (7–10).

IL-1 and TNF- α are key mediators in the perpetuation of synovitis and cartilage/bone destruction and are produced in increased quantities by RA synovium and detected in synovial fluid (11, 12). These proinflammatory cytokines mediate the cascade of molecular pathways ensuing in the production of matrix-degrading enzymes (13). The important role of IL-1 β , TNF- α , and IL-6 on osteoclastic recruitment, proliferation, and differentiation has been shown (14–17). In addition, osteoclast or osteoclast-like cells demonstrated immunoreactivity for IL-1 β , IL-6, and TNF- α (18). Furthermore, the potency of IL-17 as a stimulator of osteoclastogenesis has been shown *in vitro* (19), and this T-cell-derived cytokine was found in the synovium of patients with RA (19, 20). Recently, osteoprotegerin ligand (OPGL) has been considered a novel key regulator

of osteoclastogenesis, as OPGL knockout mice did not show osteoclastic bone resorption (21).

In addition to the action of destructive mediators, the destructive process seems under the control of regulatory mediators such as IL-4 and IL-10. These modulatory cytokines have the potential to antagonize inflammatory and destructive mediators of the RA process effectively (22, 23). Marked protection of cartilage can be achieved with IL-4/IL-10 treatment (24, 25). Recently, we found impressive prevention of cartilage destruction by local IL-4 gene therapy, despite severe inflammation (26). Of great importance, IL-4 could not be detected in the synovium of patients with RA (27). This lack of IL-4 may contribute to the uneven balance between destructive and regulatory mediators in the synovium of the RA process. In vitro, IL-4 has been shown to be an inhibitor of bone resorption (28–31) and osteoclast-like cell formation (32, 33); however, its role in vivo has not been identified.

In the present study, we examined the impact of local IL-4 on bone erosion in the knee joint of mice with collagen-induced arthritis, using gene transfer with an IL-4-expressing adenoviral vector. In addition, we investigated the effects of IL-4 on the degradation and formation of collagen type I in bone samples from patients with arthritis. Collagen arthritis is an autoimmune model of RA, driven by the combination of cellular and humoral immunity against collagen type II (CII) and is characterized by rapid and severe erosions of cartilage and bone (34–36). Local IL-4 treatment impressively prevents joint damage and bone erosion, despite severe inflammation. The protective effect was associated with decreased formation of osteoclast-like cells and downregulation of IL-17, IL-6, IL-12, and OPGL in the synovium. In addition, mRNA levels of cathepsin K in synovial tissue was reduced in the IL-4 group. Interestingly, IL-4 prevented collagen type I breakdown, but enhanced the formation of type I procollagen in bone from patients with arthritis, suggesting promotion of tissue repair.

Methods

Animals. Male DBA-1/BOM mice were purchased from Bomholdgård (Ry, Denmark). The mice were housed in filter-top cages. The mice were immunized 10–12 weeks of age. Female C57bl/6 and balb/c mice were obtained at our university breeding facilities in Nijmegen. Balb/c IL-4 gene knockout mice were kindly provided by NV Organon (Oss, The Netherlands). Water and food were provided ad libitum.

Adenoviral vectors. The recombinant replication-deficient adenovirus Ad5E1mIL-4 was generated by homologous recombination after cotransfecting 293 cells with PACCMVmIL-4 and a virus-rescuing vector pAdBHG10 as described elsewhere (37). The empty recombinant replication-deficient adenovirus Ad5del70-3 was used as a control vector throughout the study. High titers of recombinant adenoviruses were amplified, purified, titered, and stored as described previously (38). Biologic

activity of IL-4 produced by Ad5E1mIL-4 was verified by blocking experiments with anti-IL-4 on AdE1mIL-4-induced inflammation and synovial cell mass.

Intra-articular gene transfer with Ad5E1mIL-4. Naive mice were intra-articularly injected in the right knee joint with 10^8 , 10^7 , or 10^6 pfu/6 μ L of either Ad5E1mIL-4 or Ad5del70-3. At different time points, mice were bled and sacrificed by cervical dislocation. Patella with adjacent synovium was dissected in a standardized manner (25) from the right and the contralateral knee. The levels of IL-4 in sera and washouts of joint tissue were measured by ELISA as described later here.

Induction of collagen-induced arthritis. Bovine type II collagen was prepared as described (24) and diluted in 0.05 M acetic acid to a concentration of 2 mg/mL and was emulsified in equal volumes of CFA (2 mg/mL of *Mycobacterium tuberculosis*; strain H37Ra; Difco Laboratories, Detroit, Michigan, USA). The mice were immunized intradermally at the base of the tail with 100 μ L of emulsion (100 μ g of collagen). On day 21, mice were given an intraperitoneal booster injection of 100 μ g of type II collagen dissolved in PBS, and normally arthritis onset will then occur around days 25–28.

Study protocol. The collagen arthritis model (CIA) was induced in male DBA-1 mice as already described here. Just before expected onset of CIA, mice were scored visually for the appearance of arthritis. Mice without macroscopic signs of arthritis in the paws were selected. Mice were anesthetized with ether, and a small aperture in the skin of the knee was performed for the intra-articular injection procedure. When absence of arthritis was confirmed in the knee joint, intra-articular injections were performed with 10^7 pfu/6 μ L of either an IL-4-expressing (Ad5E1mIL-4) or an empty control (Ad5del70-3) recombinant human type 5 adenovirus vector or with saline (26). At days 1, 3, 5, and 7 after the intra-articular injection of the viral vector, mice were sacrificed by cervical dislocation, and the skin of the knee joint was removed. The appearance of arthritis in the injected joints was assessed and severity score was recorded as described previously (24). Thereafter, knee joints were isolated and processed for light microscopy.

Assessment of arthritis. Mice were considered to have arthritis when significant changes in redness and/or swelling were noted in the digits or in other parts of the paws. Knee joint inflammation was scored visually after skin dissection, using the following scale: 0, non-inflamed; 1, mild inflammation; 1.5, marked inflammation; 2, severe inflammation. Scoring was done by two independent observers, without knowledge of the experimental groups.

Assessment of IL-4, IL-6, and IL-12 protein in 1-hour patella washouts. To determine the levels of IL-4, IL-6, and IL-12 in patella washouts, patellae were isolated in a standardized manner from knee joints as described previously (25). Patella were incubated in RPMI 1640 medium (GIBCO BRL, Breda, The Netherlands) with 0.1% BSA, gentamicin (50 μ g/mL), and L-glutamine (2

mM) (200 μ L/patella) for 1 hour at room temperature. After supernatant was harvested the IL-4, IL-6, and IL-12 levels were measured by ELISA (25, 26). Anti-murine IL-4 antibodies (Ab's) were purchased from PharMingen (San Diego, California, USA; capture Ab: rat anti-mouse IL-4 mAb [clone: BVD4-1D11]; detection Ab: rat anti-mouse IL-4 mAb biotin labeled [clone: BVD6-24G2]). The detection range of the IL-4 ELISA is 1,280–1.2 pg/mL. The sensitivity of the IL-4 ELISA is 5 pg/mL. No cross-reactivity was found with the cytokines IL-1, IL-6, or IL-10. Anti-murine IL-6 Ab's were from Biosource International (Camarillo, California, USA; capture Ab: rat anti-mouse IL-6 mAb [clone: MP5-20F3]; detection Ab: rat anti-mouse IL-6 mAb biotin labeled [clone MP5-32CK]). The detection range of the IL-6 ELISA is 2,560–40 pg/mL, with a sensitivity of 78 pg/mL. No cross-reactivity was found with the cytokines IL-1 β , IL-4, and IL-10. Anti-murine IL-12 Ab's were obtained from Genzyme (Cambridge, Massachusetts, USA; capture Ab: monoclonal rat anti-mouse IL-12 [clone C15.6]; detection Ab: monoclonal rat anti-mouse IL-12 biotin labeled [clone C17.8]). The detection range of the IL-12 ELISA is 1,280–1.2 pg/mL, with a sensitivity of 10 pg/mL. No cross-reactivity was found with IL-4, IL-6, TNF- α , and IL-1.

Briefly, ELISA plates (Maxisorb; Nunc, Copenhagen, Denmark) were coated with the capture Ab (3 μ g/mL) by overnight incubation at 4°C in 0.1 M carbonate buffer (pH 9.6). Nonspecific binding sites were blocked by 1-hour incubation at 37°C with 1% BSA in PBS/Tween-20. The supernatants were tested by 3-hour incubation at 37°C. The plates were then incubated at 37°C with the biotin-labeled second Ab (0.25 μ g/mL) diluted in PBS/0.5% BSA (pH 7.5), followed by a 30-minute incubation at 37°C with streptavidin conjugated to poly-horseradish peroxidase (0.25 μ g/mL) (source: *Streptomyces avidinii*; Central Laboratory of Blood Transfusion, Amsterdam, The Netherlands) diluted in 1% casein colloid/PBS buffer (pH 7.5) (Central Laboratory of Blood Transfusion). Bound complexes were detected by reaction with 0.08% orthophenylenediamine (OPD) diluted in 50 mM phosphate buffer (pH 6.0) and 0.03% H₂O₂. Absorbance was measured at 492 nm using an ELISA plate reader (Titertek Multiscan MCC/340; Labsystems, Helsinki, Finland). The cytokine concentration in the samples was calculated as picograms per milliliter using recombinant murine IL-4 (a kind gift of S. Smith [Schering-Plough, Kenilworth, New Jersey, USA]), IL-6 (Biosource International) and IL-12 (kindly provided by S. Wolf, Genetic Institute Inc., Cambridge, Massachusetts, USA) as a standard.

Isolation of RNA. Mice were sacrificed by cervical dislocation, and the patella and adjacent synovium were immediately dissected (39). Synovium biopsy tissue was taken from six patella specimens. Two biopsy specimens with a diameter of 3 mm were punched out, using a biopsy punch (Stifle, Wächtersbach, Germany): one from the lateral side and one from the medial side.

Three lateral and three medial biopsy samples were pooled to yield two samples per group. The synovium samples were immediately frozen in liquid nitrogen. Synovium biopsy samples were ground to powder using a microdismembrator II (Braun Inc., Melsungen, Germany). Total RNA was extracted in 1 mL of Trizol reagent (GIBCO BRL), a monophasic solution of phenol and guanidine isothiocyanate, which is an improved single-step RNA isolation method based on the method described by Chomczynski and Sacchi (40).

PCR amplification. One microgram of synovial RNA was used for RT-PCR. Messenger RNA was reverse transcribed to complementary DNA (cDNA) using oligo-dT primers, and one twentieth of the cDNA was used in one PCR amplification. PCR was performed at a final concentration of 200 μ M dNTPs, 0.1 μ M of each primer, and 1 unit of *Taq* polymerase (GIBCO BRL) in standard PCR buffer (20 mM Tris-HCl [pH 8.4] and 50 mM KCl) (GIBCO BRL). The mixture was overlaid with mineral oil and amplified in a thermocycler (OmniGene, Hybaid, United Kingdom). Message for GAPDH was amplified using the primers described elsewhere (24). Primers for cathepsin K, IL-17, IL-12, OPGL and osteoprotegerin (OPG) were designed using Oligo 4.0 and Primer Software (Molecular Biology Insights Inc., Cascade, Colorado, USA). For every mediator that is tested in the PCR reaction, GAPDH expression was also measured in the same reaction mix. Samples (5 μ L) were taken from the reaction tubes after a certain number of cycles. PCR products were separated on 1.6% agarose and stained with ethidium bromide. The expression for GAPDH is normalized between the control vector group and the IL-4 group before differences in mRNA expression for a particular mediator were determined.

Radiology. At the end of the experiment, knee joints were isolated and used for x-ray analysis as a marker for joint destruction. X-ray films were carefully examined using a stereo microscope, and joint destruction was scored on a scale of 0–5, ranging from no damage to complete destruction of the joint.

Tartrate-resistant acid phosphatase staining. At the end of the experiment, whole knee joints were fixed for 2 days in 10% formalin, followed by decalcification in 10% EDTA (Titriplex III; Merck, Darmstadt, Germany) in 1 mM Tris-HCl (pH 7.4) for up to 2 weeks at 4°C (10). Decalcified specimens were processed for paraffin embedding (41). Staining of tissue sections (7 μ m) for tartrate-resistant acid phosphatase (TRAP) was performed by a leukocyte acid phosphatase kit, a cell-staining kit for the detection of tartrate resistant acid phosphatase from Sigma Chemical Co. (St. Louis, Missouri, USA).

Histology. Whole knee joints were removed and fixed for 4 days in 10% formalin. After decalcification in 5% formic acid, the specimens were processed for paraffin embedding (41). Tissue sections (7 μ m) were stained with hematoxylin and eosin (H&E) or Safranin O. Histopathological changes were scored using the fol-

lowing parameters. Infiltration of cells was scored on a scale of 0–3, depending on the amount of inflammatory cells in the synovial cavity (exudate) and synovial tissue (infiltrate). A characteristic parameter in CIA is the progressive loss of bone. This destruction was graded on a scale of 0–3, ranging from no damage to complete loss of the bone structure.

Histopathological changes in the knee joints were scored in the patella and femur/tibia regions on five semiseria sections of the joint, spaced 70 μm apart. Immunohistochemistry was quantified using an automated image analysis system (Leica Q500/N; Leica Imaging Systems Ltd., Cambridge, United Kingdom). Microscopic images were recorded by a CDD video camera (Victor Company of Japan Ltd., Tokyo, Japan) and processed by a personal computer. Optical density was measured in the cartilage or synovium. For cartilage, the whole area of noncalcified cartilage was scanned, and staining was expressed per unit of tissue (μm^2). For synovium, a defined area along the cortical bone was scanned, using a standardized template. Five sections per joint were scanned. Staining values were corrected for background staining, as measured in the control vector group. Scoring was performed by two observers without knowledge of the experimental group, as described earlier (24).

Immunohistochemistry of OPGL. Whole knee joints were fixed, decalcified and paraffin embedded as already describe here. Tissue sections (7 μm) were treated with 1% H_2O_2 for 10 minutes at room temperature. Sections were incubated for 1 hour with the primary Ab RANKL (goat polyclonal Ab raised against a peptide mapping at the NH_2 -terminus of RANKL (RANK ligand) of mouse origin (N-19; Santa Cruz Biotechnology Inc., Santa Cruz, California, USA) or a control goat IgG Ab (Jackson ImmunoResearch Laboratories, West Grove, Pennsylvania, USA). After rinsing, sections were blocked with 4% normal mouse serum for 20 minutes

at room temperature. Thereafter, sections were incubated for 30 minutes with biotinylated mouse anti-goat IgG (Jackson ImmunoResearch Laboratories) and detected using biotin-streptavidin/peroxidase staining (Elite kit; Vector Laboratories, Burlingame, California, USA). Development of the peroxidase staining was done with 3',3'-diaminobenzidine (Sigma Chemical Co.). Counterstaining was done with Mayer's hematoxylin.

Immunohistochemical staining of type II collagen neoepitopes. Whole knee joints were fixed for 2 days in 10% formalin, followed by decalcification in 10% EDTA (Titriplex III), 7.5% polyvinylpyrrolidone (PVP; M_r 29,000; Serva, Amsterdam, The Netherlands) in 0.1M phosphate buffer (pH 7.4) for 2 weeks at 4°C. After extensive rinsing with 7.5% PVP in 0.1M phosphate buffer, tissue blocks were rapidly frozen in liquid nitrogen and stored at -70°C. Whole knee joint sections (7 μm) were cut at 22°C on a micron cryostat and mounted on glass microscope slides precoated with 3-aminopropyltriethoxysilan (Sigma Chemical Co.). Sections were dried for 1 hour and stored at -70°C until further use. After thawing, the sections were fixed in freshly prepared 4% formaldehyde (5 minutes) and washed extensively in 0.1 M PBS (pH 7.4) for 15 minutes. Sections were incubated with 1% hyaluronidase (type I-s; Sigma Chemical Co.) for 30 minutes at 37°C, to remove proteoglycans. After treatment with 1% H_2O_2 for 30 minutes, nonspecific staining was blocked by incubation with 10% normal goat serum with 1% BSA. Sections were incubated overnight with the primary rabbit Ab Col2-3/4C_{short} (kindly provided by A.R. Poole [McGill University, Montreal, Canada]) directed against the COOH-terminal neoepitope generated by cleavage of native human type II collagen by collagenases, which has been described and characterized previously (42). The Col2-3/4C_{short} antiserum detects the COOH-terminal neoepitope that can be generated by

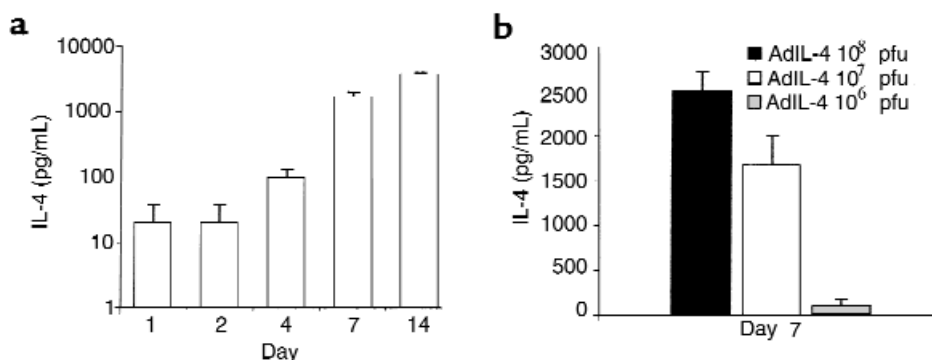
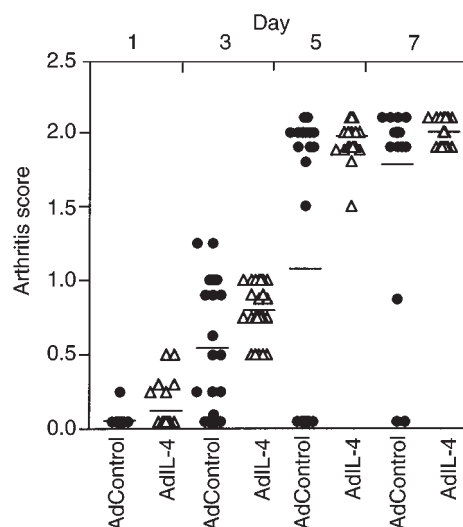


Figure 1

Adenoviral vector-mediated IL-4 expression in the mouse knee joint. (a) 1.10^7 pfu of Ad5E1mIL-4 was given intra-articularly to naive C57bl/6 mice and patella with adjacent synovium was taken in a standardized manner on days 1, 2, 4, 7, and 14 to measure IL-4 in the washouts of joint tissue by ELISA. The control vector of the same dose and the washouts from the contralateral knee both gave rise to undetectable levels of IL-4 (not graphed). Results are expressed as mean \pm SD of four mice per time point. (b) Various doses of AdE1mIL-4 were given intra-articularly to naive C57bl/6 mice, and IL-4 was measured in washouts of joint tissue at day 7 by ELISA. Results are expressed as mean \pm SD of four mice per dose. The detection limit of the mIL-4 ELISA is 5 pg/mL.

Figure 2

Kinetic study of the course of collagen arthritis in the knee joint after intra-articular injection of Ad5E1mIL-4 and Ad5del70-3. Collagen type II-immunized DBA-1 mice were injected intra-articularly in the right knee joint with 1.10^7 pfu of either Ad5E1mIL-4 or Ad5del70-3 before onset of CIA was noted. At days 1, 3, 5, and 7 after intra-articular injection of the viral vector, mice were sacrificed by cervical dislocation, and the skin of the knee joint was removed. The appearance of arthritis in the injected joints was visually scored for severity (arthritis score). Results are the mean \pm SD of two separate experiments with a total of at least 22 mice per group. Ad control, Ad5del70-3.



matrix metalloproteinase-1 (MMP-1), MMP-8, MMP-13, and probably also by MMP-2 (43). After extensive rinsing, sections were incubated with biotinylated goat anti-rabbit IgG and detected using biotin-streptavidin/peroxidase staining (Elite kit). Development of the peroxidase staining was done with 3',3'-diaminobenzidine (Sigma Chemical Co.). Counterstaining was done with Mayer's hematoxylin.

Preparation of bone fragments. Rheumatoid bone samples were obtained from patients with osteoarthritis (OA) and RA, according to the revised criteria of the American College of Rheumatology (44), who were undergoing knee or wrist synovectomy, or joint replacement. Bone fragments were prepared as described previously (30). Samples were cut into small pieces of approximately 2 mm³ and incubated in triplicate in complete medium consisting of MEM medium (GIBCO BRL), 2 mM L-glutamin, 100 U/mL penicillin, 50 mg/mL gentamicin, 20 mM HEPES buffer, and 10% FCS. Cultures were performed at 37°C in a 5% CO₂/95% humidified air. Bone fragments were cultured in 24-well plates (Falcon, Oxnard, CA) in a final volume of 2 mL. The cytokines to be tested were added at the beginning of the culture.

Measurement of collagen degradation. Type I collagen C-telopeptide breakdown products (CTX) were measured in synovium piece culture supernatants by a two-site ELISA (Serum Crosslaps One-Step, Osteometer Biotech, Ballerup, Denmark) using two mAb's raised against a synthetic peptide with an amino acid sequence specific for a part of the C-telopeptide of α 1-chain of type I collagen (45). Intra- and interassay CVs are lower than 5% and 8%, respectively, and the sensitivity is 154 pmol/L.

Determination of type I collagen production. The production of type I collagen was estimated in 48-hour culture media by measuring the concentration of the C-propeptide of type I collagen (PICP) using a two-site ELISA that uses an mAb and a polyclonal Ab raised against human PICP purified from skin fibroblast cultures (Procollagen-C, Metra Biosystem Inc., Palo Alto, California, USA)

(46, 47). The sensitivity of the assay is 1 ng/mL, and the intra- and interassay CV were below 7%.

Statistical analysis. Means \pm SD of the various groups were determined and potential differences between experimental groups were tested using the Mann-Whitney rank sum test, unless stated otherwise.

Results

Intra-articular Ad5E1mIL-4 gene transfer in the mouse knee joint. Naive C57bl/6 mice were intra-articularly injected in the right knee joint with 1.10^7 pfu of Ad5E1mIL-4, and IL-4 levels were measured at different time points in washouts of joint tissue. This dose of adenovirus did not induce joint inflammation in a knee joint of naive mice (48). Low levels of IL-4 were found the first 2 days after a single injection of Ad5E1mIL-4, after which IL-4 levels increased in time (Figure 1a). The same expression pattern was found in IL-4 gene knockout mice (data not shown), indicating that rise of

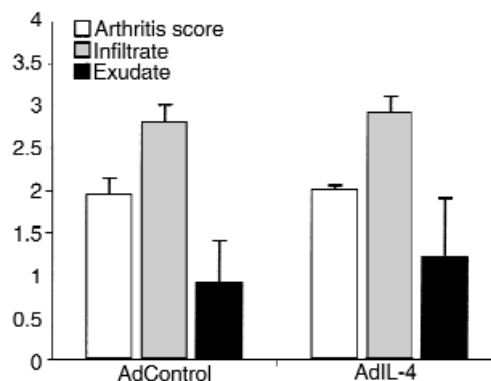
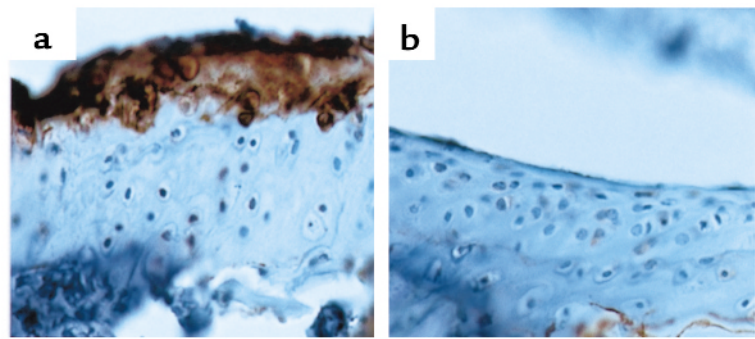


Figure 3

Analysis of the inflammatory aspects of local IL-4 overexpression in the knee joint of mice with collagen-induced arthritis. Knee joints were taken for histology. Synovial infiltrate and exudate were scored on a scale of 0-3. Results are the mean \pm SD of four separate experiments with at least eight mice per group per experiment. For details, see Figure 2.

Figure 4

Effects of local IL-4 on collagen breakdown. (a) Arthritic knee joint of a mouse 7 days after intra-articular injection of 1.10^7 pfu of Ad5del70-3 showing staining for type II collagen breakdown epitope, detected with mAb Col2-3/4C_{short}. (b) Knee joint of a mouse 7 days after intra-articular injection of 1.10^7 pfu of Ad5E1mIL-4. Note the decreased staining of collagen type II breakdown epitope. **a** and **b**, $\times 250$.



IL-4 levels in time was not due to autoinduction of IL-4. The adenoviral vector-mediated IL-4 expression in the mouse knee joint was vector dose related (Figure 1b). No detectable levels of IL-4 were found in washouts from the contralateral knee or the Ad5del70-3 control vector injected knee or in sera from Ad5E1mIL-4-injected animals (data not shown).

Intra-articular Ad5E1mIL-4 gene transfer in the knee joint of CII-immunized mice. DBA-1 mice were immunized with CII, and shortly before expected onset of collagen arthritis, a single injection of 1.10^7 pfu of Ad5E1mIL-4 or control vector was given in the right knee joint. At days 7 and 14 after the intra-articular injection of Ad5E1mIL-4, relatively high IL-4 levels (333 ± 105 and 416 ± 230 pg/mL, respectively) were measured in washouts of joint tissue of the IL-4 group. No detectable IL-4 was noted in washouts of the knee joints injected with the control vector (Ad5del70-3). No difference was noted in the course of the collagen arthritis in the injected knee joints between the IL-4 group and the control vector group (Figure 2). In line with our previous study (26), at day 7, a 100% arthritis incidence was noted in the right knee joint of the IL-4 group with a severity score of 2.0 ± 0.2 compared with 90% incidence in the control vector group with an arthritis score of 1.8 ± 0.6 (Figure 3). No obvious differences in severity were found in the infiltrate and exudate between the Ad5E1mIL-4 group and the Ad5del70-3 control group (Figure 3).

Table 1

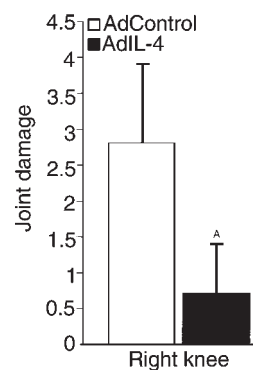
Classification of individual mice, with respect to degree of joint destruction after Ad5E1mIL-4 treatment^A

	Joint destruction ^B	
	Ad5del70-3	Ad5E1mIL-4 ^C
None	0	5
Mild	4	7
Marked	4	0
Severe	4	0

^ASee Figure 4 for more detail on the experimental protocol. ^BArthritic mice were classified according to their degree of joint destruction, as scored radiologically on whole knee joints. Whole knee joints were scored using a scale of no changes (none), minor destruction, one spot per area (mild), marked changes in more areas (marked), and severe erosions afflicting the joint (severe). χ^2 test showed significance ($P < 0.001$) between Ad5E1mIL-4 and Ad5del70-3 treatment comparing none/mild and marked/severe groups. ^CNumber of mice.

IL-4 prevents collagen breakdown during collagen arthritis. Collagen breakdown leads to irreversible joint damage. We investigated the impact of local IL-4 application on collagen breakdown during collagen arthritis. Histological knee joint sections were stained with Ab's recognizing type II collagen breakdown neopeptides. We found less collagen type II breakdown neopeptide expression in the IL-4 group compared with the control group ($72 \pm 16\%$ [SD] suppression; mean of 10 samples) (Figure 4), which is in line with our earlier findings that IL-4 prevents cartilage erosion.

Local IL-4 overexpression prevents localized bone erosion during collagen arthritis. Whole knee joints were radiologically scored for the degree of joint destruction. Seven and 14 days after the viral injection, x-ray analysis showed marked joint destruction in the control vector group (Figures 5 and 6, b and d). Interestingly, local IL-4 treatment strongly reduced the degree of joint destruction (75%) ($P < 0.001$) (Figure 5). At days 7 and 14 after the viral injection, marked prevention of joint damage was still noted in the IL-4 group compared with the control vector group (Figure 6, c and e). In addition, mice were ranked for individual scores of

**Figure 5**

X-ray analysis of joint damage in CIA after one intra-articular injection of Ad5E1mIL-4. Immunized DBA-1 mice were injected intra-articularly in the right knee with 1.10^7 pfu of Ad5E1mIL-4 or Ad5del70-3 before onset of CIA was noted. Seven days later, mice were sacrificed by cervical dislocation, and the knee joints were taken for x-ray analysis. Joint damage was scored on a scale of 0–5. Results are the mean \pm SD with 12 mice per group. ^A $P < 0.001$ versus control group, by Mann-Whitney rank sum test.

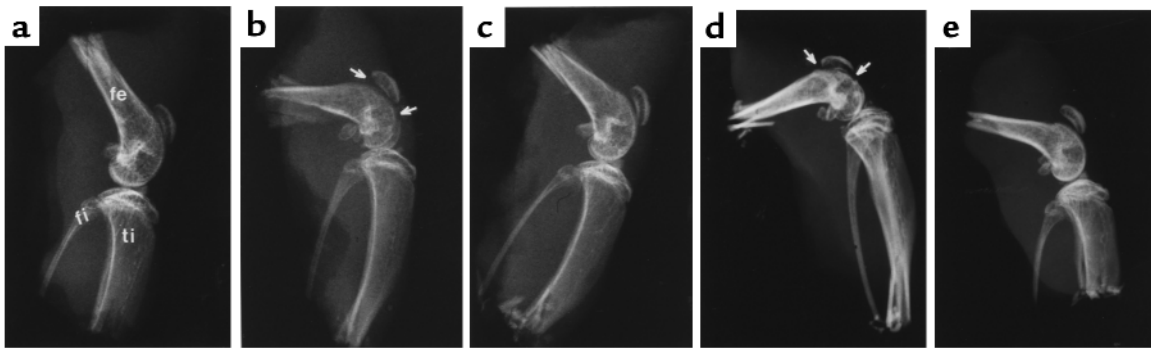


Figure 6

Effects of Ad5E1mIL-4 on joint damage and bone structure in CIA. (a) Knee joint of a naive DBA-1 mouse. (b and d) Arthritic knee joint of a mouse 7 and 14 days, respectively, after intra-articular injection of 1.10^7 pfu of Ad5del70-3 control vector. Note the enhanced joint damage and less-compact bone structure (arrows). (c and e) Knee joint of a mouse 7 and 14 days, respectively, after intra-articular injection of 1.10^7 pfu of Ad5E1mIL-4. Note the prevention of joint damage and the compact bone structure. fe, femur; fi = fibula; ti = tibia.

joint destruction in four subclasses (Table 1). Whereas the majority of mice of the control group were ranked as having severe destruction, none of the mice of the IL-4 group was in this category. All mice of the IL-4 group were ranked as having no or mild destruction.

A characteristic histological parameter in collagen arthritis is the progressive loss of bone at the joint margins. Subchondral and cortical bone destruction was scored on semiseriate knee joint sections in the patella and femur/tibia region. Hyperplastic synovial tissue, consisting of synoviocytes extends over the cortical bone surface of the patella and femur/tibia in the arthritic control group and the IL-4-treated group (Figure 7a). Profound bone erosions were found in the control, arthritic group (Figures 7b, and 8, a-d). Destruction of subchondral bone in the patella and femur region was noted (Figure 7c). Lateral and medial sites of the cortical bone of the patella and several parts of the femur/tibia were completely eroded (Figure 7d). Synoviocytes were noted in the erosion front. Inflammatory tissue seems to invade into the bone at

sites of bone erosion. Of high interest, despite the lack of difference in hyperplasia of synovial tissue that extends over the bone surface (Figure 7a), the degree of bone erosion was highly reduced in the IL-4-treated group ($P < 0.001$) (Figures 7 and 8, e-h). Mean values of two separate experiments revealed 70% and 68% reduction for this parameter in the subchondral bone of the patella and femur/tibia, respectively, and 58% and 62% reduction in the cortical bone of the patella and femur/tibia, respectively, in the IL-4 group compared with its respective adenoviral vector group.

Effects of IL-4 on osteoclast-like cells. Osteoclasts are potent bone resorbing cells and play an important role in joint destruction. TRAP activity is a characteristic phenotypic marker of osteoclasts and osteoclast precursors and is expressed in osteoclast-like cells in murine collagen-induced arthritis (10). To demonstrate further the protective effect of local IL-4, TRAP staining was performed on paraffin-embedded knee joint sections. TRAP-positive mononuclear cells were found in the erosive front in the control vector group

Figure 7

Histological analysis of bone erosion in CIA after one intra-articular injection of Ad5E1mIL-4. Immunized DBA-1 mice were injected intra-articularly in the right knee with 1.10^7 pfu of Ad5E1mIL-4 or Ad5del70-3 before onset of CIA was noted. Seven days later, mice were sacrificed by cervical dislocation, and the knee joints were taken for histology. Pannus formation (i.e., hyperplastic synovial tissue extending over the cortical bone surface) (a) and bone erosion (b) were scored on a scale of 0–3. Loss of subchondral (c) and cortical (d) bone in the patella and femur/tibia region was separately scored on a scale of 0–3. Results are the mean \pm SD of four separate experiments with at least eight mice per group per experiment. ^A $P < 0.001$; ^B $P = 0.003$; ^C $P = 0.005$ versus control group, by Mann-Whitney rank sum test.

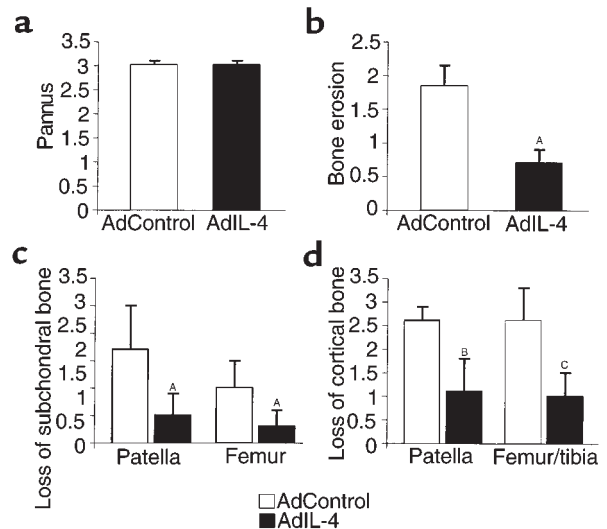
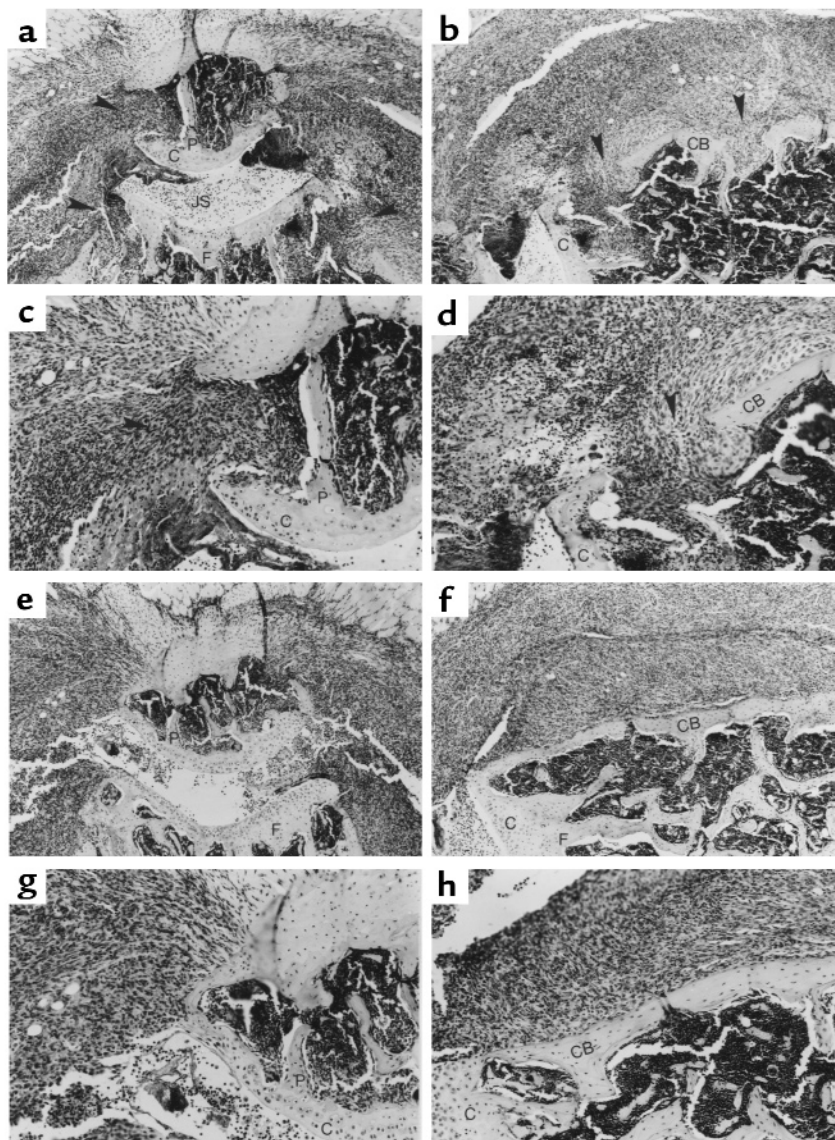


Figure 8

Effects of Ad5E1mIL-4 on bone erosion in CIA. (a-d) Arthritic knee joint of a mouse 7 days after intra-articular injection of 1.10^7 pfu of Ad5del70-3 control vector. Note the infiltrate and bone erosion (arrows). (e-h) Knee joint of a mouse 7 days after intra-articular injection of 1.10^7 pfu of Ad5E1mIL-4. Note the pronounced infiltrate, but prevention of bone erosion. a, b, e, and f, $\times 100$. c, d, g, and h, $\times 200$. H&E staining was used. P, patella; F, femur; JS, joint space; C, cartilage; S, synovium; CB, cortical bone.



(Figure 9, a-d). Local IL-4 overexpression in the knee joint of CII-immunized mice highly decreased the number of TRAP-positive mononuclear cells, indicating that IL-4 inhibits the formation of osteoclast-like cells (Figure 9, e-h).

The mechanism(s) involved in the formation and activation of osteoclasts in RA is still unknown. However, locally produced cytokines in the synovium, such as IL-1, IL-6, and TNF- α could provide signals for osteoclast differentiation and bone resorption (14-17). Local IL-4 gene therapy reduces the IL-1 β protein level (76%) found in the washouts of synovial tissue (26). No significant levels of free TNF- α was found in tissue washouts of either the IL-4-treated group or the control vector group (data not shown). IL-6 protein was much lower (56%) in the synovium washouts of the IL-4-treated group compared with the control vector group (Figure 10a).

Local IL-4 suppresses IL-17 and OPGL expression in the synovium. Many of the cytokines known to stimulate

bone resorption act through the upregulation of a novel and essential factor for osteoclastogenesis, OPGL (21). OPGL is produced by different cell types, including activated T cells (49). IL-17 is a T-cell-derived cytokine that was found in the synovium of a patient with RA and is a potent stimulator of osteoclastogenesis (19, 20). To get a better impression of potential changes in mediators involved in T-cell-driven activation, we analyzed IL-17 and IL-12 mRNA levels, using RT-PCR. Both cytokines were strongly reduced in the IL-4-treated mice and marked reduction of IL-12 protein levels (74%) was found (Table 2; Figure 10b).

OPGL expression was found in the synovium and at places where bone erosion takes place using RT-PCR and immunohistochemistry (Table 2; Figure 11). Intriguingly, OPGL expression was greatly reduced in the synovium by local IL-4 (Table 2; Figure 11c: $57 \pm 12\%$ [SD] suppression, mean of 10 samples). No difference in OPG mRNA expression

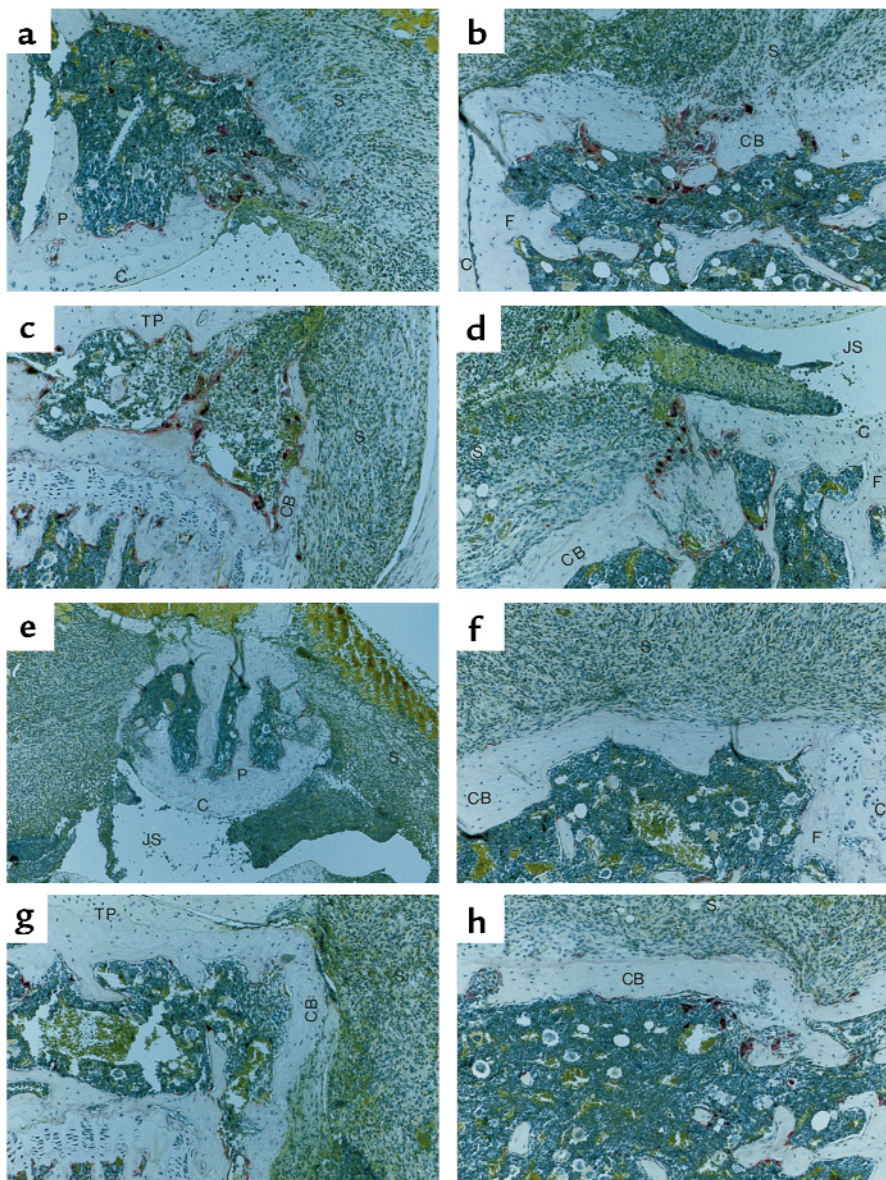


Figure 9
Effects of Ad5E1mIL-4 on osteoclast-like cells. (a-d) Arthritic knee joint of a mouse 7 days after intra-articular injection of 1.10^7 pfu of Ad5del70-3 control vector. Note the TRAP-positive mononuclear cells in the erosive front (red). (e-h) Knee joint of a mouse 7 days after intra-articular injection of 1.10^7 pfu of Ad5E1mIL-4. Note the decreased number of TRAP-positive mononuclear cells. e, $\times 100$. a-d and f-h, $\times 200$. P, patella; F, femur; JS, joint space; C, cartilage; S, synovium; CB, cortical bone; TP, tibia plateau.

was noted between the IL-4 group and the control group (Table 2).

Ad5E1mIL-4 suppresses cysteine proteinase cathepsin K mRNA expression in synovial tissue. Cysteine proteinase cathepsin K probably is involved in osteoclast-mediated bone resorption (13, 50). Upregulation of cathepsin K mRNA expression in RA synovium compared with normal synovium has been reported (50). Cathepsin K was not only expressed by osteoclast but also by synovial fibroblast, suggesting that cathepsin K contributes to bone destruction mediated by RA synovial cells (50). We investigated the effects of local IL-4 overexpression on the cathepsin K expression in the synovial tissue. RT-PCR measurements revealed a strongly reduced level of cathepsin K in the synovial tissue by Ad5E1mIL-4 (Table 2).

IL-4 prevents collagen type I degradation in bone from patients with RA and those with OA. The major collagen type found in bone is type I collagen. The increased rate of bone

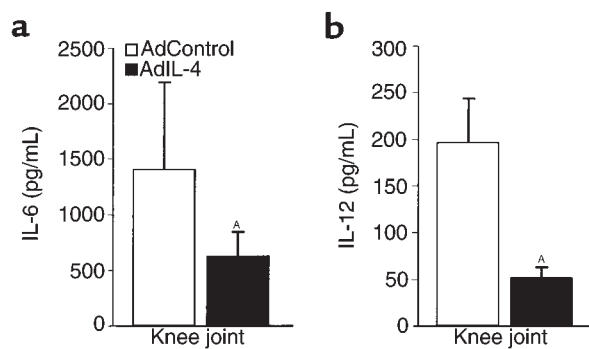
destruction is reflected by a COOH-terminal peptide released during the degradation of type I collagen. The effects of IL-4 on type I collagen CTX was tested in bone samples from five patients with RA and four with OA. CTX was found in the supernatants of these patients. Incubation with IL-4 for 7 days markedly suppressed CTX in the supernatant of all patients (mean: 70% for RA and 65% for OA), indicating that IL-4 strongly prevented collagen type I degradation (Table 3). In addition, we analyzed the effects of IL-4 on the synthesis of type I procollagen. It was found in all samples that formation was enhanced (mean: 77% for RA and 85% for OA), suggesting promotion of tissue repair (Table 3).

Discussion

We clearly demonstrated marked protection against joint destruction by local IL-4 overexpression in the inflamed joint. Radiological and histological analysis revealed pronounced protection against cartilage and

Figure 10

Local IL-4 overexpression in the knee joint of collagen type II-immunized mice suppresses local IL-6 and IL-12 protein levels. Collagen type II-immunized mice with a booster injection on day 22 were injected in the right and left knee joint on day 26 with 1.10^7 pfu of Ad5E1mIL-4 or Ad5del70-3 before onset of CIA was noted. Seven days after the intra-articular injection of the adenoviral vector, patella with adjacent synovium were isolated in a standardized manner from the knee joints and cultured for 1 hour in 200 μ L RPMI 1640 with 0.1% BSA medium at room temperature. IL-6 and IL-12 levels were measured in these culture supernatants using a specific ELISA. Results are the mean \pm SD of eight and nine patella washouts per group for IL-6 and IL-12, respectively. ^A*P* = 0.04 versus control group, by Mann-Whitney rank sum test.



bone erosion, despite full-blown arthritis. This protective effect of local IL-4 was associated with decreased formation of osteoclast-like cells and downregulation of IL-17, IL-6, IL-12, OPGL, and cathepsin K expression in the synovium. Furthermore, IL-4 inhibits the breakdown of type I collagen in bone samples from patients with arthritis. Interestingly, promotion of tissue repair by IL-4 was suggested through upregulation of type I procollagen in these cultures.

Lack of regulatory mediators such as IL-4 may contribute to the uneven balance of destructive and modulatory mediators in the synovium of the RA process. Understanding the regulation of the destructive process, the cytokines and cells that are involved may provide better therapeutic approaches in patients with RA. It is now generally accepted that TNF- α and IL-1 are key mediators in RA, and these proinflammatory cytokines play a critical role in the CIA (51). Studies in animal models identified the pivotal role of IL-1 in cartilage matrix degradation, whereas TNF- α plays a major role in the inflammatory process (51–56). Enhanced IL-1 β protein levels were found in

the arthritic synovial tissue (26), whereas, TNF- α protein levels were low in both the control vector and IL-4-expressing vector group, suggesting that IL-1 is enhancing osteoclast formation in CIA. Of high interest, local IL-4 treatment strongly reduced local IL-1 (26) in the arthritic synovium, indicating that IL-4 is an important regulator of this destructive mediator.

Protection of bone erosion was associated with decreased formation of osteoclast-like cells in the IL-4-treated mice. Locally produced cytokines in the synovium could provide signals for osteoclast differentiation and bone resorption (14–17). In addition to IL-1, IL-6 has been shown to be a powerful stimulator of osteoclast bone resorption. It is produced by the inflamed synovium and found in large amounts in RA synovial fluid (57, 58). It can induce osteoclast development and was shown to be directly involved in bone resorption in an in vivo model of osteoporosis, related to estrogen loss (59). Anti-IL-6 is inhibitory to osteoclast-like cell formation (10). In the present study, we found marked reduction of IL-6 in the arthritic synovium tissue after local IL-4 treatment, indicating that the mechanism of decreasing the number of osteoclast-like cells by local IL-4 treatment may, at least in part, be mediated by suppressing this important osteoclast stimulator. It is not yet clear whether IL-4 directly reduced IL-6 production or whether this is a result of marked suppression of IL-1 (26).

Osteoclasts differentiate from hematopoietic monocyte/macrophage precursors (4, 21). It has been demonstrated that osteoclast formation can occur in the absence of any bone or bone marrow-derived cells (60). Furthermore, it has been shown that synovial macrophages are capable of differentiating into osteoclasts in the presence of rheumatoid synovial fibroblasts (60), revealing that rheumatoid synovial cells contain both osteoclast progenitors and stromal cells supporting their differentiation (60). OPGL may play an important role in this differentiation pathway, as OPGL is considered a novel key regulator of osteoclastogenesis (21). Many of the cytokines known to stimulate bone resorption act through the upregulation of this novel and essential factor. The synovial lining is normally a thin layer, one to two

Table 2

Synovial mRNA levels after Ad5E1mIL-4 treatment^A

	PCR cycles ^B Synovium		Δ^D
	Ad5del70-3 ^C	Ad5E1mIL-4 ^C	
IL-17	34	> 42	-8
IL-12	30	36	-6
OPGL	30	34	-4
OPG	30	30	0
Cathepsin K	30	35	-5

^ASynovial mRNA levels were determined by RT-PCR technology, 7 days after the viral injection. Total RNA from six synovium biopsies of three mice were pooled, yielding two samples per group, as described in Methods. Values are the mean of two experiments with 12 mice per group. The PCR measurements of a particular mediator were routinely repeated three times. Samples (5 μ L) were taken at two-cycle intervals, with a total of six samples applied to the gel. The variations in the two repeated experiments never exceeded more than two cycles. ^BNumber of PCR cycles in which gene product of interest was first detectable. ^CImmunized DBA-1 mice were injected intra-articularly in the right knee joint with 1.10^7 pfu of Ad5E1mIL-4 or Ad5del70-3, before onset of CIA was noted. Messenger RNA expression was determined 7 days after the viral injection. ^D Δ refers to the difference between the respective Ad5del70-3- and Ad5E1mIL-4-treated conditions.

cells in thickness, which consist of type A and B cells, showing macrophages and fibroblast-like properties. During (chronic) joint inflammation, considerable thickening of the lining is a characteristic event, and the subsynovial tissue becomes infiltrated by numerous macrophages and lymphocytes. Therefore, osteoclasts differentiated from monocyte/macrophage precursors in the synovial membrane are probably involved in bone destruction in arthritis. Interestingly, we found OPGL expression in the synovium and at sites where bone erosion takes place in the arthritic control group. Furthermore, we found osteoclast-like cells in the erosive front in the knee joint of the arthritic control mice showing severe joint destruction, which is compatible with an earlier study demonstrating direct participation of osteoclast-like cells in the joint destruction of CIA (10). Moreover, at bone erosion sites, the receptor of OPGL, RANK was expressed in areas where OPGL expression was found (E. Lubberts et al., manuscript in preparation). Remarkably, local IL-4 treatment suppressed OPGL expression and highly reduced numbers of osteoclast-like cells, suggesting that local IL-4 overexpression interferes in the differentiation pathway of macrophage precursors to osteoclasts.

We found reduced numbers of osteoclast-like cells after local IL-4 treatment, whereas the amount of inflammatory cells in the synovial tissue was not reduced. A similar situation has been described in osteomyelitis, where reduced osteoclast activity was observed in bone adjacent to infection, without a notable decrease in the inflammatory mass (61). This suggests that the inflammatory cells can be there, but do not necessarily display a destructive phenotype. It was shown that the T-cell-derived cytokine IL-17, which is expressed in the synovium of patients with RA (19, 20), is a potent stimulator of osteoclastogenesis (19). To get a better impression of potential changes in mediators involved in T-cell-driven activation, we analyzed IL-12 and IL-17 levels. Both cytokines were strongly reduced in the IL-4-treated mice. Activated, but not resting, T cells can directly trigger osteoclastogenesis through OPGL (49), and, as already discussed, also OPGL mRNA expression was greatly reduced. Interestingly, no difference was found in OPG expression between the control group and the IL-4 group, suggesting that IL-4 suppresses the OPGL/OPG balance. These data indicate that T-cell-driven OPGL production is a pivotal element in bone erosion in collagen arthritis and that IL-4 inhibits this process either directly, or through down-regulation of cytokines involved in T-cell maturation and mediator production. Investigation into further characterization of the IL-12, IL-17, and OPGL interplay is currently under way.

Cysteine proteinase cathepsin K expression is highly tissue specific and is predominantly expressed in osteoclasts (62, 63) and fibroblasts, but hardly in macrophages (50). Cathepsin K has been suggested to

be a key enzyme in diseases associated with excessive loss of bone (50). In the present study, we found marked reduction of mRNA expression of cathepsin K in synovial tissue by local IL-4, which is in line with reduced numbers of osteoclast-like cells. In addition, it implies that IL-4 may have a direct effect on the cathepsin K production in fibroblasts.

In most metabolic bone diseases, both bone formation and bone resorption are altered. To analyze these elements in bone samples of patients with arthritis,

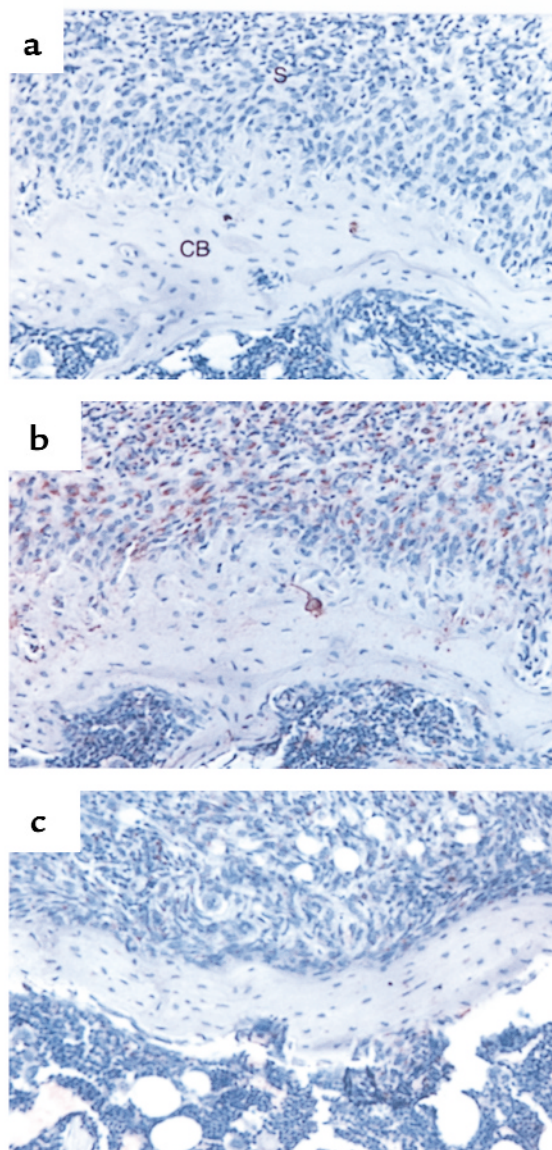


Figure 11 Effects of IL-4 on OPGL expression in the synovium. (a and b) Arthritic knee joint of a mouse 7 days after intra-articular injection of 1.10^7 pfu of Ad5del70-3 control vector showing staining for OPGL, detected with a control anti-goat Ab (a) or the anti-RANKL Ab (b). Note the OPGL expression in the synovium and in cells along the cortical bone. (c) Knee joint of a mouse 7 days after intra-articular injection of 1.10^7 pfu of Ad5E1mIL-4 showing staining for OPGL, detected with the anti-RANKL Ab. Note the decreased OPGL expression in the synovium and in cells along the cortical bone. a-c, $\times 250$. S, synovium; CB, cortical bone.

Table 3IL-4 prevents collagen type I breakdown but enhances procollagen type I formation in bone from patients with arthritis^A

	CTX (nM) ^B			PICP (ng/mL) ^B		
	0	+ IL-4		0	+ IL-4	
RA1	89.9 ± 54.2	17.5 ± 7.8	-80 ^C	284.9 ± 4.2	441.7 ± 2.3	+55 ^C
RA2	80.0 ± 7.9	1.0 ± 0.5	-99	211.6 ± 17.4	388.8 ± 30.5	+83
RA3	40.6 ± 14.5	5.3 ± 4.2	-88	246.2 ± 14.2	412.7 ± 32	+67
RA4	99.4 ± 7.3	44.3 ± 5.8	-55	381.9 ± 59.3	980.0 ± 234.2	+156
RA5	88.7 ± 5.4	63.0 ± 3.1	-29	300.1 ± 6.5	379.3 ± 66.4	+26
Mean of percent variation			-70 ± 28 ^D			+77 ± 48 ^D
OA1	157.0 ± 8.5	19.2 ± 8.5	-87 ^C	932.7 ± 64	2,467 ± 169	+163 ^C
OA2	25.9 ± 15.3	20.2 ± 7.3	-22	1,362.3 ± 58	1,901 ± 79	+39
OA3	9.9 ± 1.6	3.7 ± 1.6	-88	284.9 ± 4.2	441.7 ± 2.3	+55
OA4	2.1 ± 1.1	1.9 ± 0.8	-62	211.6 ± 87.3	388.8 ± 30.4	+83
Mean of percent variation			-65 ± 31 ^D			+85 ± 55 ^D

^ARA and OA bone samples from five and four patients, respectively, were incubated for 7 days in the presence of IL-4 (50 ng/mL). ^BLevels of CTX and PICP in supernatants were measured by ELISA. Results are expressed as mean ± SD of culture triplicates with percent variations from baseline. ^CColumn represents percent induction. ^D*P* < 0.05; differences between IL-4-treated and control group were compared with the paired Wilcoxon test.

we have taken the same biochemical assays as are used routinely in bone metabolic studies. This includes the measurement of PICP as a marker of procollagen synthesis by osteoblasts and CTX, a COOH-terminal peptide, as a marker of type I collagen degradation (64–66). Earlier studies already indicated that high serum and urinary levels of CTX reflect increased bone destruction in patients with RA, and a positive correlation with x-ray destruction was demonstrated (67). In the present study, we show that IL-4 can suppress CTX release in cultures of bone explants of patients with arthritis, but also enhanced the formation of type I procollagen. As such, IL-4 exerts a dual positive effect. This adds clinical relevance to the convincing protective effect noted with IL-4 in the collagen arthritis model.

Cartilage damage is usually linked to bone erosion, and MMPs are crucial in late, irreversible cartilage damage. In the present study, we confirmed the cartilage protective effect of local IL-4 (26) and found less collagen type II breakdown neoepitope expression, which can be generated by MMP-1, -8, -13, and probably also by MMP-2 (43). This suggests that IL-4 reduces collagenase activity, either directly or through reduction of stromelysin-1, which is essential in collagenase activation. Further characterization of the IL-4 effect on MMP activity is warranted.

Previous studies from our group have revealed the potential uncoupling of inflammation and joint destruction. TGF- β showed enhanced fibrosis but ameliorated cartilage damage (68). In addition, selective elimination of synovial lining cells with toxic liposomes can prevent the expression of joint inflammation; however, this treatment is not necessarily protective against cartilage damage (68). Furthermore, OPG treatment in adjuvant-induced arthritis completely abolished the loss of mineral bone density however, had no effect on the severity of inflammation (49). Another important demonstration showing protection of the skeleton from damage

when inflammation is essentially unaffected was reported by Bresnihan et al. (69). In this human clinical study with IL-1 receptor antagonist, beneficial effect on the rate of joint erosion was shown, although the inflammation was not significantly arrested. The present study clearly shows uncoupling of inflammation and surface erosion of bone and cartilage. All of this underscores the concept that the balance of destructive and protective mediators determines the relative erosive nature of a given arthritis, rather than the bulk of the inflammatory mass.

In conclusion, this is the first report demonstrating clear bone protective effects of local IL-4 gene therapy in experimental arthritis, despite severe inflammation. Furthermore, IL-4 prevented collagen type I degradation in bone samples of patients with arthritis, and interestingly, it stimulated the formation of type I procollagen. Because the control of bone destruction is the most difficult target in the treatment of patients with arthritis, our data have significant implications for the prevention of bone erosion in arthritis.

Acknowledgments

We acknowledge The Central Animal Laboratory, Faculty of Medicine, University of Nijmegen for animal care. We thank A.R. Poole for providing us with Col2-3/4C_{short} Ab, and M. Helsen and E. Vitters for technical assistance. This work was supported by grants from The Dutch League against Rheumatism (grant 742) and from the European Union (Biomed-2 Program BMH4-CT96-1698), and partially by the Hamilton Health Sciences Corp., and St. Joseph's Hospital, Hamilton, Ontario, Canada.

1. Nijweide, P.J., Burger, E.H., and Feyen, J.H.M. 1986. Cells of the bone: proliferation, differentiation, and hormonal regulation. *Physiol. Rev.* **66**:855–886.
2. Manolagas, S.C., and Jilka, R.L. 1995. Bone marrow, cytokines, and bone remodeling: emerging insights into the pathophysiology of osteoporosis. *N. Engl. J. Med.* **332**:305–311.
3. Roodman, G.D. 1996. Advances in bone biology: the osteoclast. *Endocr. Rev.* **17**:308–332.

4. Suda, T., Takahashi, N., and Martin, T.J. 1992. Modulation of osteoclast differentiation. *Endocr. Rev.* **13**:66-80.
5. Firestein, G.S., Alvaro-Garcia, J.M., and Maki, R. 1990. Quantitative analysis of cytokine gene expression in rheumatoid arthritis. *J. Immunol.* **144**:3347-3353.
6. Chen, E., Keystone, E.C., and Fish, E.N. 1993. Restricted cytokine expression in rheumatoid arthritis. *Arthritis Rheum.* **36**:901-910.
7. Bromley, M., and Wooley, D.E. 1984. Chondroclasts and osteoclasts at subchondral sites of erosion in the rheumatoid joint. *Arthritis Rheum.* **27**:968-975.
8. Leisen, J.C.C., Duncan, H., Riddle, J.M., and Richford, W.C. 1988. The erosive front: a topographic study of the junction between the panus and the subchondral plate in the macerated rheumatoid metacarpal head. *J. Rheumatol.* **15**:17-22.
9. Gravalles, E.M., et al. 1998. Identification of cell types responsible for bone resorption in rheumatoid arthritis and juvenile rheumatoid arthritis. *Am. J. Pathol.* **152**:943-951.
10. Suzuki, Y., Nishikaku, F., Nakatuka, M., and Koga, Y. 1998. Osteoclast-like cells in murine collagen induced arthritis. *J. Rheumatol.* **25**:1154-1160.
11. Arend, W.P., and Dayer, J.-M. 1995. Inhibition of the production and effects of interleukin-1 and tumor necrosis factor α in rheumatoid arthritis. *Arthritis Rheum.* **38**:151-160.
12. Feldmann, M., Elliot, M.J., Woody, J.N., and Maini, R.N. 1997. Anti-tumor necrosis factor-alpha therapy of rheumatoid arthritis. *Adv. Immunol.* **64**:282-350.
13. Müller-Ladner, U., Gay, R.E., and Gay, S. 1998. Molecular biology of cartilage and bone destruction. *Curr. Opin. Rheumatol.* **10**:212-219.
14. Pfeilschiffer, J., Chenu, C., Bird, A., Mundy, G.R., and Roodman, G.D. 1989. Interleukin-1 and tumor necrosis factor stimulate the formation of human osteoclast-like cells in vitro. *J. Bone Miner. Res.* **4**:113-118.
15. Lowik, C.W., et al. 1989. Parathyroid hormone and PTH-like protein stimulated interleukin-6 production by osteogenic cells: a possible role of interleukin-6 in osteoclastogenesis. *Biochem. Biophys. Res. Commun.* **162**:546-552.
16. Ishimi, Y., et al. 1990. IL-6 is produced by osteoblasts and induces bone resorption. *J. Immunol.* **146**:3297-3303.
17. De la Mata, J., et al. 1995. Interleukin-6 enhances hypercalcemia and bone resorption mediated by parathyroid hormone-related protein in vivo. *J. Clin. Invest.* **95**:2846-2852.
18. O'Keefe, R.J., et al. 1997. Osteoclasts constitutively express regulators of bone resorption: an immunohistochemical and in situ hybridization study. *Lab. Invest.* **76**:457-465.
19. Kotake, S., et al. 1999. IL-17 in synovial fluids from patients with rheumatoid arthritis is a potent stimulator of osteoclastogenesis. *J. Clin. Invest.* **103**:1345-1352.
20. Chabaud, M., et al. 1999. Human interleukin-17: a T cell-derived proinflammatory cytokine produced by the rheumatoid synovium. *Arthritis Rheum.* **42**:963-970.
21. Kong, Y.-Y., et al. 1999. OPGL is a key regulator of osteoclastogenesis, lymphocyte development and lymph-node organogenesis. *Nature.* **397**:315-323.
22. Chomarat, P., and Banchereau, J. 1997. An update on interleukin-4 and its receptor. *Eur. Cytokine Netw.* **8**:333-344.
23. Moore, K.W., O'Garra, A., De Waal-Malefyt, R., Vieira, P., and Mosmann, T.R. 1993. Interleukin-10. *Annu. Rev. Immunol.* **11**:165-190.
24. Joosten, L.A.B., et al. 1997. Role of interleukin-4 and interleukin-10 in murine collagen-induced arthritis. Protective effect of interleukin-4 and interleukin-10 treatment on cartilage destruction. *Arthritis Rheum.* **40**:249-260.
25. Lubberts, E., Joosten, L.A.B., Helsen, M.M.A., and Van den Berg, W.B. 1998. Regulatory role of interleukin-10 in joint inflammation and cartilage destruction in murine streptococcal cell wall arthritis. More therapeutic benefit with IL-4/IL-10 combination therapy than with IL-10 treatment alone. *Cytokine.* **10**:361-369.
26. Lubberts, E., et al. 1999. Adenoviral vector-mediated overexpression of IL-4 in the knee joint of mice with collagen-induced arthritis prevents cartilage destruction. *J. Immunol.* **163**:4546-4556.
27. Miossec, P., and Van den Berg, W.B. 1997. Th1/Th2 cytokine balance in arthritis. *Arthritis Rheum.* **40**:2105-2115.
28. Watanabe, K., et al. 1990. Interleukin-4 as a potent inhibitor of bone resorption. *Biochem. Biophys. Res. Commun.* **172**:1035-1041.
29. Bizzarri, C., et al. 1994. Interleukin-4 inhibits bone resorption and acutely increases cytosolic Ca²⁺ in murine osteoclasts. *J. Biol. Chem.* **269**:13817-13824.
30. Miossec, P., et al. 1994. Interleukin-4 inhibits bone resorption through an effect on osteoclasts and proinflammatory cytokines in an ex vivo model of bone resorption in rheumatoid arthritis. *Arthritis Rheum.* **37**:1715-1722.
31. Onoe, Y., et al. 1996. IL-13 and IL-4 inhibit bone resorption by suppressing cyclooxygenase-2-dependent prostaglandin synthesis in osteoblast. *J. Immunol.* **156**:758-764.
32. Riancho, J.A., Zarrabeitia, M.T., Mundy, G.R., Yoneda, T., and Gonzalez-Macias, J. 1993. Effects of interleukin-4 on the formation of macrophages and osteoclast-like cells. *J. Bone Miner. Res.* **8**:1337-1344.
33. Kasono, K., et al. 1993. Inhibitory effect of interleukin-4 on osteoclast-like cell formation in mouse bone marrow culture. *Bone Miner.* **21**:179-188.
34. Trentham, D.E., Townes, A.S., and Kang, A.H. 1977. Autoimmunity to type II collagen: an experimental model of arthritis. *J. Exp. Med.* **146**:857-868.
35. Courtenay, J.S., Dallman, M.J., Dayan, A.B., Martin, A., and Mosedale, B. 1980. Immunization against heterologous type II collagen-induced arthritis in mice. *Nature.* **283**:666-668.
36. Stuart, J.M., Townes, A.S., and Kang, A.H. 1982. Nature and specificity of immune responses to collagen in type II collagen-induced arthritis in mice. *J. Clin. Invest.* **69**:673-683.
37. Hogaboam, C.M., et al. 1997. Therapeutic effects of interleukin-4 gene transfer in experimental inflammatory bowel disease. *J. Clin. Invest.* **100**:2766-2776.
38. Xing, Z., Ohkawara, Y., Jordana, M., Graham, F.L., and Gaudie, J. 1996. Transfer of GM-CSF gene to rat lung induces eosinophilia, monocytosis and fibrotic reactions. *J. Clin. Invest.* **97**:1102-1110.
39. Van Meurs, J.B.J., Van Lent, P.L.E.M., Joosten, L.A.B., Van der Kraan, P.M., and Van den Berg, W.B. 1997. Quantification of mRNA levels in joint capsule and articular cartilage of the murine knee joint by RT-PCR. *Rheumatol. Int.* **16**:197-205.
40. Chomczynski, P., and Sacchi, N. 1987. Single step method of RNA isolation by acid guanidinium thiocyanate-phenol-chloroform extraction. *Anal. Biochem.* **162**:156-159.
41. Van den Berg, W.B., Joosten, L.A.B., and Van de Putte, L.B.A. 1984. Electrical charge of the antigen determines intraarticular handling and chronicity of arthritis in mice. *J. Clin. Invest.* **74**:1850-1859.
42. Billingham, R.C., et al. 1997. Enhanced cleavage of type II collagen by collagenases in osteoarthritic articular cartilage. *J. Clin. Invest.* **99**:1534-1545.
43. Aimes, R.T., and Quigley, J.P. 1995. Matrix metalloproteinase-2 is an interstitial collagenase. Inhibitor-free enzyme catalyzes the cleavage of collagen fibrils and soluble native type I collagen generating the specific 1/4- and 3/4-length fragments. *J. Biol. Chem.* **270**:5872-5876.
44. Arnett, F.C., et al. 1988. The American Rheumatism Association 1987 revised criteria for the classification of rheumatoid arthritis. *Arthritis Rheum.* **31**:315-324.
45. Bonde, M., et al. 1997. Measurement of bone degradation products in serum using antibodies reactive with an isomerized form of an 8 amino acid sequence of the C-telopeptide of type I collagen. *J. Bone Miner. Res.* **12**:1028-1034.
46. Garner, P., Sornay-Rendu, E., Chapuy, M.C., and Delmas, P.D. 1996. Increased bone turnover in late postmenopausal women is a major determinant of osteoporosis. *J. Bone Miner. Res.* **11**:337-349.
47. Kikuchi, K., et al. 1995. Elevated procollagen type I carboxyterminal propeptide production in cultured scleroderma fibroblasts. *Dermatology.* **190**:104-108.
48. Lubberts, E., et al. 2000. Intra-articular IL-10 gene transfer regulates the expression of collagen-induced arthritis (CIA) in the knee and ipsilateral paw. *Clin. Exp. Immunol.* **120**:375-383.
49. Kong, Y.-Y., et al. 1999. Activated T cells regulate bone loss and joint destruction in adjuvant arthritis through osteoprotegerin ligand. *Nature.* **402**:304-309.
50. Hummel, K.L., et al. 1998. Cysteine proteinase cathepsin K mRNA is expressed in synovium of patients with rheumatoid arthritis and is detected at sites of synovial bone destruction. *J. Rheumatol.* **25**:1887-1894.
51. Joosten, L.A.B., Helsen, M.M.A., Van de Loo, F.A.J., and Van den Berg, W.B. 1996. Anticytokine treatment of established type II collagen-induced arthritis in DBA/1 mice: a comparative study using anti-TNF α , anti-IL-1 α/β , and IL-1Ra. *Arthritis Rheum.* **39**:797-809.
52. Van den Berg, W.B., Joosten, L.A.B., Helsen, M.M.A., and Van de Loo, F.A.J. 1994. Amelioration of established murine collagen-induced arthritis with anti-IL-1 treatment. *Clin. Exp. Immunol.* **11**:237-243.
53. Bakker, A.C., et al. 1997. Prevention of murine collagen-induced arthritis in the knee and ipsilateral paw by local expression of human interleukin-1 receptor antagonist protein in the knee. *Arthritis Rheum.* **40**:893-900.
54. Van de Loo, F.A.J., Joosten, L.A.B., Van Lent, P.L.E.M., Arntz, O.J., and Van den Berg, W.B. 1995. Role of interleukin-1, tumor necrosis factor α , and interleukin-6 in cartilage proteoglycan metabolism and destruction. Effect of in situ blocking in murine antigen- and zymosan-induced arthritis. *Arthritis Rheum.* **38**:164-172.
55. Van Meurs, J.B.J., et al. 1998. Interleukin-1 receptor antagonist prevents expression of the metalloproteinase-generated neopeptide VDIPEN in antigen-induced arthritis. *Arthritis Rheum.* **41**:647-656.
56. Ghivizzani, S.C., et al. 1998. Direct adenovirus-mediated gene trans-

- fer of interleukin 1 and tumor necrosis factor alpha soluble receptors to rabbit knees with experimental arthritis has local and distal antiarthritic effects. *Proc. Natl. Acad. Sci. USA.* **95**:4613–4618.
57. Guerne, P.A., Zuraw, B.L., Vaughan, J.H., Carson, D.A., and Lotz, M. 1989. Synovium as a source of interleukin-6 in vitro: contribution to local and systemic manifestations of arthritis. *J. Clin. Invest.* **83**:585–592.
58. Miossec, P., et al. 1992. Inhibition of the production of proinflammatory cytokines and immunoglobulins by interleukin-4 in an ex vivo model of rheumatoid synovitis. *Arthritis Rheum.* **35**:874–883.
59. Jilka, R.L., et al. 1992. Increased osteoclast development after estrogen loss: mediation by interleukin-6. *Science.* **257**:88–91.
60. Takayanagi, H., et al. 1997. A new mechanism of bone destruction in rheumatoid arthritis: synovial fibroblast induce osteoclastogenesis. *Biochem. Biophys. Res. Commun.* **240**:279–286.
61. Pesanti, E.L., and Lorenzo, J.A. 1998. Osteoclasts and effects of interleukin-4 in development of chronic osteomyelitis. *Clin. Orthop.* **355**:290–299.
62. Tezuka, K., et al. 1994. Molecular cloning of a possible cysteine proteinase predominantly expressed in osteoclasts. *J. Biol. Chem.* **269**:1106–1109.
63. Drake, F.H., et al. 1996. Cathepsin K, but not cathepsin B, L, or S, is abundantly expressed in human osteoclasts. *J. Biol. Chem.* **271**:12511–12516.
64. Osada, K., et al. 1994. Etretinate administration reduces serum propeptide of type I procollagen level in patients with psoriasis. *Br. J. Dermatol.* **131**:655–659.
65. Hakala, M., Risteli, L., Manelius, J., Nieminen, P., and Risteli, J. 1993. Increased type I collagen degradation correlates with disease severity in rheumatoid arthritis. *Ann. Rheum. Dis.* **52**:866–869.
66. Kotaniemi, A., Isomaki, H., Hakala, M., Risteli, L., and Risteli, J. 1994. Increased type I collagen degradation in early rheumatoid arthritis. *J. Rheumatol.* **21**:1593–1596.
67. Garnero, P., Jouvence, P., Buchs, N., Delmas, P.D., and Miossec, P. 1999. Uncoupling of bone metabolism in rheumatoid arthritis patients with or without joint destruction: assessment with serum type I collagen breakdown products. *Bone.* **24**:381–385.
68. Van den Berg, W.B. 1998. Joint inflammation and cartilage destruction may occur uncoupled. *Springer Semin. Immunopathol.* **20**:149–164.
69. Bresnihan, B., et al. 1998. Treatment of rheumatoid arthritis with recombinant human interleukin-1 receptor antagonist. *Arthritis Rheum.* **41**:2196–2204.