

# Transient expression of IL-1 $\beta$ induces acute lung injury and chronic repair leading to pulmonary fibrosis

See related Commentary on pages 1501–1502.

Martin Kolb,<sup>1,2</sup> Peter J. Margetts,<sup>1</sup> Daniel C. Anthony,<sup>3</sup> Fernando Pitossi,<sup>4</sup> and Jack Gauldie<sup>1</sup>

<sup>1</sup>Department of Pathology and Molecular Medicine and Centre for Gene Therapeutics, McMaster University, Hamilton, Ontario, Canada

<sup>2</sup>Medizinische Klinik, Julius-Maximilians-Universität Würzburg, Germany

<sup>3</sup>CNS Inflammation Group, University of Southampton, United Kingdom

<sup>4</sup>Gene Therapy Laboratory, Institute for Biochemical Research, Campomar Foundation, Buenos Aires, Argentina

Address correspondence to: Jack Gauldie, Department of Pathology and Molecular Medicine and Centre for Gene Therapeutics, McMaster University, 1200 Main Street West, Hamilton, Ontario, Canada L8N 3Z5.

Phone: (905) 521-2100 ext. 76332; Fax: (905) 577-0198; E-mail: gauldie@mcmaster.ca.

Received for publication February 20, 2001, and accepted in revised form May 8, 2001.

IL-1 $\beta$  is one of a family of proinflammatory cytokines thought to be involved in many acute and chronic diseases. Although it is considered to participate in wound repair, no major role has been attributed to IL-1 $\beta$  in tissue fibrosis. We used adenoviral gene transfer to transiently overexpress IL-1 $\beta$  in rat lungs after intratracheal administration. The high expression of IL-1 $\beta$  in the first week after injection was accompanied by local increase of the proinflammatory cytokines IL-6 and TNF- $\alpha$  and a vigorous acute inflammatory tissue response with evidence of tissue injury. The profibrotic cytokines PDGF and TGF- $\beta$ 1 were increased in lung fluid samples 1 week after peak expression of IL-1 $\beta$ . Although PDGF returned to baseline in the third week, TGF- $\beta$ 1 showed increased concentrations in bronchoalveolar lavage fluid for up to 60 days. This was associated with severe progressive tissue fibrosis in the lung, as shown by the presence of myofibroblasts, fibroblast foci, and significant extracellular accumulations of collagen and fibronectin. These data directly demonstrate how acute tissue injury in the lung, initiated by a highly proinflammatory cytokine, IL-1 $\beta$ , converts to progressive fibrotic changes. IL-1 $\beta$  should be considered a valid target for therapeutic intervention in diseases associated with fibrosis and tissue remodeling.

*J. Clin. Invest.* 107:1529–1536 (2001).

## Introduction

IL-1 is an important cytokine involved in acute and chronic inflammation in a complex network of signaling molecules. The three known constituents of the IL-1 gene family are IL-1 $\alpha$ , IL-1 $\beta$  and IL-1 receptor antagonist (IL-1RA), which all bind to the IL-1 receptor with similar affinity (1). Although IL-1 $\alpha$  remains in the cytosol or is expressed at cell membranes, IL-1 $\beta$  is released after proteolytic cleavage and is therefore more prominent in propagation of the inflammatory process. IL-1RA is present in both intracellular and secreted forms (2). All three IL-1 constituents show complex regulation on the transcriptional, translational, and post-translational level, an important facet that has to be considered in interpretation of studies demonstrating altered signal or protein expression in animal or human diseases (3).

IL-1 is involved in various disorders of the lung. Most investigations focus on proinflammatory effects of IL-1; however, there is increasing evidence that IL-1 also elicits potent profibrotic responses. A number of human and animal studies have revealed the presence of IL-1 $\beta$  in chronic inflamed tissues and in tissues undergoing fibrogenesis, with accumulation of myofibroblasts and matrix deposition (1, 4–7). Inhibition of

IL-1 $\beta$  at the initiation of animal models of fibrosis caused attenuation of the disease (8), suggesting a causative link between cytokines involved in the acute phase of inflammation, such as IL-1, and the conversion to chronic inflammation and fibrosis.

Although the role of IL-1 in tissue repair and fibrosis is uncertain, the importance of TGF- $\beta$ 1 in these processes is well recognized (9, 10). TGF- $\beta$ 1 is one of the key cytokines in scar formation and acts at different levels to increase lung collagen deposition. It is chemotactic for fibroblasts and promotes their transformation to myofibroblasts, induces the synthesis of matrix proteins and glycoproteins, and inhibits collagen degradation. We have previously shown, in a gene-transfer model similar to that described here, that transient overexpression of active TGF- $\beta$ 1 causes severe progressive fibrotic reactions in the lung (11). Other, moderately profibrotic cytokines such as GM-CSF and TNF- $\alpha$  mediate fibrotic responses likely through TGF- $\beta$  (12–14).

We have used a recombinant replication-deficient adenovirus vector to transfer and overexpress the gene for human IL-1 $\beta$  for a transient but prolonged period (7–10 days) in rodent lung. This extended expression of IL-1 $\beta$  elicits acute alveolar and parenchymal damage with sub-

sequent induction of TGF- $\beta$  expression and progressive interstitial fibrogenesis over the period of the next 60 days to termination. Matrix deposition and accumulation of myofibroblasts appear similar to those seen in human pulmonary fibrosis. These data complement our previous results with active TGF- $\beta$  in the lung (11) and contrast with the acute inflammation but minimal tissue damage and lack of chronic changes seen with lung gene transfer of TNF- $\alpha$  (12), the other suspected acute inflammatory cytokine. These data indicate that IL-1 $\beta$  plays an immediate and direct role in the induction of acute and chronic inflammation and should be considered a valid target for therapeutic intervention in diseases associated with fibrosis and tissue remodeling, such as idiopathic pulmonary fibrosis, asthma, liver cirrhosis, and renal fibrosis.

## Methods

**Recombinant adenovirus.** The construction of adenoviral vectors is described in detail elsewhere (15). For construction of AdhIL-1 $\beta$ , human IL-1 $\beta$  cDNA (in pGEM3Z vector, a gift from British Biotech Pharmaceuticals Ltd., Oxford, United Kingdom) was cloned into a shuttle vector with a human cytomegalovirus promoter and cotransfected on 293 cells with a plasmid containing E1- to E3-deleted type 5 adenoviral genome. The resulting replication-deficient virus was amplified and purified by CsCl gradient centrifugation and PD-10 Sephadex chromatography, and finally plaque titered on 293 cells. The vector was checked for integrity of viral DNA (by restriction digest and Southern blot) and expression of the desired protein (by Western blot). Control vectors (AdDL70) with no insert in the E1 region were produced in the same way.

**Animal treatment.** Female Sprague-Dawley rats (Charles River Laboratories, Montreal, Quebec, Canada), weighing 200–250 g, were housed under special pathogen-free conditions. Rodent laboratory food and water was provided ad libitum. The animals were treated in accordance to the guidelines of the Canadian Council of Animal Care. All animal procedures were performed with inhalation anesthesia with isoflurane (MTC Pharmaceuticals, Cambridge, Ontario, Canada). A total of  $5 \times 10^8$  plaque-forming units (pfu) of AdhIL-1 $\beta$  or AdDL70 was administered intratracheally in a volume of 300  $\mu$ l PBS after minor surgical preparation. One group of animals received PBS only ( $n = 4$ ). AdhIL-1 $\beta$ -treated rats were sacrificed by abdominal aortic bleeding at days 2 ( $n = 3$ ), 7 ( $n = 4$ ), 14 ( $n = 3$ ), 21 ( $n = 4$ ), 42 ( $n = 3$ ), and 60 ( $n = 3$ ). AdDL70-treated control animals were sacrificed at days 2 ( $n = 2$ ), 7 ( $n = 3$ ), 14 ( $n = 2$ ), and 21 ( $n = 3$ ).

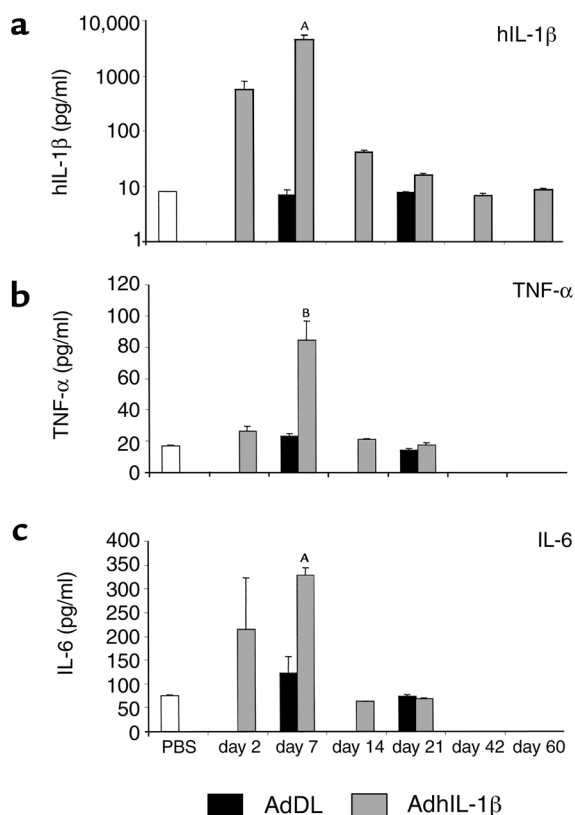
Bronchoalveolar lavage (BAL) was performed as described previously (11). BAL fluid was processed for cell counts and stored until determination of cytokine concentration. The right main bronchus was tied; the lung was removed, rinsed in PBS again, and frozen immediately in liquid nitrogen. Tissue samples were stored at  $-70^\circ\text{C}$  until further processing. The left lung was inflated with and fixed in 10% formalin for histological examination.

**Determination of cytokine levels in BAL fluid.** Human IL-1 $\beta$  (Amersham Pharmacia Biotech, Piscataway, New Jersey, USA) and rat IL-1 $\beta$ , rat TNF- $\alpha$ , rat IL-6, human PDGF-AB, and human TGF- $\beta$ 1 (all R&D Systems, Minneapolis, Minnesota, USA) were measured using ELISA according to manufacturers' recommendations. TGF- $\beta$ 1 measured by ELISA was latent plus active TGF- $\beta$  after acid activation. The cross reactivity between human and rat IL-1 $\beta$  in the assays used was less than 2%. The PDGF and TGF- $\beta$  ELISA used detects PDGF and TGF- $\beta$  across species.

**TGF- $\beta$  bioassay.** Bioactive TGF- $\beta$  was detected with an established bioassay using mink lung epithelial cells (MLECs) with a stable transfection of the human plasminogen-activator-inhibitor-1 gene fused to the firefly luciferase reporter gene (16). Standards for TGF- $\beta$ 1 were generated adding recombinant human TGF- $\beta$  to the medium of MLECs (10–500 pg/ml; R&D Systems). Luciferase activity was measured with (D)-luciferin (Luciferase Assay System; Promega Corp., Madison, Wisconsin, USA) and multiplate luminometer (Tropix TR717; Applied Biosystems, Foster City, California, USA). Data are presented in relative light units (RLUs).

**Serum cysteine protease inhibitor.** Rat serum was analyzed for the acute-phase protein, rat  $\alpha_1$ -cysteine protease inhibitor, by immunoelectrophoresis as described previously (17). Rat serum samples were electrophoresed for 16 hours through a 1% agarose gel containing rabbit anti-rat  $\alpha_1$ -cysteine protease inhibitor serum in barbital buffer (pH 8.6). The gel was transferred to Gel Bond film (FMC Bioproducts, Rockland, Maine, USA) and stained with Coomassie brilliant blue. Amounts of  $\alpha_1$ -cysteine protease inhibitor were extrapolated using rat serum standard curves and expressed as milligrams per milliliter.

**Histology and immunohistochemistry.** After fixation in 10% buffered formalin for 24 hours, longitudinal sections of the lung were paraffin embedded, sectioned, and stained with hematoxylin and eosin and Masson-trichrome. Immunohistochemistry was performed to stain cells and structures positive for  $\alpha$ -smooth muscle actin ( $\alpha$ -SMA) and fibronectin. Sections (3  $\mu$ m) were cut on aptex-coated slides and were deparaffinized in xylene followed by 100% ethanol and then placed in a freshly prepared methanol H<sub>2</sub>O<sub>2</sub> solution for 30 minutes to block endogenous peroxidase activity. After hydration to water with graded alcohol, the sections were placed in 0.05M Tris buffer saline (TBS; pH 7.6). Immunohistochemistry was carried out with antibodies against  $\alpha$ -SMA and fibronectin (DAKO Corp., Carpinteria, California, USA). For  $\alpha$ -SMA immunohistochemistry, sections were blocked with 1% normal swine serum (NSS) in TBS for 20 minutes followed by incubation in 1:100 mouse anti-human  $\alpha$ -SMA in 1% NSS overnight. Sections were then incubated with a 1:300 biotinylated rabbit anti-mouse (DAKO Corp.) for 1 hour followed by 45 minutes of incubation with a 1:600 streptavidin/peroxidase conjugate (DAKO Corp.). Negative control sections were run in parallel with nonimmune mouse or rabbit



**Figure 1** Proinflammatory cytokines in BAL fluid. (a) Transgene human IL-1 $\beta$  was elevated 2 days after injection of AdhIL-1 $\beta$ , was maximally expressed after 7 days, and returned to baseline by day 14. Endogenous TNF- $\alpha$  (b) and IL-6 (c) were upregulated parallel to hIL-1 $\beta$  and returned to baseline concentration by day 14. In control animals treated with AdDL70, hIL-1 $\beta$ , TNF- $\alpha$ , and IL-6 were not different from PBS-treated rats. <sup>A</sup> $P < 0.008$  versus AdDL70 control; <sup>B</sup> $P < 0.02$  versus AdDL70 control.

immunoglobulin diluted to the same concentration as the primary antibodies. For fibronectin immunohistochemistry, sections were digested with 0.4% pepsin in 0.5N HCl before incubation with 1:2,000 fibronectin in 1% normal goat serum overnight. Sections were then incubated with a 1:300 biotinylated goat anti-rabbit (DAKO Corp.) for 1 hour followed by 45 minutes of incubation with a 1:600 streptavidin/peroxidase conjugate (DAKO Corp.). All sections were rinsed in 0.05 M acetate buffer (pH 5.0) before development in an AEC chromogen substrate for 15 minutes. All sections were counterstained in Mayer's hematoxylin for 2 minutes before mounting with glycerine gelatin.

**Hydroxyproline assay.** Frozen lung samples were homogenized in deionized water, and hydroxyproline content was determined by a colorimetric assay described previously (18). Data are calculated as micrograms of hydroxyproline per milligrams of lung tissue.

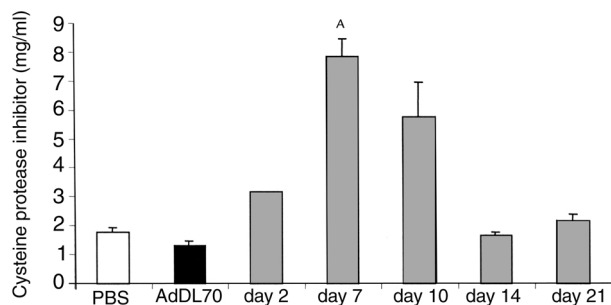
**Statistical analysis.** Data are shown as mean  $\pm$  SEM. For evaluation of group differences, we used the Student's *t* test. A *P* value less than 0.05 was considered significant.

## Results

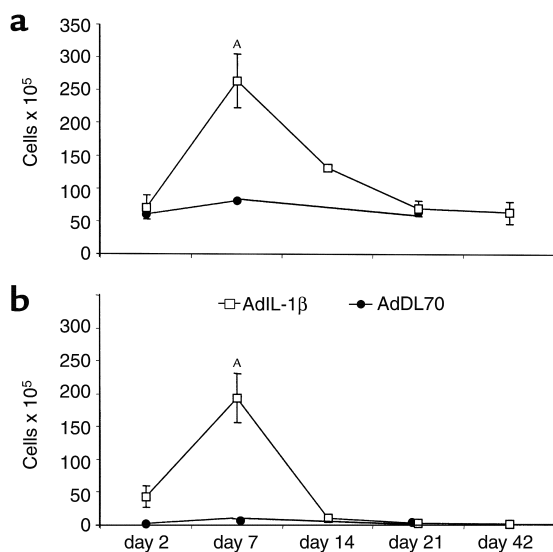
**Expression of transgene protein and proinflammatory cytokines in BAL fluid (IL-1 $\beta$ , TNF- $\alpha$ , and IL-6).** We used an ELISA specific for human IL-1 $\beta$  to detect and quantify transgene human IL-1 $\beta$  in BAL fluid of infected rats. Transgene hIL-1 $\beta$  was present in AdhIL-1 $\beta$ -treated animals as early as 2 days after infection and peaked by day 7 (4,733  $\pm$  913 vs. 7.1  $\pm$  1.4 pg/ml in AdDL70 control;  $P < 0.008$ ). The level of IL-1 $\beta$  in control animals was at the detection limit of the ELISA. By day 14, hIL-1 $\beta$  levels were markedly declined, but still significantly elevated compared with control. After 3 weeks, transgene cytokine was barely detectable, with concentrations similar to control animals treated with PBS or control virus AdDL70 (Figure 1a). Rat serum levels of hIL-1 $\beta$  were higher by day 7 in AdhIL-1 $\beta$ -treated animals compared with controls (826.8  $\pm$  118.5 vs. 162.4  $\pm$  60.5 pg/ml in AdDL70;  $P < 0.02$ ). To determine whether the background value of 160 pg/ml detected in rat serum was due to rat IL-1 $\beta$ , samples were assayed for rat IL-1 $\beta$  by rat-specific ELISA. In BAL fluid, endogenous (rat) IL-1 $\beta$  appeared to be increased at 7 days (957.8  $\pm$  425 vs. 84  $\pm$  14 pg/ml in AdDL70) and was otherwise found at baseline (<80 pg/ml) at all other times, but the day 7 change did not reach statistical significance. When the rat IL-1 $\beta$  assay was applied to serum, no differences were seen in levels of rat IL-1 $\beta$  between AdhIL-1 $\beta$ - and AdDL70-treated animals.

The two other acute proinflammatory cytokines determined in this study, TNF- $\alpha$  and IL-6, followed the same time course as IL-1 $\beta$  with an earlier decline to normal. In AdhIL-1 $\beta$ -treated animals, TNF- $\alpha$  showed maximal expression by day 7 (84.5  $\pm$  12.4 vs. 23.5  $\pm$  1.5 pg/ml in AdDL70 control;  $P < 0.02$ ) and was returned to baseline level by day 14 (Figure 1b). IL-6 was also maximally present 7 days after infection with AdhIL-1 $\beta$  (329.2  $\pm$  15.5 vs. 121.5  $\pm$  35 pg/ml in AdDL70 control;  $P < 0.008$ ) and had returned to normal by day 14 (Figure 1c).

**Serum acute-phase response.** As an indication of circulating IL-1 and effects on the liver, serum concentrations of  $\alpha_1$ -cysteine protease inhibitor were determined



**Figure 2** Serum concentration of  $\alpha_1$ -cysteine protease inhibitor was maximally increased 7 days after injection of AdhIL-1 $\beta$  and returned to baseline by day 14. Injection of control virus AdDL70 did not cause elevated serum levels of  $\alpha_1$ -cysteine protease inhibitor. <sup>A</sup> $P < 0.002$  versus AdDL70 control.



**Figure 3**  
 (a) Total cells retrieved by BAL were increased 7 and 14 days after injection of AdhIL-1 $\beta$ . The vast majority of cells at day 7 were neutrophils (b), whereas alveolar macrophages accounted for the persistent increase of total cells at day 14. Cell counts and differentials were normal by day 21. Seven days after injection, animals treated with control virus AdDL70 had a slight, insignificant increase in total cell number. Neutrophils were not elevated. <sup>A</sup>*P* < 0.01 versus AdDL70 control.

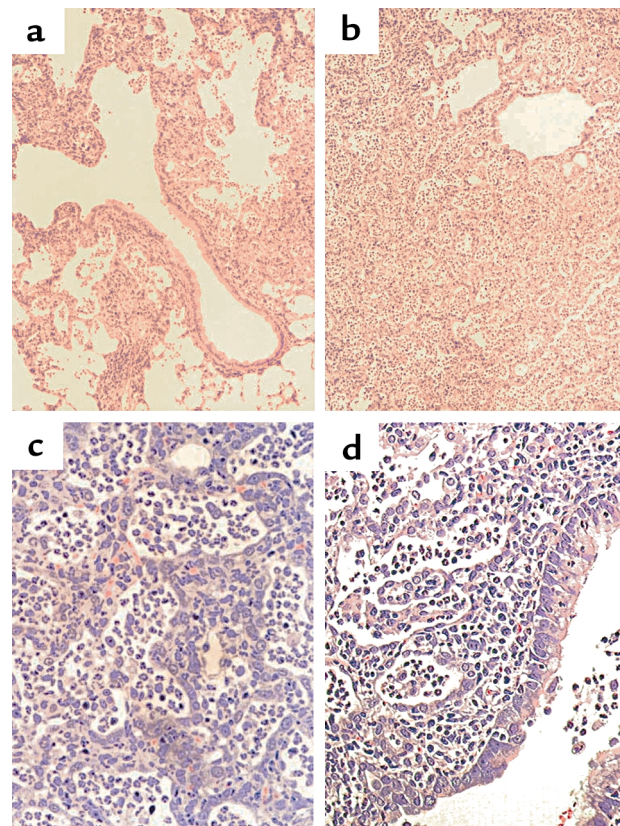
to quantify the systemic acute-phase response. Rats treated with AdhIL-1 $\beta$  had increased levels of cysteine protease inhibitor 2 days after injection, peaking by day 7 ( $7.85 \pm 0.59$  vs.  $1.32 \pm 0.15$  mg/ml in AdDL70 control; *P* < 0.002), and returning to baseline by day 14 (Figure 2), mirroring changes to both IL-1 and IL-6 levels.

**Acute effects of AdhIL-1 $\beta$  on the inflammatory response in the lung.** Intratracheal injection of AdhIL-1 $\beta$  resulted in a dramatic acute inflammatory response in the lung. The total amount of cells recovered in BAL fluid significantly increased by day 7 in AdhIL-1 $\beta$ -treated animals compared with control rats (Figure 3a). The vast majority of inflammatory cells were neutrophils, which accounted for almost 80% of cells in differential counts (Figure 3b). Alveolar macrophages had morphological signs of activation, such as enlargement and increase of intracellular vacuoles, and were predominant by day 14, when neutrophil counts were back to baseline. Other cell types were not markedly increased in BAL fluid at any time point. Control vector-treated animals showed normal cellularity in BAL at these times. In the parenchyma, inflammatory infiltrates were present as early as 2 days after injection, predominantly in peribronchial areas, and were most prominent by day 7 with patchy distribution throughout the lungs (Figure 4, a and b). Infiltrates were composed mainly of neutrophils and macrophages (Figure 4, c and d). Some parts of the inflamed sites showed marked tissue destruction and disruption of alveolar architecture. The acute inflammatory response resolved after 2 weeks.

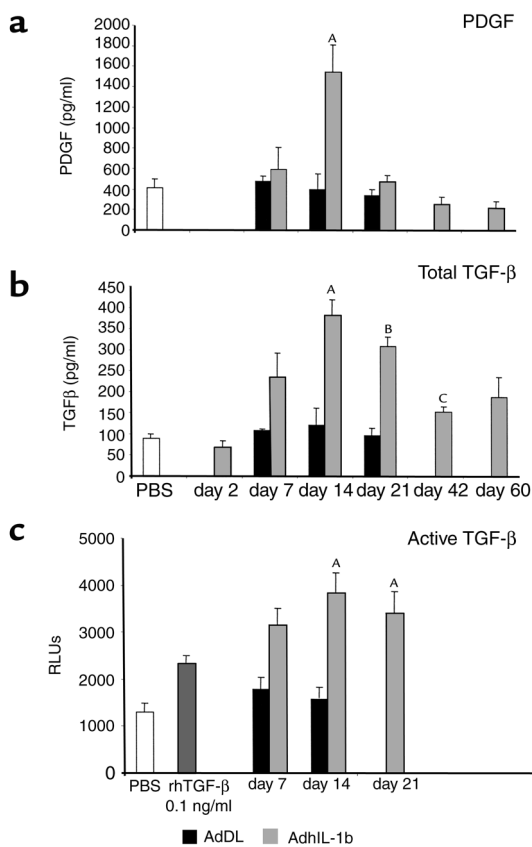
**Expression of profibrotic cytokines in BAL fluid (PDGF and total/active TGF- $\beta$ ).** PDGF and total TGF- $\beta$  in BAL fluid

were measured by ELISA. PDGF in BAL fluid was significantly increased only at day 14 after injection of AdhIL-1 $\beta$  ( $397.2 \pm 150$  vs.  $1,546 \pm 265$  pg/ml in AdDL70 control; *P* < 0.04; Figure 5a). In contrast, TGF- $\beta$  was elevated by day 7 and was maximal 14 days after injection of AdhIL-1 $\beta$  ( $380.9 \pm 38.1$  vs.  $120.9 \pm 39.6$  pg/ml in AdDL70 control; *P* < 0.02; Figure 5b) at a time when IL-1 and other cytokines had returned to baseline. TGF- $\beta$  levels returned to lower values by day 42, but were still significantly increased compared with PBS-treated animals (*P* < 0.04). Active TGF- $\beta$  in BAL fluid was determined using a bioassay that measures luciferase activity induced by TGF- $\beta$  through PAI-I promoter in a transformed cell line. BAL fluid contained significant amounts of active TGF- $\beta$  at 7 and 14 days after injection of AdhIL-1 $\beta$ , equivalent to approximately 100 pg/ml of recombinant human TGF- $\beta$  (*P* < 0.04 versus AdDL70 control; Figure 5c).

**Chronic effects of AdhIL-1 $\beta$  and induction of fibrotic responses in the lung.** Transient overexpression of IL-1 $\beta$  induced marked tissue injury and repair in the lung, leading to



**Figure 4**  
 Lung histology in the first week after injection of AdhIL-1 $\beta$  showed acute inflammatory reactions in the lungs, beginning in peribronchial areas after 2 days (a). By day 7, inflammatory infiltrates affected large parts of the lung (b). In some areas, the cellular infiltrates completely filled alveoli while alveolar structures remained intact. In other regions, they caused marked alveolar wall destruction (c). The inflammatory infiltrates consisted mainly of neutrophils and macrophages, reaching the airway lumen after passing bronchial mucosa (d). Hematoxylin and eosin staining;  $\times 24$  (a and b);  $\times 160$  (c and d).



**Figure 5** Profibrotic cytokines in BAL fluid. (a) PDGF was increased 2 weeks after injection of AdhIL-1 $\beta$ , 1 week after peak expression of proinflammatory cytokines, and returned to normal values by day 21. (b) TGF- $\beta$  also showed maximal expression after 2 weeks. By day 21, in contrast to PDGF, concentration of TGF- $\beta$  in BAL fluid was slightly reduced compared with day 14. Increased TGF- $\beta$  concentration was measured for the entire course of the experiment up to day 60. (c) The presence of bioactive TGF- $\beta$  in BAL fluids of AdhIL-1 $\beta$ -treated animals was demonstrated using an established bioassay (MLECs with luciferase reporter gene, controlled by TGF- $\beta$ -inducible promoter PAI-1; for details see the text). <sup>A</sup> $P < 0.04$  versus AdDL70 control. <sup>B</sup> $P < 0.02$  versus AdDL70 control. <sup>C</sup> $P < 0.04$  versus PBS.

severe and progressive pulmonary fibrosis. Histologically, an increase of pulmonary myofibroblasts and deposition of collagen in the interstitium was observed as early as 14 days after intratracheal injection of AdhIL-1 $\beta$ . Myofibroblasts were distributed throughout the tissue in the interstitium and along alveolar walls, frequently gathing and forming accumulations with similarities to fibroblast foci seen in usual interstitial pneumonia in humans (Figure 6). Immunohistochemistry and collagen staining were used to demonstrate that these cells were myofibroblasts ( $\alpha$ -SMA; Figure 6b) and major producers of collagen (Figure 6c) and other matrix components such as fibronectin (Figure 6d). By day 21, lungs showed extensive fibrotic areas and significant quantities of myofibroblasts and extracellular matrix (Figure 6, e–g). The histological appearance of interstitial fibrosis was unchanged at the latest observation point of the

study, assessed 60 days after initiation of tissue injury. At that time, the quantity of myofibroblasts was markedly reduced and few fibroblast foci were apparent.

Hydroxyproline content of lung homogenates was determined to quantify the amount of collagen in the tissue. The concentration of lung hydroxyproline was elevated beginning 14 days after injection of AdhIL-1 $\beta$ , confirming the histological observations, and was steadily increased over the course of the experiment (day 60:  $5.03 \pm 0.08$  vs.  $1.79 \pm 0.17$   $\mu$ g/mg lung tissue in control animals;  $P < 0.00001$ ; Figure 7).

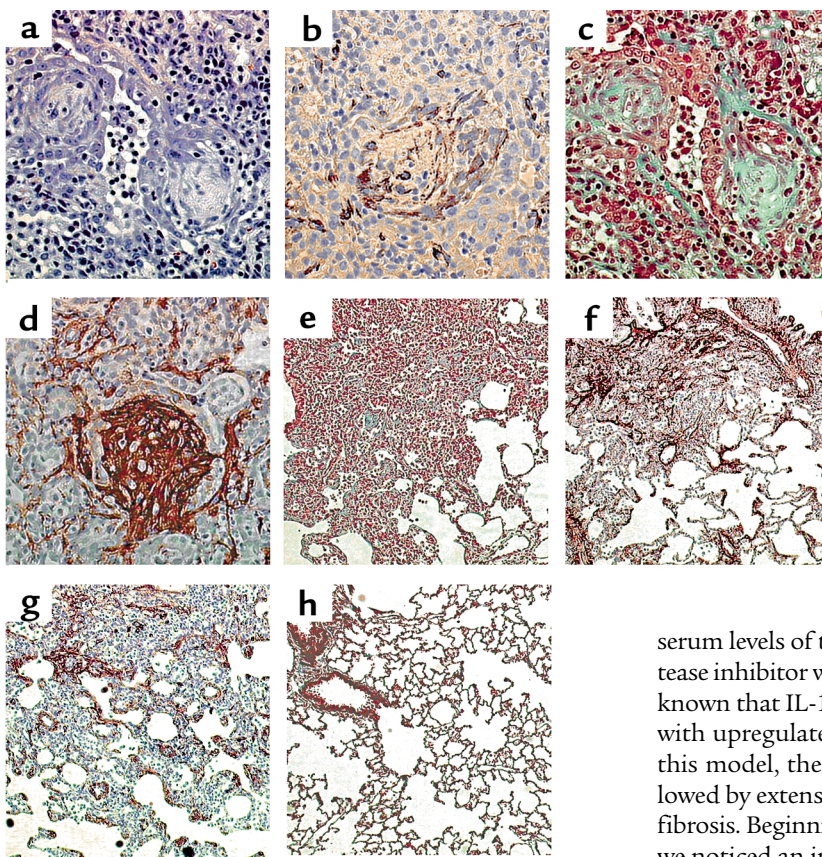
*Effects of pulmonary overexpression of hIL-1 $\beta$  on other organs.* The liver showed a transient increase of intracellular fat vacuoles by day 7, the time of maximal expression of proinflammatory cytokines in BAL fluid and acute-phase protein in serum. These changes disappeared completely by day 42 without generation of liver fibrosis. No obvious morphological changes were observed in spleen, kidneys, or heart.

## Discussion

We show in this study that transient overexpression of IL-1 $\beta$  in the epithelial cells of rodent lung using adenoviral gene transfer induces acute inflammation with alveolar tissue destruction resulting in progressive interstitial fibrosis. Moreover, we demonstrate that this long-term effect is coincident with sustained induction of the profibrotic cytokine TGF- $\beta$ . To our knowledge, is the first experimental model directly showing how acute tissue injury in the lung, initiated by a highly proinflammatory cytokine, IL-1 $\beta$ , converts to progressive fibrotic changes.

The IL-1 gene family is a group of cytokines involved in a variety of acute and chronic lung diseases. The three constituents are IL-1 $\alpha$ , IL-1 $\beta$ , and IL-1RA. IL-1 $\beta$  is one of the major extracellular proinflammatory cytokines, acting often synergistically with TNF- $\alpha$  (1, 2). Several studies have described the important role of IL-1 in acute lung injury. Short-time exposure to IL-1 by injection of recombinant IL-1 into rodent tracheas leads to development of acute alveolar leakage and neutrophil inflammation (19, 20). These experimental findings are supported by data from human studies. In patients with adult respiratory distress syndrome (ARDS), IL-1 is elevated in BAL fluid and alveolar macrophages (21–23). Although ARDS is a disorder that leads to complete restoration of lung function in a majority of cases, there is a substantial risk that progressive fibrosis develops (22, 24). IL-1 $\beta$  was shown to be expressed in fibroproliferative areas in idiopathic pulmonary fibrosis (6) and to be present in BAL fluid of infants with chronic lung disease of prematurity (25). Recent studies have demonstrated a potential role for IL-1RA in pulmonary fibrosis. One study showed a higher risk for fibrosing alveolitis in patients with IL-1RA polymorphism and suggested a pathophysiological role for unopposed IL-1 in this condition (26). Another study reported that patients with chronic sarcoidosis have higher IL-1RA/IL-1 $\beta$  ratios in BAL fluid compared with patients with radiographic





**Figure 6**  
Fibrogenic responses in the lung after intratracheal injection of AdhIL-1 $\beta$ . (a) Numerous fibroblast foci were observed in the lung tissue 14 days after injection. Special staining methods demonstrated that cells in these foci were myofibroblasts (b,  $\alpha$ -SMA immunohistochemistry), and synthesized collagen (c, Masson trichrome) and fibronectin (d, immunohistochemistry). Major collagen and fibronectin accumulation was noticed 3 weeks after injection of AdhIL-1 $\beta$  (e and f, Masson trichrome and fibronectin immunohistochemistry), and myofibroblasts were present in interstitial areas and along alveolar walls (g,  $\alpha$ -SMA immunohistochemistry). The histological appearance of animals treated with control virus AdDL70 was normal (h, Masson trichrome).  $\times 160$  (a-d);  $\times 50$  (e-h).

improvement, implying a predictive value for the course of sarcoidosis (27, 28). In animal models in which acute injury results in pulmonary fibrosis, e.g., using bleomycin, silica, or irradiation, the presence of IL-1 was demonstrated by mRNA analysis and immunohistochemistry (4, 5, 7). One study suggested a major role of IL-1 in the generation of fibrosis by showing beneficial effect of IL-1RA on the course of bleomycin induced lung fibrosis (8).

In our study, animals were exposed to IL-1 $\beta$  in the lung over a period of 7–10 days using adenoviral gene transfer and responded with a vigorous acute inflammatory reaction in the lungs. Predominant inflammatory cell types involved in this process were neutrophil granulocytes and macrophages, as was expected from previous studies. In some pulmonary areas, inflammation was accompanied by tissue destruction and disruption of alveolar architecture. IL-1 is a known stimulus for the induction of other proinflammatory cytokines, and we found significantly increased concentrations of IL-6 and TNF- $\alpha$  in BAL fluid, likely acting in concert with IL-1 to perpetuate inflammation and subsequent events. We also showed that overexpression of transgene human IL-1 $\beta$  appeared to induce endogenous (rat) IL-1 $\beta$  in the lung at 7 days, but otherwise there was no evidence of major involvement of endogenous IL-1 $\beta$  in the response. The animals were sick between days 4 and 8 after injection of AdhIL-1 $\beta$ , showing symptoms of respiratory distress and systemic involvement, such as fever and weight loss. Accordingly,

serum levels of the acute-phase protein  $\alpha_1$ -cysteine-protease inhibitor were elevated during this period. It is well known that IL-1 induces a hepatic acute-phase reaction with upregulated acute-phase protein (2). However, in this model, the acute inflammatory response was followed by extensive wound repair and progressive tissue fibrosis. Beginning 2 weeks after initiation of the injury, we noticed an increase of pulmonary collagen, both by morphological analysis and by lung hydroxyproline concentrations. Lung collagen concentration steadily increased during the course of the experiment, with the highest level seen after 60 days. Myofibroblast-like cells were observed in the tissue coincident with the first signs of interstitial fibrosis. By day 14, numerous accumulations of myofibroblasts were present, mainly in areas of developing scars. Morphologically, the accumulations had compelling similarities to fibroblast foci, a histological feature characteristic for usual interstitial pneumonia (see Figure 6). In usual interstitial pneumonia, fibroblast foci are areas where extracellular matrix is synthesized and believed to be sites of ongoing tissue injury (29). The fibroblast foci we observed in rat lung after overexpression of IL-1 $\beta$  showed marked presence of collagen and fibronectin, supporting the hypothesis concerning the role of fibroblast foci in humans.

Although IL-1 has always been considered to participate in tissue injury and repair, it has not been attributed a major role in chronic disease to date. One likely reason for this is controversial data about *in vitro* effects of IL-1. IL-1 was shown to stimulate collagen production in skin fibroblasts (30), but conversely appears to reduce ECM synthesis in lung fibroblasts (31). The effect on fibroblast proliferation is also controversial (32). The interference of IL-1 with prostaglandin synthesis may affect its *in vitro* properties, because of strong anti-mitogenic and antifibrotic influences of prostaglandins (33). Although the direct effect of IL-1 on fibroblasts still has to be determined, it is known that IL-1 is able to induce cytokines and growth factors *in vitro* and *in vivo* (22).

Among those, PDGF and TGF- $\beta$  are two key profibrotic growth factors (10). In the present study, we measured both PDGF and TGF- $\beta$  in BAL fluid after administration of AdhIL-1 $\beta$  and found significantly elevated levels peaking by day 14, 1 week after the maximal expression of transgene IL-1 $\beta$ . Whereas PDGF returned to baseline after 21 days, we found sustained expression of TGF- $\beta$  in BAL fluid, which was still increased 60 days after injection of AdhIL-1 $\beta$  and relates to the progressive fibrosis.

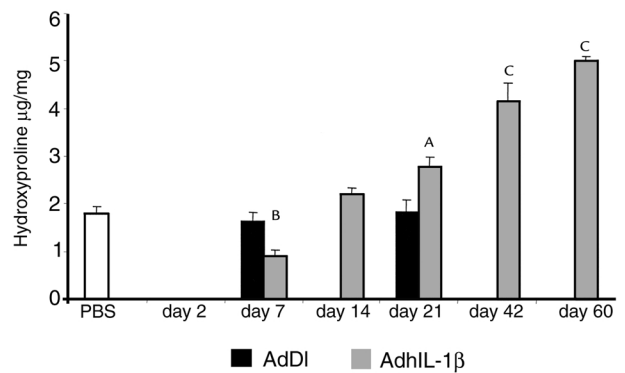
This observation complements our earlier findings about transient overexpression of potentially profibrotic cytokines in the rodent lung. Among those, GM-CSF, TNF- $\alpha$ , and TGF- $\beta$  appear to play an important role in the fibrotic tissue response (11–14). The main differences between gene transfer models using these cytokines and IL-1 $\beta$  on tissue inflammation and remodeling in the lung are summarized in Table 1. The extent and cellular composition of the acute inflammatory response of AdhIL-1 $\beta$  was similar to AdTNF- $\alpha$ . However, in the AdTNF- $\alpha$  model we did not see the extensive early alveolar destruction as in the AdhIL-1 $\beta$  model, and the fibrotic response in the chronic stage was marginal when compared with that of AdhIL-1 $\beta$ -treated animals. In contrast to AdTNF- $\alpha$  and AdhIL-1 $\beta$ , the experiments using active AdTGF- $\beta$ 1 showed virtually no acute inflammation and early tissue damage, but resulted in dramatic and progressive pulmonary remodeling and fibrosis. The delivery of AdGM-CSF resulted in acute inflammation, some early alveolar damage, and a marked fibrotic reaction, but the extent of these changes was significantly less than after the administration of AdhIL-1 $\beta$ . These observations show that IL-1 $\beta$  and TGF- $\beta$  have a major, and GM-CSF an intermediate, impact on chronic pulmonary fibrosis, whereas TNF- $\alpha$  is not as effective when transiently overexpressed by adenoviral gene transfer. The summarized data (Table 1) suggest that both the amount and duration of increased TGF- $\beta$  in the pulmonary environment are one of the reasons for excessive remodeling and fibrosis. In the AdTGF- $\beta$  model, TGF- $\beta$  was present at high levels (peak >50 ng/ml) for approximately 10 days, followed by pulmonary collagen accumulation 1 week after peak expression. After administration of AdGM-CSF, endogenous TGF- $\beta$  was increased for 11 week (maxi-

**Table 1**

Effect of the profibrotic cytokines IL-1 $\beta$ , TNF- $\alpha$ , GM-CSF, and TGF- $\beta$  on acute tissue injury and remodeling in the rodent lung after delivery by adenoviral gene transfer

	Inflammation	Alveolar destruction	TGF- $\beta$ in BALF	Fibrosis
AdIL-1 $\beta$	+++	++	400 pg/ml	+++
AdTNF $\alpha^A$	+++	+/-	150 pg/ml	+
AdGM-CSF <sup>B</sup>	++	+	600 pg/ml	++
AdTGF $\beta$ 1 <sup>C</sup>	-	-	>50 ng/ml	+++

<sup>A</sup>Ref. 12; <sup>B</sup>ref. 13; <sup>C</sup>ref. 11.



**Figure 7**

Animals treated with AdhIL-1 $\beta$  showed a progressive increase of lung hydroxyproline concentration past day 21 after injection. <sup>A</sup>*P* < 0.01 versus AdDL70 control. <sup>B</sup>*P* < 0.01, <sup>C</sup>*P* < 0.001 versus PBS control.

mal 600 pg/ml), resulting in marked but not excessive fibrosis, whereas AdTNF- $\alpha$  increased TGF- $\beta$  just twofold above control vector (150 pg/ml), with only minor evidence of fibrosis. The concentration of TGF- $\beta$  in BAL fluid after AdhIL-1 $\beta$  was similar to the AdGM-CSF model, but was delayed (peak expression of 400 pg/ml after 21 days) and appeared to increase through day 60. In addition to the ability to induce endogenous TGF- $\beta$ , the potential to cause early alveolar destruction appears to effect the profibrotic properties of individual cytokines.

It is also important to realize that transient overexpression of IL-1 $\beta$ , TGF- $\beta$ , GM-CSF, or TNF- $\alpha$  in the lung induced the development of chronic inflammation and fibrosis. This phenomenon was restricted to the lung, despite considerable systemic involvement during the acute phase of the models. In particular, IL-1 $\beta$  induced systemic effects previously associated with this cytokine including the hepatic acute-phase response, fever and cachexia. However, the fibrosis was restricted to the lung, the tissue site where TGF- $\beta$  was generated, suggesting that the process of fibrogenesis is tissue-specific and limited. This also suggests that therapeutic intervention would best target the local event and involve less the systemic effects of many cytokines that play both pathological as well as physiological roles.

The complex transcriptional, translational, and post-translational regulation of the IL-1 gene family offers opportunity for pharmacological intervention. The presence of a natural antagonist, IL-1RA, is a unique feature in cytokine biology and overexpression of IL-1RA could be beneficial in diseases associated with IL-1 (1–3). Earlier clinical trials with IL-1RA that focused on sepsis and ARDS have shown some promising, but yet unconfirmed, results (34, 35). To our knowledge, there is no systematic analysis of the clinical benefit of IL-1RA in fibroproliferative disease. Another target for drug development is the IL-1 receptor. Two receptors for IL-1 are known and bind to IL-1 $\alpha$ , IL-1 $\beta$ , and IL-1RA with similar affinity: type I receptor mediates the signal trans-

duction together with the receptor accessory protein, whereas type II receptor does not transfer a signal and acts as a sink for IL-1 (36). It was recently shown that human lung epithelial cells do not express sufficient type II receptor and thus lack the ability to downregulate IL-1 $\beta$  activity (37). Hence, overexpression of type II receptor in pulmonary epithelium, e.g., using gene transfer, could be a valuable treatment option in lung diseases associated with increased local concentrations of IL-1 $\beta$ .

These data indicate that IL-1 $\beta$  plays an immediate and direct role in pulmonary tissue injury and repair. They show that IL-1 $\beta$  is a potent inducer of TGF- $\beta$ , and suggest that at least a part of its profibrotic effects is mediated through this growth factor. IL-1 $\beta$  should be considered a valid target for therapeutic intervention in diseases associated with fibrosis and tissue remodeling, such as pulmonary fibrosis, chronic asthma, liver cirrhosis, and renal fibrosis.

### Acknowledgments

We thank Jane Ann Schroeder, Duncan Chong, and Xueya Feng for their outstanding technical help, Mary Jo Smith for preparation of histology, and Tom Galt for assistance in animal handling. The work was supported by CIHR Canada, Wellcome Trust, Hamilton Health Science Corporation and St. Joseph's Hospital Hamilton. M. Kolb is thankful for the continuing support of Michael Schmidt. P.J. Margetts is supported by Kidney Foundation Canada.

- Dinarello, C.A. 1997. Interleukin-1. *Cytokine Growth Factor Rev*. **8**:253–265.
- Tocci, M.J., and Schmidt, J.A. 1997. Interleukin-1: structure and function. In *Cytokines in health and disease*. D.G. Remick and J.S. Friedland, editors. Marcel Dekker. New York, New York, USA. 1–27.
- Watkins, L.R., Hansen, M.K., Nguyen, K.T., Lee, J.E., and Maier, S.F. 1999. Dynamic regulation of the proinflammatory cytokine, interleukin-1beta: molecular biology for non-molecular biologists. *Life Sci*. **65**:449–481.
- Phan, S.H., and Kunkel, S.L. 1992. Lung cytokine production in bleomycin-induced pulmonary fibrosis. *Exp. Lung Res*. **18**:29–43.
- Thrall, R.S., and Scalise, P.J. 1995. Bleomycin. In *Pulmonary fibrosis*. S.H. Phan, editor. Marcel Dekker. New York, New York, USA. 231–292.
- Pan, L.H., Ohtani, H., Yamauchi, K., and Nagura, H. 1996. Co-expression of TNF alpha and IL-1 beta in human acute pulmonary fibrotic diseases: an immunohistochemical analysis. *Pathol. Int*. **46**:91–99.
- Johnston, C.J., et al. 1996. Early and persistent alterations in the expression of interleukin-1 alpha, interleukin-1 beta and tumor necrosis factor alpha mRNA levels in fibrosis-resistant and sensitive mice after thoracic irradiation. *Radiat. Res*. **145**:762–767.
- Piguet, P.F., Vesin, C., Grau, G.E., and Thompson, R.C. 1993. Interleukin 1 receptor antagonist (IL-1ra) prevents or cures pulmonary fibrosis elicited in mice by bleomycin or silica. *Cytokine*. **5**:57–61.
- Gauldie, J., Sime, P.J., Xing, Z., Marr, B., and Tremblay, G.M. 1999. Transforming growth factor-beta gene transfer to the lung induces myofibroblast presence and pulmonary fibrosis. *Curr. Top. Pathol*. **93**:35–45.
- Lasky, J.A., and Brody, A.R. 2000. Interstitial fibrosis and growth factors. *Environ. Health Perspect*. **108**(Suppl. 4):751–762.
- Sime, P.J., Xing, Z., Graham, F.L., Csaky, K.G., and Gauldie, J. 1997. Adenovector-mediated gene transfer of active transforming growth factor-beta1 induces prolonged severe fibrosis in rat lung. *J. Clin. Invest*. **100**:768–776.
- Sime, P.J., et al. 1998. Transfer of tumor necrosis factor-alpha to rat lung induces severe pulmonary inflammation and patchy interstitial fibrogenesis with induction of transforming growth factor-beta1 and myofibroblasts. *Am. J. Pathol*. **153**:825–832.
- Xing, Z., Tremblay, G.M., Sime, P.J., and Gauldie, J. 1997. Overexpression of granulocyte-macrophage colony-stimulating factor induces pulmonary granulation tissue formation and fibrosis by induction of transforming growth factor-beta 1 and myofibroblast accumulation. *Am. J. Pathol*. **150**:59–66.
- Xing, Z., Ohkawara, Y., Jordana, M., Graham, F., and Gauldie, J. 1996. Transfer of granulocyte-macrophage colony-stimulating factor gene to rat lung induces eosinophilia, monocytosis, and fibrotic reactions. *J. Clin. Invest*. **97**:1102–1110.
- Bett, A.J., Haddara, W., Prevec, L., and Graham, F.L. 1994. An efficient and flexible system for construction of adenovirus vectors with insertions or deletions in early regions 1 and 3. *Proc. Natl. Acad. Sci. USA*. **91**:8802–8806.
- Abe, M., et al. 1994. An assay for transforming growth factor-beta using cells transfected with a plasminogen activator inhibitor-1 promoter-luciferase construct. *Anal. Biochem*. **216**:276–284.
- Koj, A., Gauldie, J., Regoeci, E., Sauder, D.N., and Sweeney, G.D. 1984. The acute-phase response of cultured rat hepatocytes. System characterization and the effect of human cytokines. *Biochem. J*. **224**:505–514.
- Woessner, J.F., Jr. 1961. The determination of hydroxyproline in tissue and protein samples containing small proportions of this imino acid. *Arch. Biochem. Biophys*. **93**:440–447.
- Hybertson, B.M., Lee, Y.M., and Repine, J.E. 1997. Phagocytes and acute lung injury: dual roles for interleukin-1. *Ann. NY Acad. Sci*. **832**:266–273.
- Lee, Y.M., et al. 2000. Platelet-activating factor contributes to acute lung leak in rats given interleukin-1 intratracheally. *Am. J. Physiol. Lung Cell Mol. Physiol*. **279**:L75–L80.
- Pugin, J., Ricou, B., Steinberg, K.P., Suter, P.M., and Martin, T.R. 1996. Proinflammatory activity in bronchoalveolar lavage fluids from patients with ARDS, a prominent role for interleukin-1. *Am. J. Respir. Crit. Care Med*. **153**:1850–1856.
- Sime, P.J., and Gauldie, J. 1996. Mechanisms of scarring. In *ARDS in adults*. T.W.H.C. Evans, editor. Chapman & Hall Medical. London, United Kingdom. 215–231.
- Ziegenhagen, M.W., et al. 1998. Increased expression of proinflammatory chemokines in bronchoalveolar lavage cells of patients with progressing idiopathic pulmonary fibrosis and sarcoidosis. *J. Investig. Med*. **46**:223–231.
- Marshall, R., Bellingan, G., and Laurent, G. 1998. The acute respiratory distress syndrome: fibrosis in the fast lane. *Thorax*. **53**:815–817.
- Kotecha, S., Wilson, L., Wangoo, A., Silverman, M., and Shaw, R.J. 1996. Increase in interleukin (IL)-1 beta and IL-6 in bronchoalveolar lavage fluid obtained from infants with chronic lung disease of prematurity. *Pediatr. Res*. **40**:250–256.
- Whyte, M., et al. 2000. Increased risk of fibrosing alveolitis associated with interleukin-1 receptor antagonist and tumor necrosis factor-alpha gene polymorphisms. *Am. J. Respir. Crit. Care Med*. **162**:755–758.
- Mikuniya, T., et al. 1997. Quantitative evaluation of the IL-1 beta and IL-1 receptor antagonist obtained from BALF macrophages in patients with interstitial lung diseases. *Sarcoidosis Vasc. Diffuse Lung Dis*. **14**:39–45.
- Mikuniya, T., et al. 2000. Significance of the interleukin-1 receptor antagonist/interleukin-1 beta ratio as a prognostic factor in patients with pulmonary sarcoidosis. *Respiration*. **67**:389–396.
- Katzenstein, A.L., and Myers, J.L. 1998. Idiopathic pulmonary fibrosis: clinical relevance of pathologic classification. *Am. J. Respir. Crit. Care Med*. **157**:1301–1315.
- Postlethwaite, A.E., et al. 1988. Modulation of fibroblast functions by interleukin 1: increased steady-state accumulation of type I procollagen messenger RNAs and stimulation of other functions but not chemotaxis by human recombinant interleukin 1 alpha and beta. *J. Cell Biol*. **106**:311–318.
- Tufvesson, E., and Westergren-Thorsson, G. 2000. Alteration of proteoglycan synthesis in human lung fibroblasts induced by interleukin-1beta and tumor necrosis factor-alpha. *J. Cell Biochem*. **77**:298–309.
- Rochester, C.L., and Elias, J.A. 1994. Cytokines and cytokine networking in the pathogenesis of interstitial and fibrotic lung disorders. *Seminars in Respiratory and Critical Care Medicine*. **14**:389–416.
- Boyle, J.E., et al. 1999. Prostaglandin-E2 counteracts interleukin-1beta-stimulated upregulation of platelet-derived growth factor alpha-receptor on rat pulmonary myofibroblasts. *Am. J. Respir. Cell Mol. Biol*. **20**:433–440.
- Fisher, C.J., et al. 1994. Recombinant human interleukin 1 receptor antagonist in the treatment of patients with sepsis syndrome. Results from a randomized, double-blind, placebo-controlled trial. Phase III rIL-1ra Sepsis Syndrome Study Group. *JAMA*. **271**:1836–1843.
- Fisher, C.J., et al. 1994. Role of interleukin-1 and the therapeutic potential of interleukin-1 receptor antagonist in sepsis. *Circ. Shock*. **44**:1–8.
- Re, F., et al. 1994. The type II "receptor" as a decoy target for interleukin 1 in polymorphonuclear leukocytes: characterization of induction by dexamethasone and ligand binding properties of the released decoy receptor. *J. Exp. Med*. **179**:739–743.
- Coulter, K.R., Wewers, M.D., Lowe, M.P., and Knoell, D.L. 1999. Extracellular regulation of interleukin (IL)-1beta through lung epithelial cells and defective IL-1 type II receptor expression. *Am. J. Respir. Cell Mol. Biol*. **20**:964–975.