

Male Gonadal Environment Paradoxically Promotes Dacryoadenitis in Nonobese Diabetic Mice

Robert E. Hunger,* Claude Carnaud,† Irina Vogt,* and Christoph Mueller*

*Department of Pathology, University of Bern, CH-3010 Bern, Switzerland; and †INSERM U25, Hôpital Necker, 75743 Paris Cedex 15, France

Abstract

Similar to pancreatic islets, submandibular glands are more rapidly infiltrated in female NOD mice than in males. The present comparative analysis of cellular infiltrations in lacrimal glands, however, revealed the opposite finding. At 12 wk of age, ~25% of male lacrimal tissue area is infiltrated, whereas age-matched female NOD mice still lack major signs of inflammation. T cells predominate in early stages of invasion, but B cells accumulate promptly in more advanced stages, and ultimately dominate over T cells. Dacryoadenitis is promoted by sex hormones, as suggested by the reduced infiltrations seen in orchidectomized NOD males ($P < 0.01$). It is also controlled by the local environment provided by the lacrimal tissue. Splenocytes from 4- and 20-wk-old female NOD mice cause massive lesions upon adoptive transfer into NOD male recipients while, conversely, female recipients develop barely any histological sign of infiltration, even after transfer of splenocytes from 20-wk-old donor males. These observations provide strong evidence for a dacryoadenitis-promoting role of male gonadal hormones in NOD mice, a finding that contrasts the known androgen-mediated protective effects on insulinitis and submandibulitis in the same strain and on dacryoadenitis in other animal models of Sjögren's syndrome. (*J. Clin. Invest.* 1998. 101:1300–1309.) Key words: lacrimal glands • submandibular glands • sex hormones • Sjögren's syndrome • castration

Introduction

The nonobese diabetic (NOD)¹ mouse is a widely used animal model for insulin-dependent diabetes mellitus (IDDM; 1, 2). In addition to the well-characterized autoimmune infiltration of the islets of Langerhans, other organs, including the submandibular glands, the lacrimal glands, the thyroid, or the ovaries, show signs of a predominantly mononuclear cell infil-

tration. Inflammatory infiltrates of pancreatic islets and submandibular glands at early stages of disease are mainly composed of T cells (CD4 T cells in particular). B cells and macrophages increase progressively in the later stages of infiltration. These observations, together with the observed presence of autoreactive T cells and the ability to transfer disease by T cells from diabetic donors into NOD neonates (3), NOD.SCID mice (4), or irradiated young adult NOD mice (5), lead to the conclusion that insulinitis and submandibulitis are primarily T cell-mediated autoimmune disorders. This lymphocytic infiltration of pancreatic islets (insulinitis) and submandibular glands (submandibulitis) results in corresponding losses of β cells and exocrine gland function, respectively. Kinetics and the extent of cellular infiltration of pancreatic islets and submandibular glands are different in male and female NOD mice. Infiltrations progress more rapidly in females, and are usually more severe than in males, a finding in keeping with the overall higher incidence of overt diabetes (6). On the other hand, the kinetics of insulinitis and submandibulitis are accelerated in castrated NOD males, and resemble that observed in untreated age-matched females, thus indicating that the sexual dimorphism is, at least in part, related to the gonadal hormone environment (7).

Several reports indicate that the nature of resident lymphocyte populations differs in lacrimal and salivary gland tissue of patients with, or of mouse models of, Sjögren's Syndrome (for review see reference 8). Recent reports analyzing exocrine gland inflammation in multiple autoimmune strains of mice also demonstrated that the degree of inflammation in NOD mice displayed a tissue-specific pattern: disease expression was far worse in lacrimal glands of males, whereas immune pathology was far greater in salivary tissues in females (9, 10). However, no exact data are available on the kinetics of infiltration and sex-related influences exerted upon the inflammation of extraorbital lacrimal glands (dacryoadenitis) in NOD mice.

Because NOD is considered to be a relevant model of Gougerot-Sjögren syndrome (6, 11), however, we found it important to specifically examine lacrimal gland manifestations that are considered to be a hallmark of the disease. Tear film dysfunction represents one of the most common symptoms in human patients suffering from Gougerot-Sjögren syndrome (12, 13). While analyzing the influence of TNF- α on inflammatory infiltration in lacrimal and submandibular glands of NOD mice (14), we surprisingly found that dacryoadenitis in NOD mice was more pronounced in male animals. Therefore, we have attempted, to follow the kinetics and cellular composition of lacrimal gland infiltrates in male and female NOD mice, and to relate these events with contemporaneous infiltration of the submandibular glands and the pancreatic islets.

Methods

Animals and surgery. NOD mice from two independent sources—the core animal facility of the Medical Faculty in Berne and Necker

Address correspondence to Christoph Mueller, Ph.D., Department of Pathology, University of Bern, Murtenstrasse 31, CH-3010 BERN, Switzerland. Phone: +41-31-632-89-04; FAX: +41-31-381-87-64; E-mail: muellerc@patho.unibe.ch

Received for publication 17 July 1997 and accepted in revised form 15 January 1998.

1. Abbreviations used in this paper: IDDM, insulin-dependent diabetes mellitus; NOD, nonobese diabetic; SPF, specified pathogen-free.

J. Clin. Invest.

© The American Society for Clinical Investigation, Inc.
0021-9738/98/03/1300/10 \$2.00

Volume 101, Number 6, March 1998, 1300–1309
<http://www.jci.org>

Hospitals, Paris—were used in this study. The former were raised under conventional conditions, while the latter came from a strict specified pathogen-free (SPF) environment. NOD.SCID mice (15) bred and maintained under SPF conditions were used as recipients in adoptive cell transfer experiments. Orchidectomies and ovariectomies were performed at weaning under ether anaesthesia. Sham-operated littermates were used as controls.

Tissue processing. Pancreases, submandibular salivary glands, and the extraorbital part of the lacrimal glands were removed and immediately fixed in 4% paraformaldehyde in PBS. After postfixing overnight, tissues were further processed for paraffin embedding by routine techniques.

For immunohistochemistry, tissue specimens of submandibular salivary glands and extraorbital lacrimal glands were embedded in O.C.T. compound (Miles Laboratories, Elkhart, IN) with a tissue specimen from the spleen as a control, and stored at -70°C .

Evaluation of tissue sections. The inflammatory infiltration in the pancreatic islets (insulinitis score) was evaluated and classified for each islet according to the following grading system: 0, intact islet; 1, area of mononuclear cell infiltration within an islet $< 25\%$; 2, area of infiltration 25–50%; 3, area of infiltration $> 50\%$; 4, end stage of insulinitis characterized by small retracted islets with or without residual infiltrate (9). Severity of insulinitis was estimated for each animal by evaluating at least 20 islets on three noncontiguous tissue sections stained with hematoxylin and eosin.

For analysis of the extent of the inflammatory infiltrates in the submandibular and lacrimal glands, a different image analysis-based method was used. In brief, we used a high-resolution color video camera CF20DX with CFDX Camera control 0.98 software (KAPPA; Messtechnik GmbH, Gleichen, Germany) on a light microscope (Leitz DMRB; Leica Mikroskopie und Systeme GmbH, Wetzlar, Germany). The computer-based analysis was performed on an AST Power Premium Computer GX P/90 (AST Research Inc., Irvine, CA) using Image-Pro Plus for Windows software (version 1.3; Media Cybernetics, Silver Spring, MD). The image of the whole gland on three noncontiguous tissue sections stained with hematoxylin and eosin was acquired and analyzed. To this end, the whole area of the tissue section was carefully surrounded using the computer mouse (total area = 100%). Subsequently, the entire tissue section was screened for the presence of infiltrating cell foci, and the relative area occupied by the infiltrating cells was calculated.

Immunohistochemistry. Serial frozen sections of submandibular gland, lacrimal gland, and spleen were stained with the rat anti-mouse monoclonal antibodies 53–2.1 (anti-Thy1.2), GK1.5 (anti-CD4), 53–6.7 (anti-CD8a), and M1/70 (anti-Mac1; all from American Type Culture Collection, Rockville, MD) as a first-stage reagent. Peroxidase-conjugated rabbit anti-rat immunoglobulin (DAKOPATTS, Copenhagen, Denmark) was used as a second-stage reagent at a 1:25 dilution in 10% normal mouse serum. 3,3'-Diaminobenzidine (Sigma Chemical Co., St. Louis, MO) was used as a substrate for peroxidase.

Evaluation of immunohistochemistry. Infiltrating cells staining positive with anti-Thy1.2, anti-B220, or anti-Mac1 primary antibodies were counted on corresponding tissue areas of serial cryostat sections using a regular microscope. At least 3 mm² of tissue section or 1,000 single cells were examined per gland.

Flow cytometric analysis of infiltrating cells. Submandibular gland and lacrimal gland-infiltrating cells were isolated as previously described (14). Lacrimal glands of male and submandibular glands of female NOD mice were carefully removed. Care was taken not to include cervical lymph nodes. One half of both the left and right glands were fixed in 4% paraformaldehyde in PBS and processed for preparation of tissue sections as described above. The extent of infiltrated area was determined as described above. The remaining parts of the glands were teased into small pieces, and single-cell suspensions were prepared by carefully disrupting the tissue pieces between the frosted ends of two glass slides. Erythrocytes were removed by osmotic shock according to a standard protocol. Single-cell suspensions of spleen were prepared by standard techniques. Isolated cells were

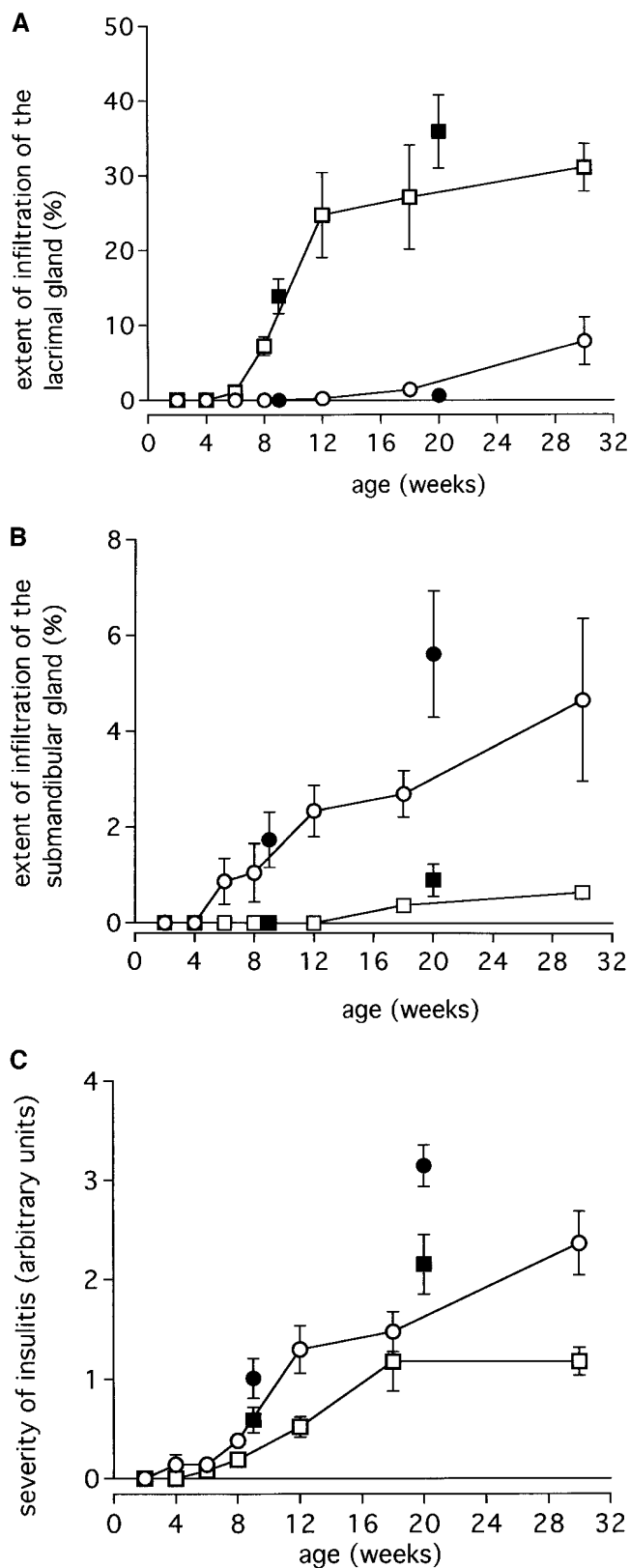


Figure 1. Time course of cellular infiltration into lacrimal glands (A), submandibular glands (B), and pancreatic islets (C) of female (circles) and male (squares) NOD mice. Autochthonous NOD/Berne mice bred under conventional conditions are represented with open symbols, and NOD/Nck raised under SPF conditions are represented with closed symbols. For each time point the mean (\pm SEM) of six mice kept under conventional conditions and of 8–10 mice kept under SPF conditions is indicated.

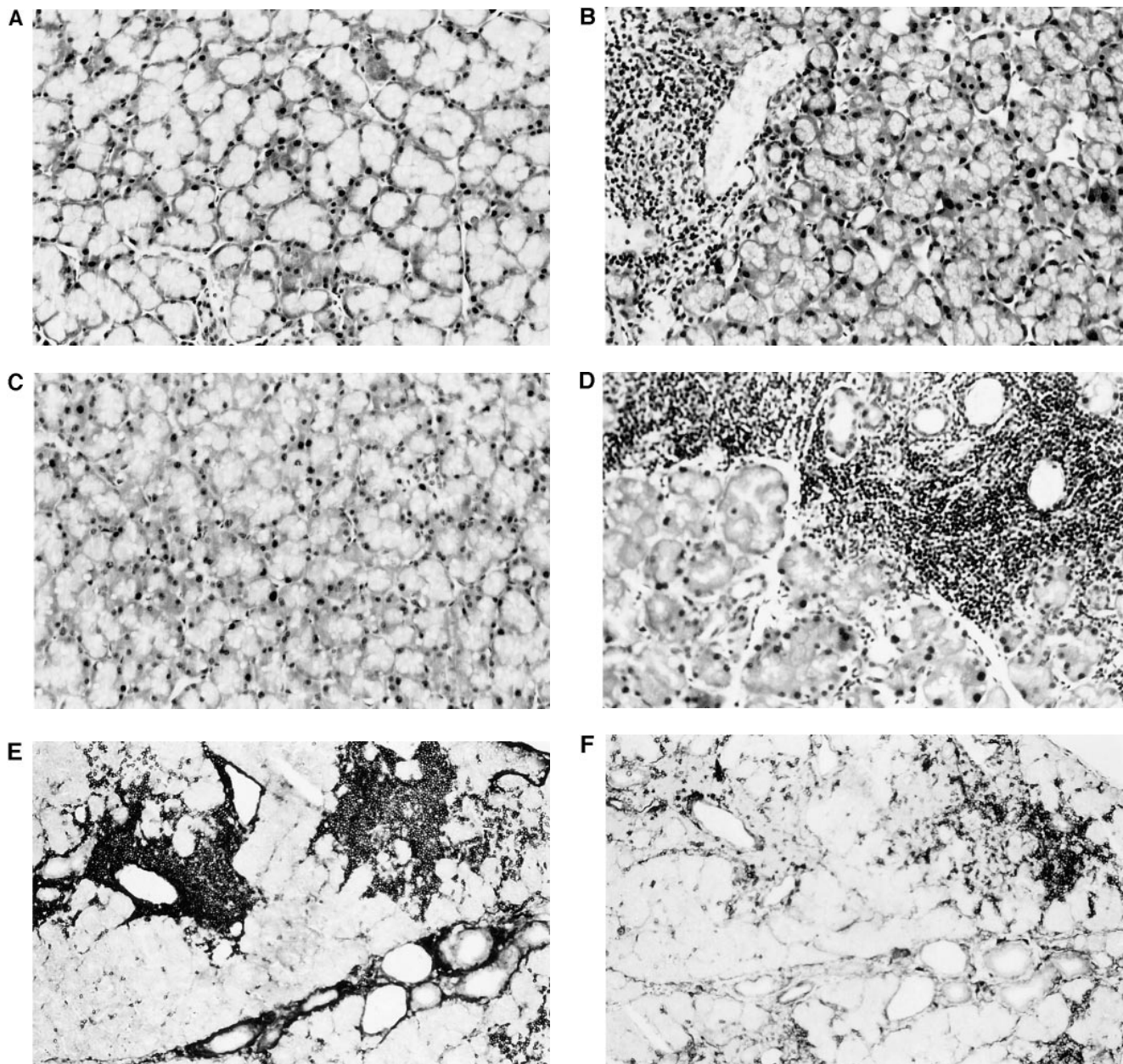


Figure 2. Representative tissue sections of lacrimal glands of NOD mice. At 4 wk of age, neither females (A) nor males (C) show infiltrates. However, at 20 wk of age the infiltrates are clearly less prominent in female (B) than in male (D) NOD mice. Immunohistochemical stainings of tissue sections from a 12-wk-old male NOD mouse show nonrandom distribution of lacrimal gland-infiltrating B cells (E) and T cells (F).

subsequently incubated on ice for 20 min with the following primary antibodies: FITC-coupled anti-Thy1.2 antibody (clone 53-2.1), FITC-coupled anti-CD4 (clone GK1.5), biotinylated anti-CD45 (clone M1/9.3.4.HL.2; all obtained from American Type Culture Collection and fluoresceinated or biotinylated according to standard protocols), phycoerythrin-coupled anti-B220 antibody (clone RA3-6B2; PharMingen, San Diego, CA), biotinylated anti-CD19 (clone 1D3; PharMingen), and phycoerythrin-coupled anti-CD8 α (clone 53-6.7; Sigma Chemical Co.). Samples with biotinylated primary antibodies were incubated for 15 min on ice with Streptavidin-Tricolor (Caltag Laboratories, San Francisco, CA) as a second-step reagent. After completion of the staining procedure, cells were fixed in 0.5% buffered paraformaldehyde. Cells were analyzed on a FACScan™ (Becton Dickinson, San Jose, CA) using Macintosh-based CellQuest software.

Adoptive cell transfer. Adoptive cell transfer into NOD.SCID mice was performed as previously described (4) using the following modifications: spleens from NOD donor mice were homogenized in Iscove's modified Dulbecco's medium containing 5% FCS, and erythrocytes were removed by osmotic shock. 2×10^7 unfractionated splenocytes in 200 μ l saline were injected intravenously into 8-12-wk-old recipients.

Results

Sex-related differences in the cellular kinetics of infiltration. For assessment of cellular infiltration kinetics in the three organs analyzed, i.e., extraorbital lacrimal gland, submandibular sali-

vary gland, and pancreatic islets, tissue sections of the respective organs were examined histopathologically. The areas of infiltration in lacrimal and submandibular gland sections were morphometrically measured for precise quantitative comparisons between groups.

The first infiltrating cells in the lacrimal glands of NOD mice appear at ~ 6 – 8 wk, and are exclusively detected in male littermates. At 12 wk, lacrimal glands of female littermates are still devoid of infiltrating cells, and at 30 wk, the area covered by mononuclear cells averages 8% (Fig. 1 A). By contrast, invasion of the lacrimal gland in NOD males progresses extremely rapidly between 6 and 12 wk of age, from an average of ~ 1 to 25% (Fig. 1 A). Lacrimal tissue sections are later infiltrated by a dense mononuclear cell infiltrate (Fig. 2). This extensive and almost exclusive infiltration of male lacrimal glands is in sharp contrast with the higher susceptibility of female NOD mice to submandibulitis (Fig. 1 B) and insulinitis (Fig. 1 C). First signs of mononuclear infiltration of the submandibular glands are seen in female NOD mice at 6 wk of age. Cellular infiltration increases gradually to $\sim 4\%$ of the total gland area at 30 wk of age. In male NOD mice, the onset of submandibulitis is delayed by ~ 8 wk compared with female littermates, and maximum extent of cellular infiltration never exceeds 1.2% of the total submandibular gland area. There is a remarkable contrast between the lack of cellular infiltrates in the submandibular glands of 12-wk-old male NOD mice and the massive invasion of their lacrimal glands. Representative

histological sections from lacrimal glands of female and male NOD mice at 4 and 20 wk are shown in Fig. 2. The corresponding sections of submandibular gland samples are presented in Fig. 3. The same sexual dimorphism is seen for insulinitis. Islet cell infiltration occurs at a younger age in female NOD mice, and progresses more rapidly than in the male littermates.

To rule out the possibility that this sharp contrast between lacrimal and submandibular gland inflammation might be particular to a NOD mouse colony and to its conditions of maintenance, we further analyzed NOD mice derived from a second breeding colony kept under SPF conditions. Lacrimal and salivary gland samples as well as islet samples from 9 and 20-wk-old mice were analyzed according to the same criteria, for the presence and the extent of cellular infiltration. Similar to our first results, lacrimal glands from the female mice presented practically no histological alterations ($0.6\% \pm 0.3$ SEM at 20 wk), whereas in males the area covered by inflammatory cells was already important at 9 wk (14.0% , $SEM \pm 2.3$), and increased considerably at 20 wk (36.0% , $SEM \pm 15.5$; Fig. 1 A). The corresponding values for the submandibular glands were 1.7% ($SEM \pm 0.6$) in 9-wk-old females vs. 0% in age-matched males, and 5.6% ($SEM \pm 1.3$) in 20-wk-old females vs. 1.0% ($SEM \pm 0.3$) in age-matched males (Fig. 1 B). Hence, the striking sex-related differences in the infiltration of salivary vs. lacrimal glands in NOD mice with a preferential infiltration of submandibular glands in females and of the lacrimal glands in males, is even more pronounced in the batch of NOD mice

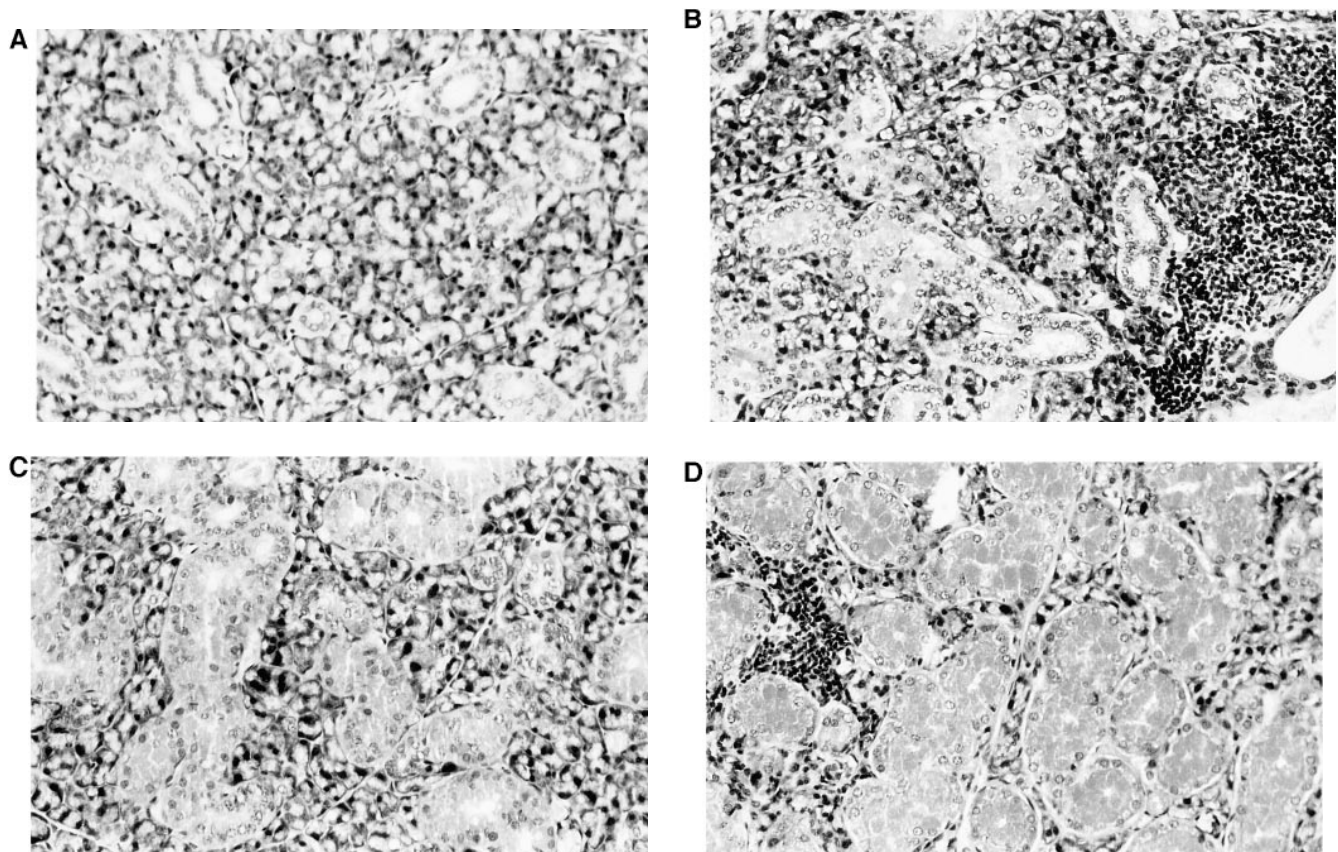


Figure 3. Representative tissue sections of submandibular glands of NOD mice. At 4 wk of age neither females (A) nor males (C) show infiltrates. However, at 20 wk of age, the infiltrates are clearly more prominent in female (B) than in male (D) NOD mice.

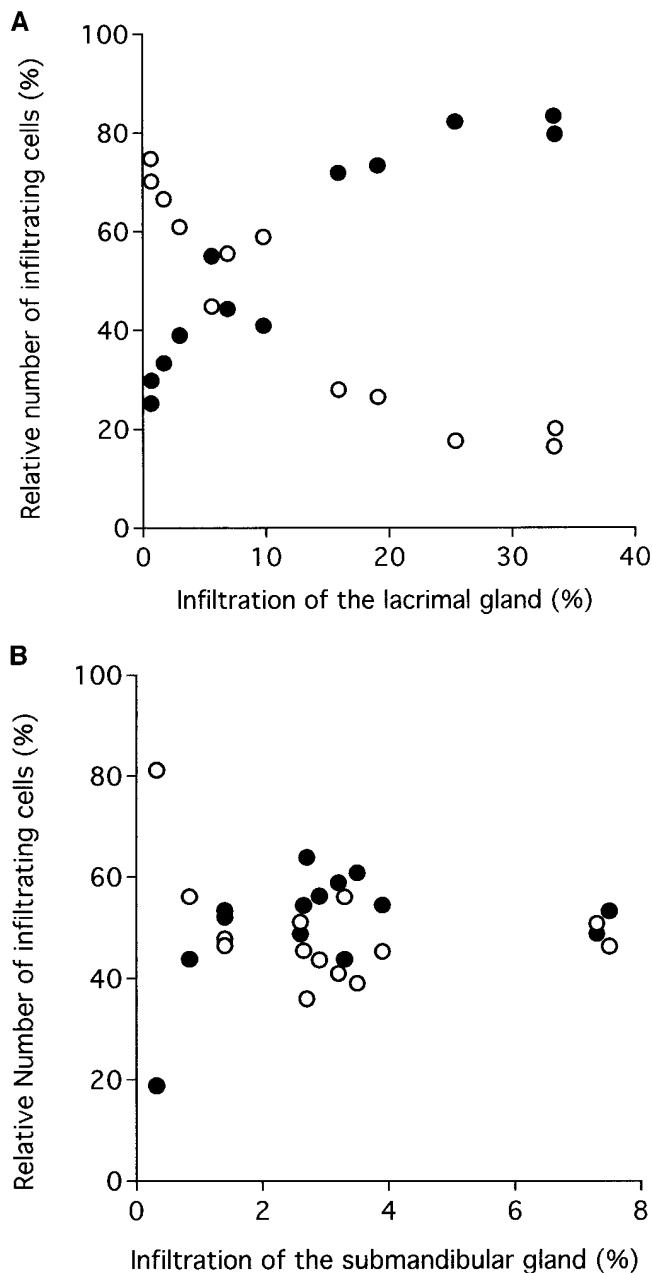


Figure 4. Immunohistochemical analysis of the phenotype of lacrimal gland-infiltrating cells of male (A) and submandibular gland-infiltrating cells of female (B) NOD mice. The relative number of T cells (open symbols) and B cells (closed symbols) is indicated for each single animal analyzed.

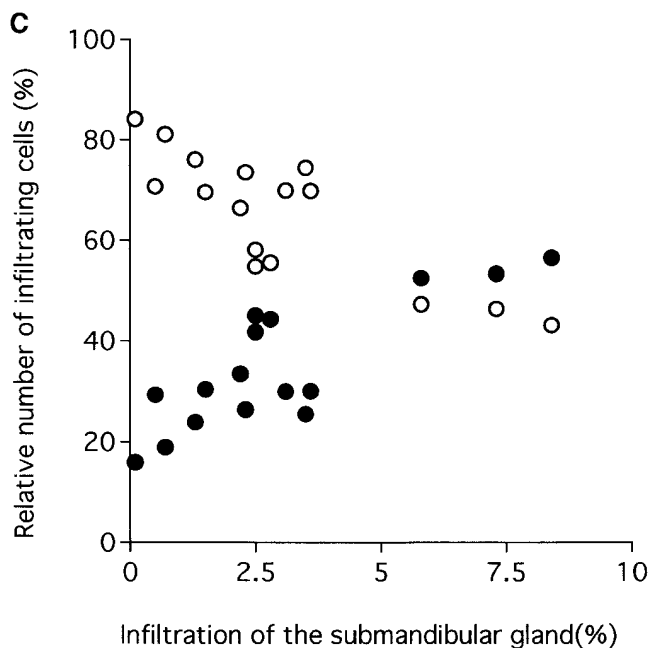
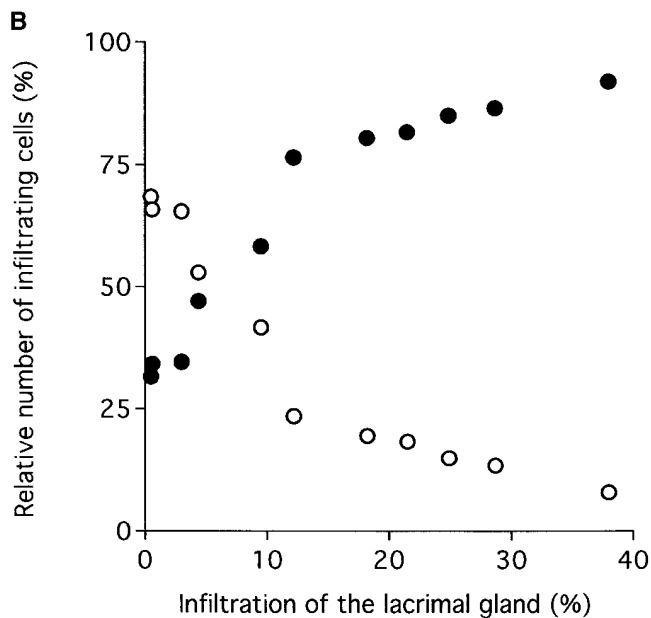
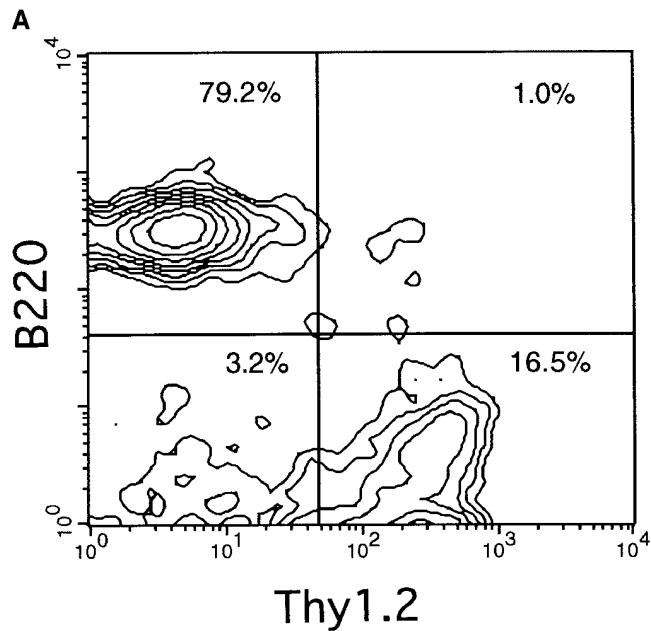
kept under SPF conditions than in the conventional mice. The severity of insulinitis (according to the grading system of Miller et al. [16]) follows the same pattern as submandibulitis: 1.0 (SEM±0.6) in 9-wk-old females vs. 0.6 (SEM±0.1) in males, and 3.2 (SEM±0.6) in 20-wk-old females vs. 2.16 (SE±0.9) in males (Fig. 1 C).

Phenotypic characterization of the cells that infiltrate the lacrimal and submandibular glands. Immunohistochemical stainings reveal the dominant presence of T and B cells characterized by a positive reaction for Thy1.2 and B220, respectively. Variations in the extent of infiltration in different animals of

the same age group are considerable (Fig. 1, A and B). Therefore, in Fig. 4 A the proportion of the respective cell subsets in the infiltrates are presented as a function of the percentage of infiltrated tissue area, and not of the age of the animals. In small lesions that probably correspond to early stages of lacrimal gland infiltration, the infiltrates are primarily composed of T cells. However, B cells rapidly become the predominant cell type in more advanced stages of infiltration (Fig. 4 A). In female submandibular glands (Fig. 4 B), lesions begin with a majority of T cells, but B cells never become as preponderant as in male lacrimal glands. B and T cells are nonrandomly distributed in the focal infiltrates. At advanced stages of infiltration, B and T cells even show signs of organization into distinct B and T cell clusters as shown for the lacrimal gland of a 12-wk-old male NOD mouse (Fig. 2, F and E). Macrophages, as assessed by immunohistochemical staining with the monoclonal antibody M1/70, contribute moderately to the infiltrates both in lacrimal and submandibular glands.

To exclude the possibility of sampling errors while analyzing tissue sections, and to overcome potential limitations in enumerating immunohistochemically stained sections, in particular for discriminating between stained and adjacent non-stained cells, an additional flow cytometric analysis of the cellular infiltrates was performed. Lacrimal glands of male and submandibular glands of female NOD mice between 6 and 24 wk of age were analyzed. The paired glands of each animal were each cut into two pieces of equal size. One half was paraffin-embedded to determine the extent of infiltration on H&E-stained tissue sections using an image analysis system as described in Methods. Cell suspensions were prepared from the remaining gland tissue and stained with directly labeled antibodies against B220 and Thy1.2 for subsequent flow cytometric analysis. The population of interest, namely the lymphoid cell population, was gated first on the basis of forward and side light scatter, and second on the basis of CD45 expression. The relative percentage of B and T cells in relation to the extent of infiltration is shown in Fig. 5 for each individual animal analyzed. Again, in lacrimal glands of male mice, the B cell population becomes rapidly dominant, representing between 75 and 95% of the infiltrate. In the submandibular glands, B cells increase with the extent of infiltration, but they never supersede T cells. Since the surface marker B220 is not exclusively expressed on B cells, isolated cells from lacrimal tissue were also stained with biotinylated anti-CD19 antibody. Over 95% of the B220⁺ cells were positive for CD19, thus confirming that the overwhelming majority of infiltrating B220⁺ cells are B cells. The relative abundance of CD4 and CD8 T cell subsets was also determined by FACScan™ analysis. The mean CD4/CD8 ratio is 3.86 (SEM±0.44; n = 16) for the submandibular gland, and 3.47 (SEM±0.18; n = 11) for the lacrimal gland. There is no influence of the extent of infiltration or of the age of the animals (data not shown). This ratio is significantly ($P < 0.0001$) higher than the one measured in the spleen of NOD mice of our colony (mean 2.77; SEM±0.10; n = 14).

Influence of castration on inflammatory infiltration. To ascertain directly the influence of the gonadal hormone environment on infiltration of lacrimal, submandibular, and Langerhans tissues, male and female NOD mice were castrated at weaning. Sham-operated littermates served as controls. As shown in Fig. 6 A, the infiltration pattern of 12-wk-old male NOD mice, orchidectomized at 4 wk, shows significant modifications reminiscent of what is usually seen in female NOD



mice. Islets of Langerhans and submandibular salivary glands are heavily infiltrated (significantly more than in sham-operated male littermates), while cellular infiltration of the lacrimal glands is significantly suppressed. On the other hand, ovariectomy of female NOD mice does not affect the infiltration patterns (Fig. 6 B).

Transfer of splenocytes into NOD.SCID mice. Due to the absence of mature B and T cells, NOD.SCID do not show cellular infiltrates in the islet of Langerhans, the submandibular, or the lacrimal glands. On the other hand, adoptive transfer of splenocytes from diabetic NOD mice into NOD.SCID recipients leads to insulinitis and IDDM. Therefore, these mice offer a unique opportunity to study the contribution of donor cells and host environment on the development of an inflammatory process. To assess more specifically the influence of host gender, we performed a series of adoptive transfer experiments in which splenocytes from adult donors were injected in female or male NOD.SCID recipients. In a first set of experiments, splenocytes from 12-wk-old male or female NOD mice were each injected into female NOD.SCID recipients. 8 wk after adoptive transfer of male or female splenocytes, female NOD.SCID recipient mice show intense cellular infiltrates in the submandibular glands and the islets of Langerhans, but only minimal signs of cellular infiltration in the lacrimal glands irrespective of the gender of the donor mice (Fig. 7 A). For comparison, the extent of infiltration in the NOD mice that served as donors is shown in Fig. 7 B. As expected, female donor mice show higher insulinitis scores and more florid cellular infiltrates in the submandibular salivary glands than do male donors, but also show significantly reduced infiltrates in the lacrimal glands. In a second set of experiments (Fig. 8), splenocytes of young (4-wk-old) and adult (20-wk-old) female NOD mice were adoptively transferred into male NOD.SCID recipients. 16 wk after transfer, irrespective of the age of the donor mice, the male NOD.SCID recipients showed extended inflammatory infiltrates of the lacrimal glands, but limited infiltrates in the submandibular glands and marked cellular infiltration of the islets of Langerhans. In conclusion, the transfer experiments show that it is the gender of the host that dictates tissue distribution of the infiltrates.

Figure 5. FACSscan-based phenotypic analysis of lacrimal gland-infiltrating cells. (A) Representative example of a FACSscan-based phenotypic analysis of lacrimal gland-infiltrating cells. Cells were isolated and stained as described in Methods. After gating on the lymphoid cell population by side (SSC-Height) and forward (FSC-Height) light scatter, CD45⁺ cells were analyzed for the presence of B (B220) and T (Thy1.2) cell markers. Lacrimal glands of male and submandibular glands of female NOD mice were analyzed. The glands of each animal were cut into two equal pieces, and one half was paraffin-embedded and used to determine histologically the extent of infiltration. From the remaining part of the glands, single-cell suspensions were prepared for subsequent staining and analysis on a FACSscan. Relative frequencies of Thy1.2-positive T cells (*open symbols*) and B220-positive B cells (*closed symbols*) in lacrimal gland-infiltrating cells (B) and in submandibular gland-infiltrating cells (C) are shown for individual animals analyzed as a function of the extent of gland infiltration.

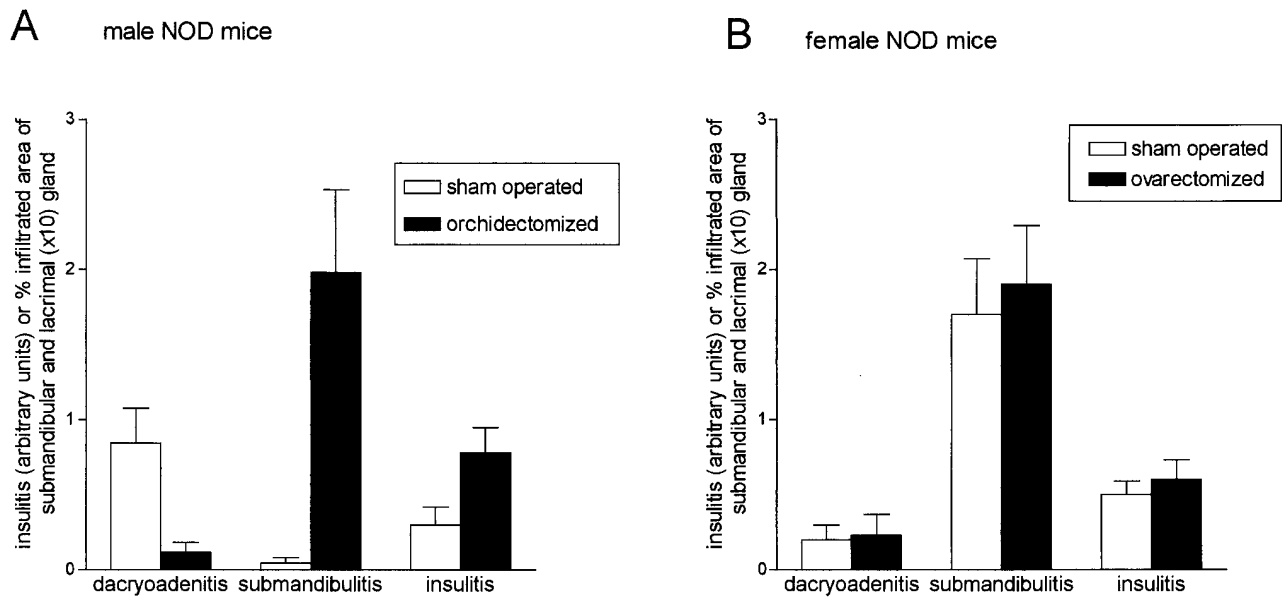


Figure 6. Effect of castration on inflammatory infiltration in pancreatic islets (*insulinitis*), submandibular (*submandibulitis*), and lacrimal glands (*dacryoadenitis*). (A) Male NOD mice were sham-operated (*open bars*, $n = 8$) or orchidectomized (*filled bars*, $n = 9$) at weaning. (B) Female NOD mice were sham-operated (*open bars*, $n = 9$) or ovariectomized (*filled bars*, $n = 9$) at weaning. Infiltration of the lacrimal glands, submandibular glands, and islets of Langerhans was determined 8 wk after surgery. The Student's *t* test was used to compare the inflammatory infiltrates in castrated and sham-operated animals. The significant *P* values are as follows: (A) dacryoadenitis, $P = 0.006$; submandibulitis, $P = 0.003$; insulinitis, $P = 0.029$. $n =$ number of animals analyzed.

Discussion

Histopathological examination of extraorbital lacrimal gland in female and male NOD mice between 2 and 30 wk of age provides compelling evidence for regulatory mechanisms dis-

tinct from those operative in the submandibular gland and pancreatic islets. The observed preferential infiltration of the lacrimal glands in male NOD mice is even more surprising in light of other mouse models of dacryoadenitis, such as NZB \times NZW F₁ mice, MLR/lpr mice, or even in normal BALB/c mice

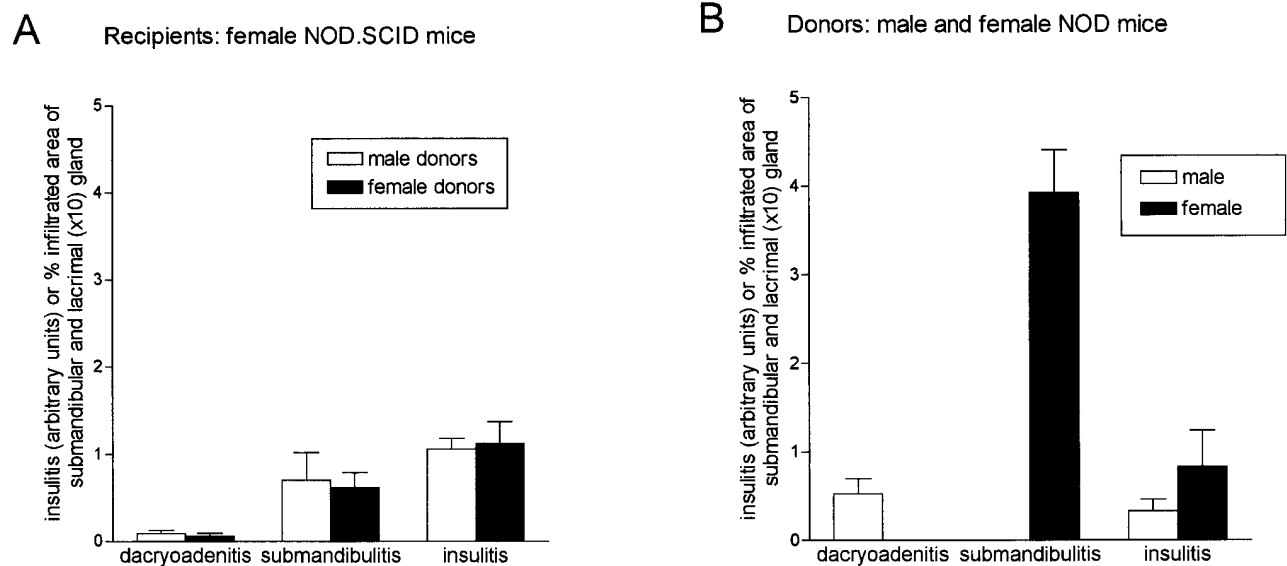


Figure 7. Adoptive transfer of splenocytes from 12-wk-old donor mice into female NOD.SCID mice. (A) Infiltration of the lacrimal glands, submandibular glands, and islets of Langerhans determined 8 wk after adoptive transfer of male splenocytes (*open bars*, $n = 7$) and female splenocytes (*filled bars*, $n = 6$). (B) Infiltration of the lacrimal glands, submandibular glands, and islets of Langerhans of the 12-wk-old male (*open bars*, $n = 4$) and female (*filled bars*, $n = 3$) donor animals. The Student's *t* test was used to compare the inflammatory infiltrates in recipients of female and male splenocytes, and between male and female donor mice, respectively. The significant *P* values are as follows: (B) dacryoadenitis, $P = 0.045$; submandibulitis, $P = 0.0002$; insulinitis, $P = 0.10$. $n =$ number of animals analyzed.

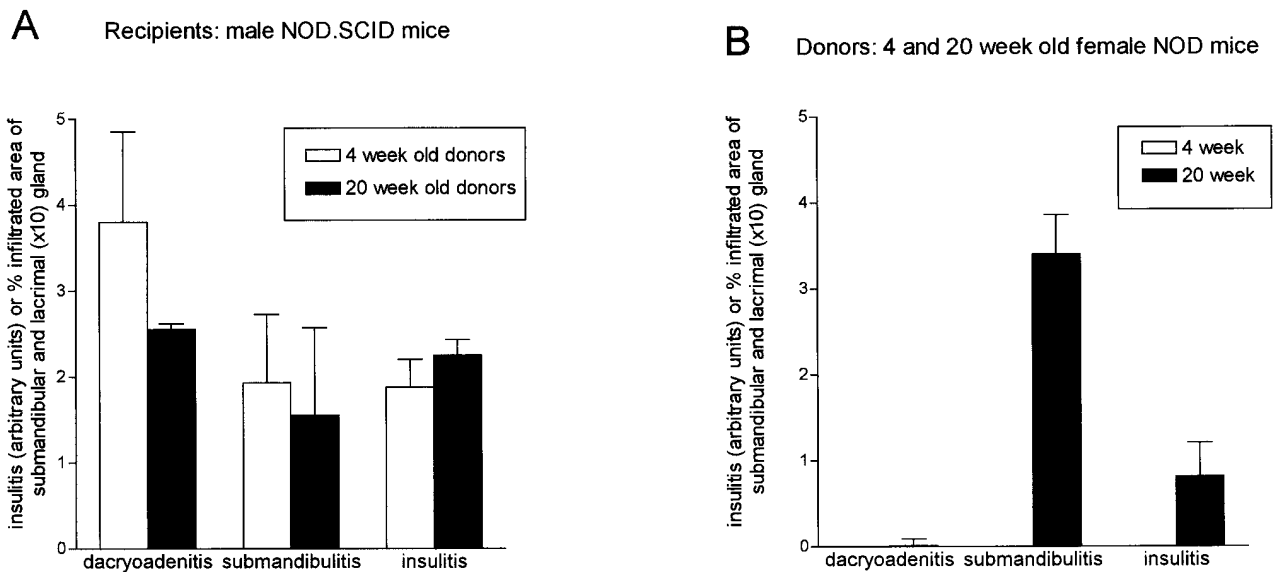


Figure 8. Adoptive transfer of splenocytes from 4- and 20-wk-old female NOD mice into male NOD.SCID mice. (A) Infiltration of the lacrimal glands, submandibular glands, and islets of Langerhans, determined 16 wk after adoptive transfer of splenocytes from 4-wk-old (open bars, $n = 5$) and 20-wk-old (filled bars, $n = 10$) female NOD mice. (B) Infiltration of the lacrimal glands, submandibular glands, and islets of Langerhans of the 4-wk-old (open bars, $n = 3$) and 20-wk-old female (filled bars, $n = 4$) donor animals. The Student's t test was used to compare the inflammatory infiltrates in recipients of 4- and 20-wk-old female splenocytes, and between the 4- and 20-wk-old female donor mice, respectively. The significant P values are as follows: (B) submandibulitis, $P = 0.002$; insulinitis, $P < 0.05$. $n =$ number of animals analyzed.

where females are more susceptible than males (17–22). In some of these models, the male gonadal environment has been shown to specifically inhibit development of inflammatory infiltrates in this tissue (23–25). Preferential infiltration of NOD male lacrimal gland has been repeatedly observed in two independent cohorts of mice, derived from different progenitors and raised in different facilities. Thus, this phenomenon cannot be attributed to genetic drift or to a particular sanitary status of a given colony. The fact that lesion extension seems even more pronounced in mice kept under SPF conditions is in keeping with the general notion that, in NOD mice, a clean status promotes expression of the autoimmune manifestations (26). Thus, in this respect, dacryoadenitis follows the same rules as insulinitis and submandibulitis. In agreement with our analysis of male NOD mice, substantial infiltration of the lacrimal gland in 5-mo-old male NOD mice has been recently reported (17). Unfortunately, age-matched female NOD mice were not assessed in this study.

The respective proportions of T and B cell subsets in lacrimal glands vs. submandibular glands show some interesting differences with time. In both tissues, T cells are predominant in the early stages of inflammatory infiltration. In the more advanced lesions of dacryoadenitis, however, we observe an impressive expansion or invasion of B cells that clearly becomes predominant, representing almost 90% of the whole infiltrate. An increase of the B cell subset during disease progression has also been reported for the islets of Langerhans, but not to such a great extent (27, 28). Our present results show that this observation is also true for submandibular gland infiltration. In the most advanced stages of submandibulitis, the proportion of B cells remains limited, barely exceeding that of T cells (Fig. 5). The question remains open as to whether this observation of prevailing B cells in late stages of dacryoadenitis reflects some

specific differences in the environment provided by this tissue. Local synthesis and release by epithelial cells of various pharmacological agents, including cytokines such as C-X-C and C-C chemokines (29), could directly or indirectly create the conditions of a specific milieu responsible for attraction and/or expansion of B cells. So far, reports on molecular mechanisms leading to inflammatory infiltration of the lacrimal gland are limited (30, 31–33). In a recent study we found that NOD transgenic for a soluble TNF-R p55 not only protected from onset of clinical IDDM, but also dramatically reduced infiltration of the submandibular glands (in female NOD mice) and the lacrimal glands (in male NODs), thus providing evidence for direct involvement of this proinflammatory cytokine in the destructive cellular infiltration of these organs (14). The fact that, as already reported for MRL/lpr mice (34), the salivary gland infiltrates in NOD mice are distinctly less severe than those of lacrimal glands (compare Fig. 1, B and C), provides another indication that each inflammatory site evolves independently from the other.

Upon analysis of the immunohistochemically stained tissue sections of lacrimal and submandibular glands, we found that B and T cells were nonrandomly distributed over the whole tissue section. In late stages they may even cluster into distinct B and T cell areas. Similar findings have already been described in biopsies from patients with Sjögren's syndrome (35). These findings prompted us to assess the relative frequency of these two subsets in the infiltrates, not only by immunohistochemistry, but also by flow cytometric analysis of the isolated gland-infiltrating cells. FACS analysis of the T cell subsets in the cellular infiltrates reveals a predominance of CD4⁺ T cells both in lacrimal glands of males and in submandibular glands of female NOD mice. The CD4/CD8 ratio is also significantly higher than in the spleen, indicating a preferential im-

migration and/or expansion of this T cell subset rather than a random accumulation. This preferential infiltration of CD4 T cells has also been reported for insulinitis (27). Moreover, a preferential infiltration of the lacrimal and submandibular glands by CD4 T cells is not unique to NOD mice; an elevated CD4/CD8 ratio has been previously noted in dacryoadenitis of MRL/lpr, MRL/+, and NZB/NZW mice (36). An elevated CD4/CD8 ratio has also been described in salivary glands of patients with Sjögren's syndrome (37), and in infiltrated synovial membranes of patients with rheumatoid arthritis (38).

The observation that male NOD.SCID develop severe signs of lacrimal gland infiltration upon adoptive transfer of splenocytes from female donors, whereas female NOD.SCID mice fail to develop these severe manifestations upon male splenocyte transfer, indicates first that female splenocytes contain precursor cells capable of initiating infiltration of the lacrimal gland, and second, that the gonadal hormone environment of the recipients dominantly determines the time course and extent of dacryoadenitis. Castration experiments have been successfully used to demonstrate the protective effect of the male gonadal hormone environment against autoimmune infiltration of the pancreatic islets, and of the submandibular glands since orchidectomy of male NOD mice leads to submandibulitis, insulinitis, and subsequent onset of IDDM, comparable to what is seen in female NOD mice (7). In our study, castration of male NOD mice leads to accelerated infiltration of the submandibular glands. On the other hand, castration causes a significant reduction in the extent of lacrimal gland infiltration, thus clearly demonstrating the distinct effects of the gonadal hormones on cellular infiltration of submandibular and lacrimal glands. As discussed above, this result is in sharp contrast with several published reports demonstrating a beneficial effect of male hormone therapy upon dacryoadenitis (23, 39). The fact that these results were achieved in MRL/lpr or in NZB \times NZW mice could eventually explain such a discrepancy. First, the underlying mechanisms through which testosterone curtails lacrimal gland infiltration are complex and still unclear. Second, the pathogenic pathways at work in the three mouse models of Sjögren disease, i.e., MRL/lpr, NZB \times NZW, and NOD, are likely to be different as suggested already by the genetic analyses performed in these strains. Therefore, it is possible that in such tightly regulated systems as those controlling autoimmune infiltration, the same hormonal trigger may have (according to the circumstances) opposite impacts upon a given tissue. It is also interesting to note that ovariectomy had only a marginal effect on lacrimal gland infiltration, and practically no effect on salivary gland and pancreatic islets. This observation is in line with previous reports indicating only a minor effect of female sex hormones on submandibulitis and insulinitis (7). Furthermore, the finding that lacrimal glands of male NOD mice are infiltrated before significant infiltrates are observed in the pancreas rules out the possibility that infiltration of the lacrimal gland is due to the diabetic condition in NOD mice.

T cell reactivity against many autoantigens, especially proteins expressed in the islets of Langerhans, have been reported in NOD mice (7). A temporal analysis suggests that only a few autoantigens are targeted during initial stages of infiltration (40, 41). However, the primary target autoantigens on β cells in the pancreas and on cells of other affected organs of the NOD mouse, remain enigmatic. In this respect it will be of interest to examine the effects on dacryoadenitis of glutamic acid

decarboxylase and insulin tolerization, which was successfully used to prevent clinical onset of IDDM (41). A further possible reason for this mutual exclusive infiltration in male and female NOD mice may be ascribed to differential genetic control of infiltration to these organs. Analysis of MHC-congenic strains of NOD mice and microsatellite mapping of susceptibility loci for IDDM may be useful for elucidating this issue, as it has already been successfully used to demonstrate an overlapping but not identical genetic control of submandibular salivary gland infiltration and insulinitis (42, 43).

In conclusion, this study provides strong evidence for a disease-promoting role of male sex hormones in the pathogenesis of lacrimal gland infiltration in NOD mice. This result is in sharp contrast to the pattern observed in other mouse models of Sjögren's syndrome, such as the MLR/lpr mouse (34). In human clinics as well, Sjögren's syndrome is considerably more frequent in women than in men. NOD mice thus provide a unique opportunity to study in an individual animal the differential effects of gonadal hormones on the cellular and molecular mechanisms leading to selective infiltration of these glands.

Acknowledgments

We would like to thank Dr. M. Dardenne for critical review of the manuscript and helpful comments, Dr. Th. Schaffner for assistance in morphometric analysis of tissue sections, Marianne Bärtschi for technical assistance, Dr. Th. Seebeck and Dr. J.A. Laissue for helpful discussions and continuous support, and all members of the labs in Paris and Bern for continued stimulating discussions.

This work was supported by grant 31.43495.95 of the Swiss National Science Foundation.

References

1. Wicker, L.S., J.A. Todd, and L.B. Peterson. 1995. Genetic control of autoimmune diabetes in the NOD mouse. *Annu. Rev. Immunol.* 13:179-200.
2. Castano, L., and G.S. Eisenbarth. 1990. Type-1 diabetes: a chronic autoimmune disease of human, mouse and rat. *Annu. Rev. Immunol.* 8:647-679.
3. Bendelac, A., C. Carnaud, C. Boitard, and J.F. Bach. 1987. Syngeneic transfer of autoimmune diabetes from diabetic NOD mice to healthy neonates. Requirement for both L3T4+ and Lyt-2+ T cells. *J. Exp. Med.* 166:823-832.
4. Christianson, S.W., L.D. Shultz, and E. Leiter. 1993. Adoptive transfer of diabetes into immunodeficient NOD-scid/scid mice—relative contributions of CD4+ and CD8+ T-cells from diabetic versus prediabetic NOD.NON-Thy-1a donors. *Diabetes* 42:44-55.
5. Wicker, L.S., B.J. Miller, and Y. Mullen. 1986. Transfer of autoimmune diabetes mellitus with splenocytes from nonobese diabetic (NOD) mice. *Diabetes* 35:855-860.
6. Goillot, E., M. Mutin, and J.L. Touraine. 1991. Sialadenitis in nonobese diabetic mice: transfer into syngeneic healthy neonates by splenic T lymphocytes. *Clin. Immunol. Immunopathol.* 59:462-473.
7. Fitzpatrick, F., F. Lepault, F. Homo-Delarche, J.-F. Bach, and M. Dardenne. 1991. Influence of castration, alone or combined with thymectomy, on the development of diabetes in the nonobese diabetic mouse. *Endocrinology* 129:1382-1390.
8. Sullivan, D.A., and E.H. Sato. 1992. Potential therapeutic approach for the hormonal treatment of lacrimal gland dysfunction in Sjogren's syndrome. *Clin. Immunol. Immunopathol.* 64:9-16.
9. Toda, I., E.M. Rocha, L.A. da Silveira, L.A. Wickham, and D.A. Sullivan. 1997. Gender-related difference in the extent of lymphocytic infiltration in lacrimal and salivary glands of mouse models of Sjögren's syndrome. *Investig. Ophthalmol. Vis. Sci.* 34(Suppl.):S434.
10. Toda, I., L.A. Wickham, E.M. Rocha, L.A. Da Silveira, and D.A. Sullivan. 1997. Gender- and androgen-related impact on the expression of proto-oncogenes and apoptotic factors in lacrimal and salivary glands of mouse models of Sjögren's syndrome. *Adv. Exp. Med. Biol.* In press.
11. Humphreys Beher, M.G., Y. Hu, Y. Nakagawa, P.L. Wang, and K.R. Purushotham. 1994. Utilization of the non-obese diabetic (NOD) mouse as an animal model for the study of secondary Sjogren's syndrome. *Adv. Exp. Med. Biol.* 350:631-636.
12. Gougerot, H. 1925. Insufficance progressive et atrophie des glandes salivaires et muqueuses de la bouche, des conjonctives (et parfois des muqueuses,

- nasale, laryngée, vulvaire). "Sécheresse" de la bouche, des conjonctives, etc. *Bull. Soc. Fr. Dermatol. Syphiligr.* 32:376-379.
13. Fox, R.I., C.A. Robinson, J.G. Curd, F. Kozin, and F.V. Howell. 1986. Sjogren's syndrome. Proposed criteria for classification. *Arthritis Rheum.* 29: 577-585.
 14. Hunger, R.E., S. Müller, J.A. Laissue, M.W. Hess, C. Carnaud, I. Garcia, and C. Mueller. 1996. Inhibition of submandibular and lacrimal gland infiltration in NOD mice by transgenic expression of soluble TNF receptor p55. *J. Clin. Invest.* 98:954-961.
 15. Prochazka, M., H.R. Gaskins, L.D. Shultz, and E.H. Leiter. 1992. The nonobese diabetic scid mouse: model for spontaneous thymomagenesis associated with immunodeficiency. *Proc. Natl. Acad. Sci. USA.* 89:3290-3294.
 16. Miller, B.J., M.C. Appel, J.J. O'Neil, and L.S. Wicker. 1988. Both the L γ T-2+ and L3T4+ T-cell subsets are required for the transfer of diabetes in nonobese diabetic mice. *J. Immunol.* 140:52-58.
 17. Moore, P.A., D.I. Bounous, R.L. Kaswan, and M.G. Humphreys-Beher. 1996. Histologic examination of the NOD-mouse lacrimal glands, a potential model for idiopathic autoimmune dacryoadenitis in Sjogren's syndrome. *Lab. Anim. Sci.* 46:125-128.
 18. Jabs, D.A., E.L. Alexynder, and R. Green. 1985. Ocular inflammation in autoimmune MRL/MP mice. *Investig. Ophthalmol. Vis. Sci.* 26:1223-1229.
 19. Jabs, D.A., and R.A. Pendergast. 1988. Murine models of Sjogren's syndrome: immunohistological analysis of different strains. *Investig. Ophthalmol. Vis. Sci.* 29:1437-1443.
 20. Jabs, D.A., C. Enger, and R.A. Pendergast. 1991. Murine models of Sjogren's syndrome: evolution of the lacrimal gland inflammatory lesions. *Investig. Ophthalmol. Vis. Sci.* 32:371-380.
 21. Jabs, D.A., and R.A. Pendergast. 1994. Murine models of Sjogren's syndrome. *Adv. Exp. Med. Biol.* 350:623-630.
 22. Kessler, H.S. 1968. A laboratory model for Sjogren's syndrome. *Am. J. Pathol.* 52:671-676.
 23. Ariga, H., J. Edwards, and D.A. Sullivan. 1989. Androgen control of autoimmune expression in lacrimal glands of MRL/Mp-lpr/lpr mice. *Clin. Immunol. Immunopathol.* 53:499-508.
 24. Sato, E.H., H. Ariga, and D.A. Sullivan. 1992. Impact of androgen therapy in Sjogren's syndrome: hormonal influence on lymphocyte populations and Ia expression in lacrimal glands of MRL/Mp-lpr/lpr mice. *Investig. Ophthalmol. Vis. Sci.* 33:2537-2545.
 25. Sato, E.H., and D.A. Sullivan. 1994. Comparative influence of steroid hormones and immunosuppressive agents on autoimmune expression in lacrimal glands of a female mouse model of Sjogren's syndrome. *Investig. Ophthalmol. Vis. Sci.* 35:2632-2642.
 26. Pozzilli, P., A. Signore, A.J. Williams, and P.E. Beales. 1993. NOD mouse colonies around the world—recent facts and figures. *Immunol. Today.* 14:193-196.
 27. Faveeuw, C., M.C. Gagnerault, and F. Lepault. 1994. Expression of homing and adhesion molecules in infiltrated islets of Langerhans and salivary glands of nonobese diabetic mice. *J. Immunol.* 152:5969-5978.
 28. Bedossa, P., A. Bendelac, J.F. Bach, and C. Carnaud. 1989. Syngeneic T cell transfer of diabetes into NOD newborn mice: in situ studies of the autoimmune steps leading to insulin-producing cell destruction. *Eur. J. Immunol.* 19: 1947-1951.
 29. Yang, S.K., L. Eckmann, A. Panja, and M.F. Kagnoff. 1997. Differential and regulated expression of C-X-C, C-C, and C-chemokines by human colon epithelial cells. *Gastroenterology.* 113:1214-1223.
 30. Toda, I., and D.A. Sullivan. 1996. Gender- and androgen-related influence on the expression of Fas antigen, bcl-2, C-MYC, C-MYB and p53 mRNA in lacrimal tissues of autoimmune and non-autoimmune mice. *Investig. Ophthalmol. Vis. Sci.* 37(Suppl.):856.
 31. Rocha, E.M., I. Toda, L.A. Wickham, L.A. da Silveira, and D.A. Sullivan. 1997. Influence of gender, androgens and cyclophosphamide on cytokine mRNA levels in lacrimal tissue of a mouse model of Sjogren's syndrome. *Investig. Ophthalmol. Vis. Sci.* 38(Suppl.):443.
 32. Toda, I., L.A. Wickham, and D.A. Sullivan. 1995. Proto-oncogene and Fas antigen mRNA expression in lacrimal glands of the female, MRL/Mp-Lpr/lpr mouse model of Sjogren's syndrome. *Investig. Ophthalmol. Vis. Sci.* 36(Suppl.):991.
 33. Pflugfelder, S.C., C.A. Crouse, D. Monroy, M. Yen, M. Rowe, and S.S. Atherton. 1993. Epstein-Barr virus and the lacrimal gland pathology of Sjogren's syndrome. *Am. J. Pathol.* 143:49-64.
 34. Hoffman, R.W., M.A. Alspaugh, K.S. Waggle, J.B. Durham, and S.E. Walker. 1984. Sjogren's syndrome in MRL/l and MRL/n mice. *Arthritis Rheum.* 27:157-165.
 35. Pepose, J.S., R.F. Akata, S.C. Pflugfelder, and W. Voigt. 1990. Mononuclear cell phenotypes and immunoglobulin gene rearrangements in lacrimal gland biopsies from patients with Sjogren's syndrome. *Ophthalmology.* 97: 1599-1605.
 36. Asamoto, H., Y. Akazawa, S. Tashiro, M. Oishi, T. Azuma, S. Koide, K. Sudo, H. Yokota, and Y. Tochino. 1984. Infiltration of lymphocytes in various organs of the NOD (non-obese diabetic) mouse. *J. Jpn. Diabetic Soc.* 27:775-781.
 37. Adamson, T.C., R.I. Fox, D.M. Frisman, and F.V. Howell. 1983. Immunohistologic analysis of lymphoid infiltrates in primary Sjogren's syndrome using monoclonal antibodies. *J. Immunol.* 130:203-208.
 38. Duke, O., G.S. Panayi, G. Janosy, and L.W. Poulter. 1982. An immunohistological analysis of lymphocyte subpopulation and their microenvironment in the synovial membranes of patients with rheumatoid arthritis using monoclonal antibodies. *Clin. Exp. Immunol.* 49:22.
 39. Sullivan, D.A., and J.A. Edwards. 1997. Androgen stimulation of lacrimal gland function in mouse models of Sjogren's syndrome. *J. Steroid Biochem. Mol. Biol.* 60:237-245.
 40. Tisch, R., X.-D. Yang, S.M. Singer, R.S. Liblau, L. Fugger, and H.O. McDevitt. 1993. Immune response to glutamic acid decarboxylase correlates with insulinitis in non-obese diabetic mice. *Nature.* 366:72-75.
 41. Kaufmann, D.L., M. Clare-Salzler, J. Tian, T. Forsthuber, G.S.P. Ting, P. Robinson, M.A. Atkinson, E.E. Sercarz, A.J. Tobin, and P.V. Lehmann. 1993. Spontaneous loss of T-cell tolerance to glutamic acid decarboxylase in murine insulin-dependent diabetes. *Nature.* 366:69-75.
 42. Roubinian, J.R., R. Papoian, and N. Talal. 1977. Androgenic hormones modulate autoantibody responses and improve survival in murine lupus. *J. Clin. Invest.* 59:1066-1071.
 43. Garchon, H.J., P. Bedossa, L. Eloy, and J.F. Bach. 1991. Identification and mapping to chromosome 1 of a susceptibility locus for periinsulinitis in non-obese diabetic mice. *Nature.* 353:260-262.