

Expression of Transforming Growth Factor- β 1 in Dystrophic Patient Muscles Correlates with Fibrosis

Pathogenetic Role of a Fibrogenic Cytokine

Pia Bernasconi, Elena Torchiana, Paolo Confalonieri, Raffaella Brugnoli, Rita Barresi, Marina Mora, Ferdinando Cornelio, Lucia Morandi, and Renato Mantegazza

Department of Neuromuscular Diseases "C. Besta" National Neurological Institute, Milan, Italy 20133

Abstract

Duchenne muscular dystrophy is a fatal disorder characterized by progressive muscular weakness, wasting, and severe muscle contractures in later disease stages. Muscle biopsy reveals conspicuous myofiber degeneration and fibrosis substituting muscle tissue. We quantitatively determined mRNA of the potent fibrogenic cytokine transforming growth factor- β 1 by quantitative PCR in 15 Duchenne muscular dystrophy, 13 Becker muscular dystrophy, 11 spinal muscular atrophy patients, and 16 controls. Higher transforming growth factor- β 1 expression was greater in Duchenne muscular dystrophy patients than controls ($P = 0.012$) and Becker patients ($P = 0.03$). Fibrosis was significantly more prominent in Duchenne muscular dystrophy than Becker muscular dystrophy, spinal muscular atrophy, and controls. The proportion of connective tissue in muscle biopsies increased progressively with age in Duchenne muscular dystrophy patients, while transforming growth factor- β 1 levels peaked at 2 and 6 yr of age. Transforming growth factor- β 1 protein was also detected by immunocytochemistry and immunoblotting. Our findings suggest that transforming growth factor- β 1 stimulates fibrosis in Duchenne muscular dystrophy. Expression of transforming growth factor- β 1 in the early stages of Duchenne muscular dystrophy may be critical in initiating muscle fibrosis and antifibrosis treatment could slow progression of the disease, increasing the utility of gene therapy. (*J. Clin. Invest.* 1995; 96:1137–1144.) Key words: transforming growth factor- β 1 • Duchenne muscular dystrophy • Becker muscular dystrophy • fibrosis • polymerase chain reaction

Address correspondence to Renato Mantegazza, Department of Neuromuscular Diseases, "C. Besta" National Neurological Institute, Via Celoria 11, Milan, 20133, Italy. Phone: 39-2-2394282; FAX: 39-2-70633874.

Received for publication 14 December 1994 and accepted in revised form 6 April 1995.

1. Abbreviations used in this paper: bFGF, basic fibroblast growth factor; BMD, Becker muscular dystrophy; DMD, Duchenne muscular dystrophy; Q-PCR quantitative PCR; SMA, spinal muscular atrophy; TGF- β 1, transforming growth factor- β 1.

J. Clin. Invest.

© The American Society for Clinical Investigation, Inc.
0021-9738/95/08/1137/08 \$2.00

Volume 96, August 1995, 1137–1144

Introduction

Duchenne muscular dystrophy (DMD)¹ is an X-linked recessive disease, affecting 1 in every 3,500 males in all populations. Progressive muscular weakness and wasting confine DMD patients to a wheelchair before the age of 15 and the disease terminates fatally around the end of the second decade (1, 2). The severe DMD phenotype is caused by mutations in the dystrophin gene (3), which lead to the absence of the cytoskeletal protein dystrophin (427 kD), normally localized at the cytoplasmic face of the sarcolemma of skeletal muscle fibers (4). Characteristic histological findings in DMD are degeneration of fibers due to segmental necrosis, regeneration, and excessive connective tissue proliferation (5). After the discovery of dystrophin (4), the most favored explanation for the muscle degeneration was that focal discontinuities in the dystrophin-deficient membrane led, under specific conditions, to abnormal intracellular Ca^{2+} influx resulting in segmental myofiber destruction (6, 7).

A proportion of samples from DMD muscles shows a mononuclear cell infiltrate consisting of macrophages, T lymphocytes, and natural killer/killer cells (8, 9). Gorospe et al. have recently reported large numbers of mast cells at the endomysium of dystrophic muscle, in the same area as grouped necrosis, suggesting that mast cell degranulation plays a role in inducing myofiber death (10, 11).

Myofiber degeneration is followed by muscle fibrosis, predominantly composed of type III collagen and involving the endomysium and perimysium (12). Fibrosis may be evident at the early stage and progresses with the disease.

Transforming growth factor- β 1 (TGF- β 1) is a multifunctional protein (13) which plays an important role in inflammation (14–16), in wound healing, and fibrosis (17). Studies on lung fibrosis (18) and liver cirrhosis (19) (both chronic, progressive, and fatal organ diseases) have shown that high levels of TGF- β 1 are present at sites of extracellular matrix expansion. The aim of the present study was to determine whether TGF- β 1 mRNA was expressed in Xp21 dystrophy muscles, and to relate its expression to patient age and degree of connective tissue proliferation.

Methods

15 DMD and 13 Becker muscular dystrophy (BMD) patients were diagnosed on the basis of clinical, histological, immunological, and genetical criteria (20). Controls were also studied as were 11 spinal muscular atrophy (SMA) patients (seven type I, and four type III), and 16 other subjects, who had undergone muscle biopsy for diagnosis but

combined clinical, electromyographic, and histological criteria revealed that they were free of muscle disease. Muscle samples, obtained by needle biopsy, were frozen and stored in liquid nitrogen pending assays.

Quantitative-PCR (Q-PCR) analysis. An internal competitor TGF- β 1 standard was constructed as described (21). Total RNA was extracted from muscle biopsies by the acid guanidinium-thiocyanate-phenol-chloroform extraction method (22). 5 μ g of total RNA was reverse transcribed in the presence of 1 \times PCR buffer (Finnzymes, Oy, Finland), 1 mM each deoxynucleoside triphosphate (dNTP) (Perkin-Elmer Corp., Norwalk, CT), 8 pmol/ μ l random hexamers (Pharmacia Biotech, Uppsala, Sweden), 1 U/ μ l RNase inhibitor (Boehringer Mannheim GmbH, Mannheim, Germany) and 10 U/ μ l of Moloney murine leukemia virus (M-MLV) reverse transcriptase (Gibco Laboratories, Grand Island, NY). The reaction mixture was incubated at room temperature for 10 min, at 37°C for 1 h, at 95°C for 5 min, and then stored at -20°C until PCR amplification. cDNA integrity was evaluated by amplification with β -actin specific primers (forward: 5' CAGGATTTAAAACTGGA-ACGGT-3'; reverse: 5'-GGAATGACTATTAATAAAAAACAACA-3'). A constant amount of cDNA (corresponding to 200 ng of total RNA) was coamplified with known concentrations of the internal competitor in 50 μ l of PCR mixture containing 1 \times PCR buffer (Finnzymes), 200 μ M each dNTP (Perkin-Elmer Corp.), 1 μ M TGF- β 1 specific primer and 2 U DynaZyme DNA polymerase (Finnzymes). Amplification was performed with 32 cycles: 94°C for 1 min, 55°C for 1 min, and 72°C for 1 min. To test the reproducibility of Q-PCR protocol, the cDNA was amplified several times. PCR products (20 μ l) were resolved on 2% agarose gel stained with ethidium bromide. Fluorescence of both target and competitor products was quantitated (as absorbance) by a densitometer which uses the BIO-PROFIL software system (Vilber-Lourmat, Tozcy, France). The absorbance ratio (target/competitor) was plotted against known concentrations of competitor. The amount of TGF- β 1-specific mRNA was determined by the equation obtained from the regression curve of the plotted values. The results were expressed as femtograms of TGF- β 1 mRNA/200 ng total RNA (see Fig. 2).

Quantitative analysis of connective tissue. Quantitative evaluation of intramuscular connective tissue was performed on hematoxylin and eosin-stained muscle transverse sections, as described (23). The area corresponding to the image obtained on a video connected to a light microscope at a magnification of 6 was adopted as unit area for the calculations. Within this area, connective tissue was outlined by a digitizer linked to a computer and its area measured as the percentage of the total area using Image Measure[®] software (Microscience Inc., Federal Way, WA). In patients and controls, a mean of five areas (range four–eight) of the muscle biopsy slide were analyzed and the total amount of fibrosis was expressed as the mean of that found in all areas.

Immunocytochemistry. Immunohistochemical analysis of TGF- β 1 was performed in seven DMD, three BMD, three SMA patients, and six controls. TGF- β 1 was detected by immunofluorescence on 6- μ m thick unfixed cryostat sections, which were incubated with mouse monoclonal antibody to human TGF- β 1 (Serotec Ltd., Oxford, United Kingdom) for 2 h, washed three times in PBS, followed by a 60-min incubation with the secondary biotinylated horse anti-mouse IgG (Vector Laboratories Inc., Burlingame, CA). After three more rinses in PBS, rhodamine-avidin D (Vector Laboratories Inc.) was applied for 60 min. Incubations were performed in a humid chamber at room temperature. On adjacent sections the primary antibody was omitted as control. Sections were mounted with a glycerol-based medium containing *p*-phenylenediamine and observed in a microscope. (Carl Zeiss, Inc., Thornwood, NY). Serial hematoxylin and eosin-stained sections were obtained to correlate monoclonal antibody TGF- β 1 localization with tissue histology.

Cell culture. PBLs were isolated by centrifugation at 22°C for 30 min at 400 *g* on Ficoll-Paque gradient (Pharmacia Biotech). Cells were resuspended and cultured as 2 \times 10⁶ cells/well in 24-well plate (Costar Corp., Cambridge, MA) in RPMI 1640 medium supplemented with 10% FCS (Hyclone Laboratories Inc., Logan, UT), 50 ng/ml PHA (Wellcome Diagnostics, Dartford, United Kingdom), 100 IU/ml penicillin, 100 μ g/ml streptomycin. After 2 d the medium was replaced with

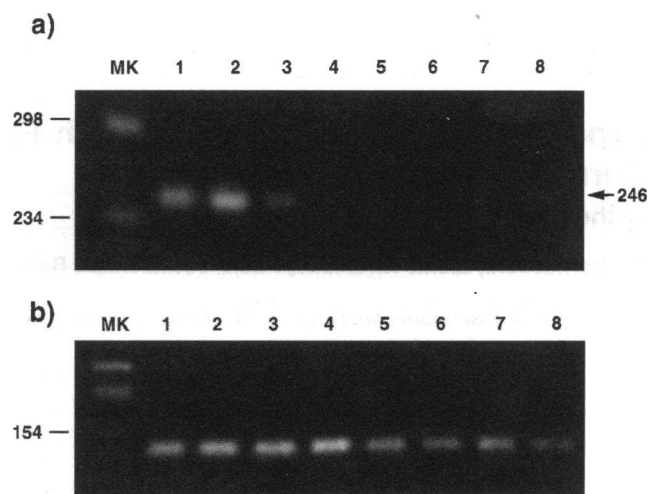


Figure 1. Detection of (a) TGF- β 1 (246 bp) and (b) actin (120 bp) mRNA amplified by RNA-PCR in muscle tissue. PCR products were resolved on 2% agarose gel, stained with ethidium bromide. MK, Mixture of fragments from cleavage of pBR328 DNA with restriction endonuclease Bgl I and of pBR328 with restriction endonuclease Hinf I. Lanes 1 and 2: DMD; 3 and 4: BMD; 5 and 6: SMA; 7 and 8: control.

serum-free RPMI 1640 in the presence of PHA. Cells were harvested 48 h later and the supernatants also collected.

Immunoblotting analysis. Muscle samples (10–15 mg) were homogenized, resuspended in 100 μ l 0.1 M Tris, pH 6.8, and centrifuged for 15 min at 10,000 \times *g* to remove insoluble material. The PBL-supernatants were concentrated to 300 μ l using Centricon 10 (Amicon Corp., Beverly, MA). Muscle and PBL supernatants (50 μ l) were transferred onto nitrocellulose membrane by slot blot apparatus (Bio-Rad Laboratories, Richmond, CA). Membranes were blocked for 30 min with 5% (wt/vol) nonfat dried milk in a buffer (TBST) containing 10 mM Tris-HCl pH 8.0, 0.9% (wt/vol) NaCl and 0.5% (vol/vol) Tween 20, and then incubated for 1 h at room temperature with mouse monoclonal antibody anti-TGF- β (Genzyme Corp., Cambridge, MA) diluted 1:1,000 in TBST (24). Primary antibody binding was revealed using an anti-mouse IgG antibody labelled with alkaline phosphatase.

Statistical analysis. Data are presented as mean \pm SD. Values were compared using the one-tailed Student's *t* test.

Results

TGF- β 1 mRNA was detected by RNA-PCR in muscle samples from all DMD, BMD, and SMA patients as well as from normal controls (Fig. 1 a). The cDNA samples were also used to detect actin transcripts as check for successful PCR amplification (Fig. 1 b). The intensity of actin transcript staining was similar in all samples, while the intensity of TGF- β 1 transcript staining was variable. We therefore decided to quantify TGF- β 1 mRNA expression using Q-PCR. Fig. 2 shows a Q-PCR gel for a DMD muscle sample (Fig. 2 a) along with a representative plot used to determine the amount of TGF- β 1-specific mRNA (Fig. 2 b). We found higher quantities of TGF- β 1 in DMD (mean 16.7 \pm 25.4 fg/200 ng total RNA) than in BMD, SMA, and control muscles (Fig. 3 a). In all SMA patients TGF- β 1 transcripts were barely quantifiable, and in controls they were sometimes undetectable by the Q-PCR technique. DMD TGF- β 1 values were significantly different from controls ($P = 0.012$), BMD ($P = 0.03$), and SMA ($P = 0.0157$) on statistical analysis. The high standard deviation of TGF- β 1 concentration in

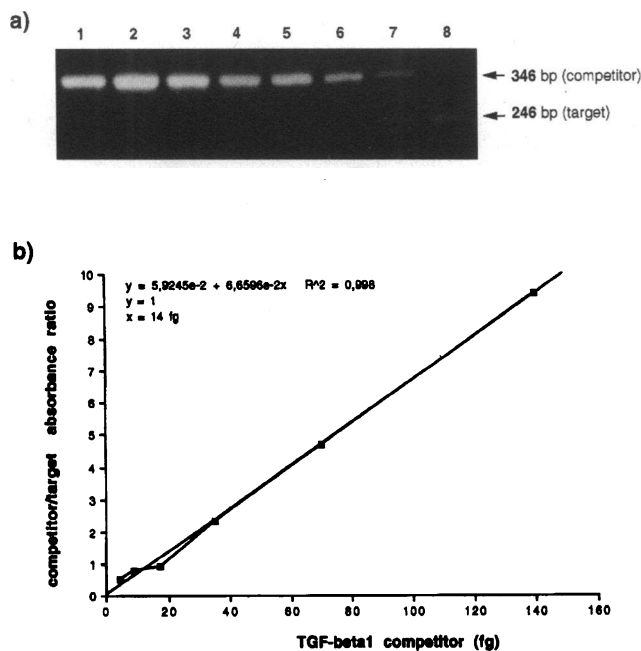


Figure 2. Q-PCR of TGF- β 1 transcript. (a) PCR product derived from competitor (upper band 346 bp) and target sequence (lower band, 246 bp), resolved on ethidium bromide stained 2% agarose gel. Lanes 1–7 are 140, 70, 35, 17.5, 8.75, 4.38, 2.19 fg of competitor per reaction, respectively. Lane 8 shows PCR amplification of target sequence without competitor. (b) A representative plot used to determine the amount of target sequence in the specimens.

the DMD group was due to a very high level from a single patient (103.6 fg/200 ng total RNA). When this high value was discounted, the mean \pm SD of the TGF- β 1-specific mRNA in DMD was 10.5 ± 8.4 ; still significantly different from controls ($P = 0.0002$), BMD ($P = 0.0035$), and SMA patients ($P = 0.0005$).

The results of the analysis of connective tissue proliferation in muscle are presented in Fig. 3 b. The proportion of connective tissue in muscle samples was higher in DMD patients than in BMD or SMA patients, and controls (statistical data given in legend to Fig. 3 b).

After grouping the patients according to age at biopsy (< 2 yr, between 2 and 6 yr, and 7 or more yr), levels of TGF- β 1 and connective tissue proliferation were compared. In DMD the proportional connective tissue in muscle increased progressively with age, while TGF- β 1 levels peaked between 2 and 6 yr (Fig. 4 a). In BMD the trends for connective tissue proliferation and TGF- β 1 levels were similar to those in DMD, but absolute values were lower (Fig. 4 b). In SMA patients there was a progressive increase in connective tissue proliferation but variation in TGF- β 1 levels were not significant (Fig. 4 c).

In all DMD patients, TGF- β 1 positive immunostaining was observed in thickened and fibrotic perimysial connective tissue branches. TGF- β 1 positivity was also detected in circumscribed areas of the endomysial connective tissue. Rarely, in areas corresponding to endomysial positivity, few mononuclear cells were observed on hematoxylin and eosin-stained adjacent sections (Fig. 5). TGF- β 1 positivity, exclusively localized in the perimysial connective tissue, was also observed in BMD and SMA patient muscle, while normal control muscle did not show any TGF- β 1 positivity (data not shown).

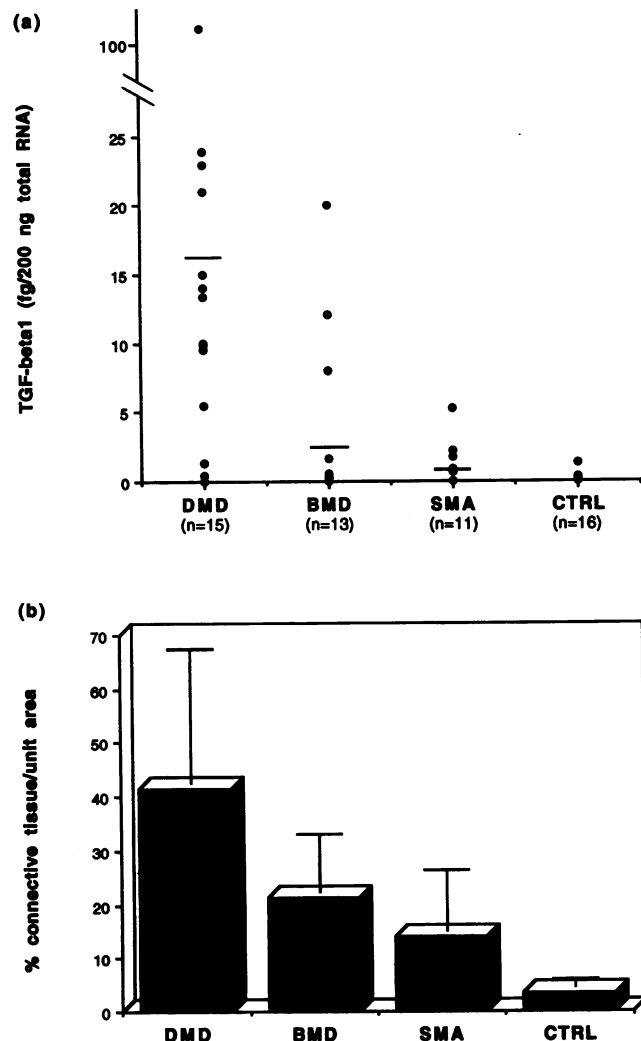


Figure 3. Quantitation of (a) TGF- β 1 transcript and (b) extent of connective tissue in muscle tissue. TGF- β 1, expressed in fg/200 ng of total RNA, was measured by the Q-PCR technique, all obtained values were reported. Extent of connective tissue, expressed as percentage per unit area, was determined by image analysis and values were plotted as means \pm SD. CTRL, control. Statistical analysis was performed by one-tailed Student's *t* test: DMD TGF- β 1 mRNA level vs controls $P = 0.012$, vs BMD $P = 0.03$, and vs SMA $P = 0.0157$. DMD connective tissue proliferation vs controls $P = 0.0001$, vs BMD = 0.005, and vs SMA $P = 0.0006$.

TGF- β 1 expression was also tested with immunoblot using a monoclonal antibody directed against the active form. The strongest signal was seen in DMD muscle; however, a positive spot was also seen in BMD and SMA, whereas in normal controls the active TGF- β 1 signal was insubstantial (Fig. 6). Supernatants from PBLs, cultured in serum-free media in the presence of PHA, were positive on blots and served as positive controls.

Discussion

Connective tissue proliferation in muscles is a major characteristic of DMD patients and is considered to be secondary to the degeneration of muscle tissue. The phenomenon may be viewed as a pivotal event in the dystrophic process since it leads to

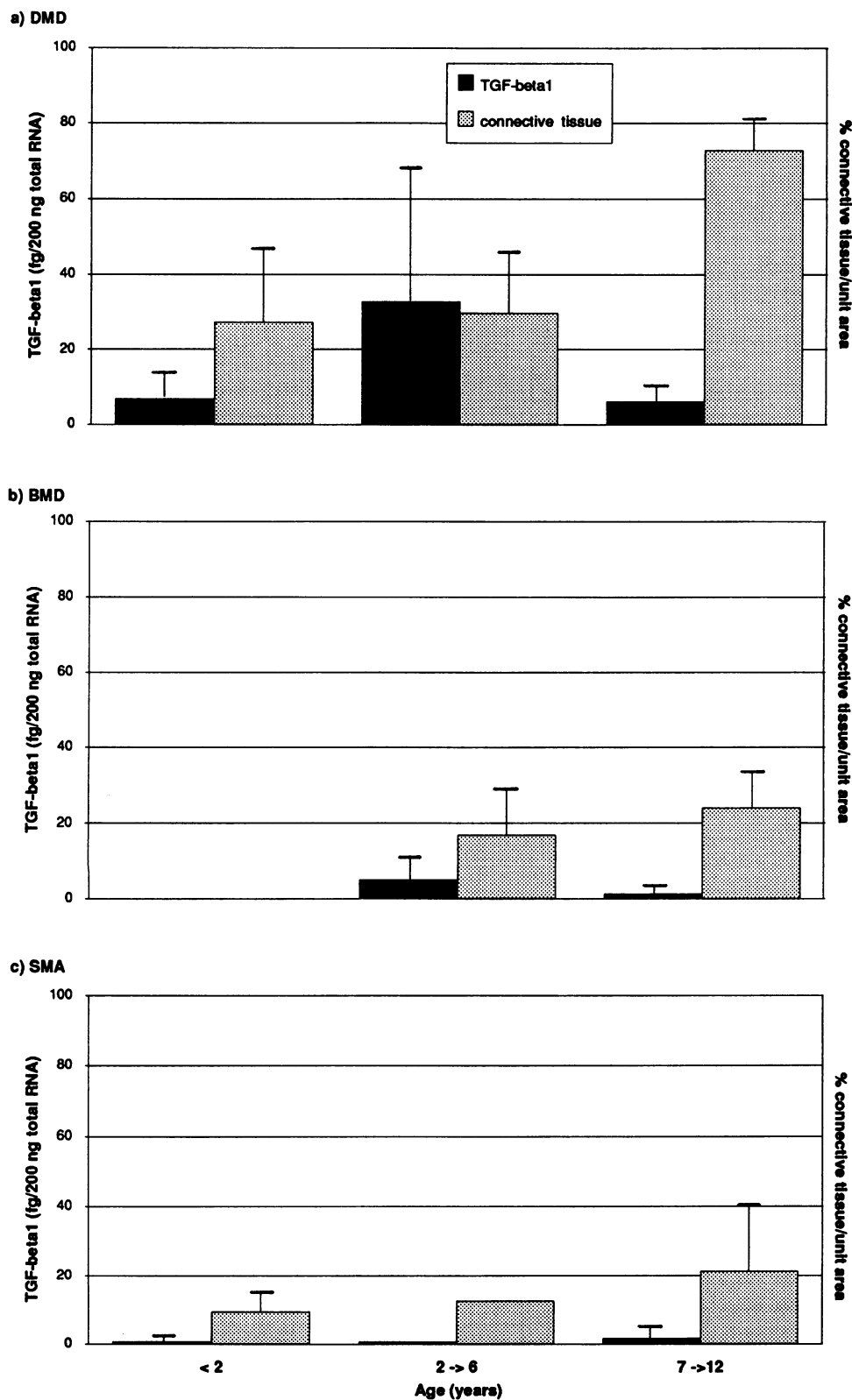


Figure 4. TGF- β 1 and connective tissue proliferation according to age: (a) DMD, (b) BMD, and (c) SMA patients, (control data not shown). Values plotted as means \pm SD.

irreversible derangement of muscle tissue organization (2, 5, 12). Fibrosis hinders nutritional support of myofibers, particularly in the advanced stages when they become physically isolated from blood supply (2). This stage correlates with development of muscular contractures (2). Connective tissue prolifera-

tion is a feature of several diseases including liver cirrhosis, glomerulonephritis, idiopathic lung fibrosis, and systemic sclerosis in which excessive development of fibrotic tissue correlates with disease irreversibility (for a recent review see reference 25). In these pathologies focal release of fibrogenic cyto-

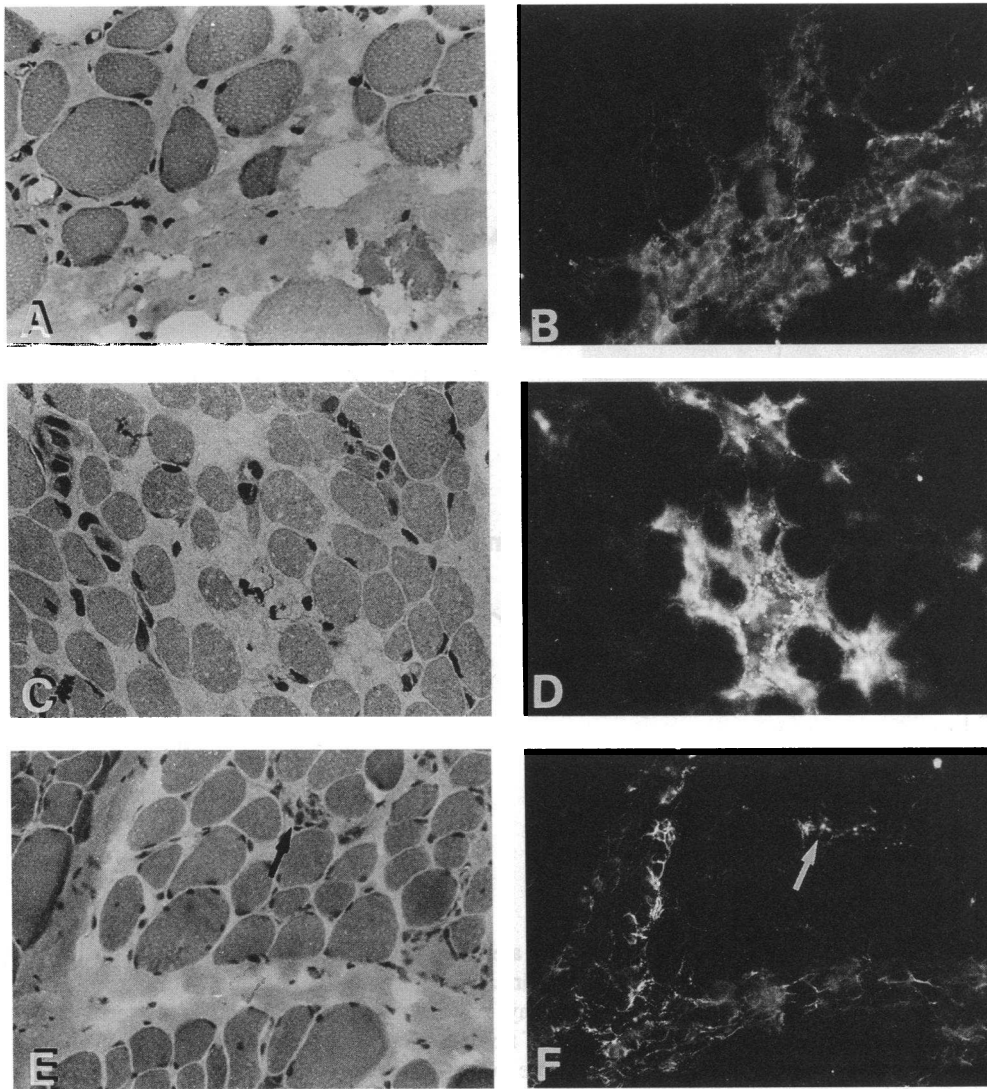


Figure 5. Hematoxylin and eosin staining (A, C, and E) and TGF- β 1 (B, D, and F) immunolocalization in three DMD patient muscles. TGF- β 1 positivity is mainly localized in the perimysium (B, and F), sometimes in the endomysium (D) and, rarely, in endomysial areas with mononuclear cells (arrow). $\times 400$.

kines is known to be a key element in collagen synthesis and fibroblast proliferation (26). Although TGF- β 1 gene is up-regulated in response to tissue injury and thought to be the cytokine most implicated in fibrosis (25, 27, 28), other cytokines, including platelet-derived growth factor, basic fibroblast growth factor (bFGF), tumor necrosis factor and interleukin-1, probably exert synergistic or coordinated effects on development of fibrosis.

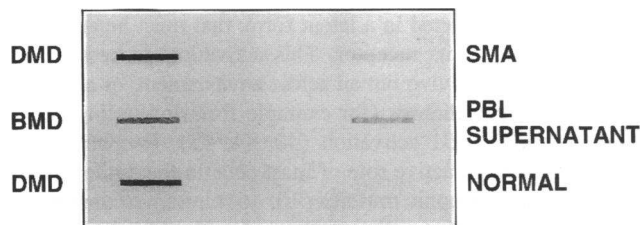


Figure 6. Slot blot of TGF- β protein present in muscle tissue probed with anti-TGF- β monoclonal antibody under nonreducing conditions (24). PBL supernatant was used as positive control.

However, it seems that TGF- β 1 alone is able to promote increased extracellular matrix deposition (15, 29). Many different cell types are able to produce TGF- β 1 (for example, platelets, lymphocytes, and macrophages) and it may have various and opposing effects on target cells (30, 31). Thus TGF- β 1 can inhibit C₂C₁₂ and P₂ muscle cell culture differentiation and stimulates L₆E₉ muscle cell cultures to differentiate (32).

Yamazaki et al. reported that TGF- β 1 and latent TGF- β binding protein were detectable at the endomysium of dystrophic muscles (33). We have now studied the expression of TGF- β 1 at the molecular level and have correlated its expression with dystrophic muscle fibrosis. We have detected TGF- β 1 transcripts by RNA-PCR method, which is 1,000-10,000 times more sensitive than northern blotting (34). Such transcripts were found in all muscle samples including controls (Fig. 1). We then quantified TGF- β 1 transcript levels using Q-PCR (21, 35). We found that TGF- β 1 transcript concentration in DMD muscle was significantly greater than in controls ($P = 0.012$) and BMD patients ($P = 0.0316$) (Fig. 3 a). In one 5-yr-old DMD patient TGF- β 1 levels were particularly high (103.6 fg/200 ng total RNA) and may be related to his severe

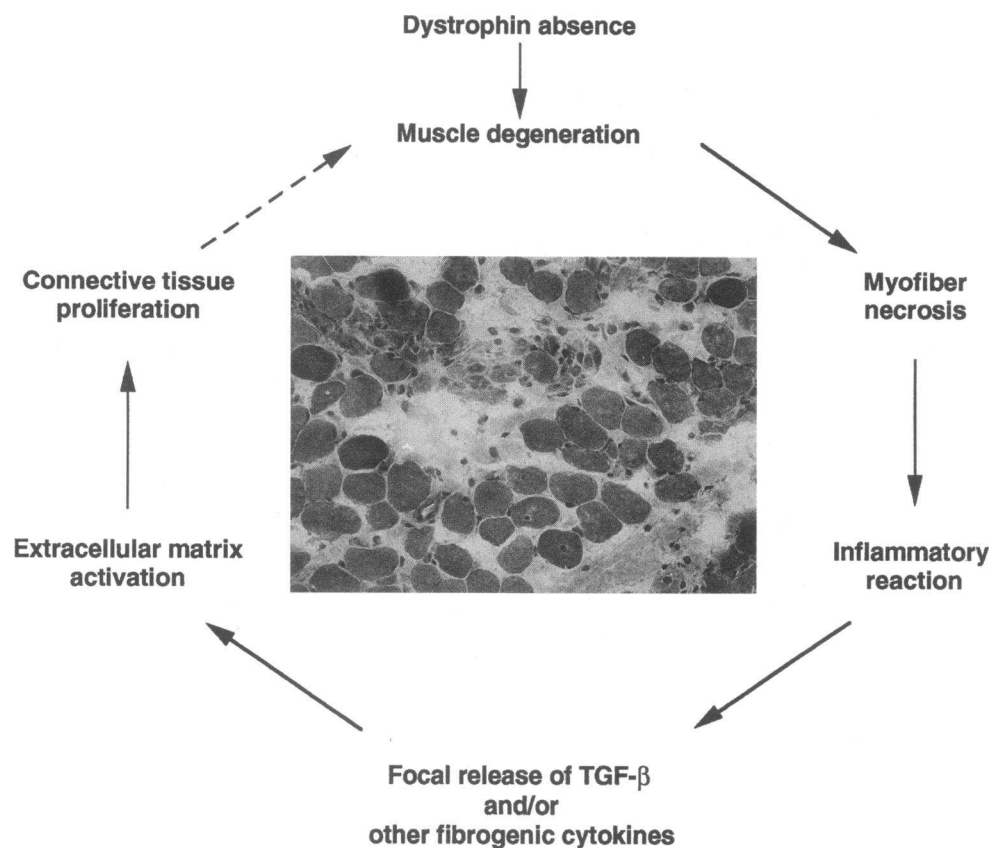


Figure 7. Model for self-perpetuating TGF- β 1 mediated connective tissue proliferation in DMD muscles.

neuromuscular functional impairment and advanced muscle degeneration (43% fibrosis and high levels of degeneration/regeneration), both unusual in such a young patient. Presence of TGF- β 1 transcript suggests ongoing in situ synthesis of TGF- β 1 in DMD muscles, which correlates with the greater proportion of connective tissue in the muscle of these patients compared to BMD, SMA, and control subjects' muscles (Fig. 3 b). It is known that TGF- β 1 femtomolar concentrations are strongly chemotactic for neutrophils, T cells, monocytes and fibroblasts; these cells may become activated and produce their own TGF- β 1, thus amplifying its fibrotic effect (25, 29).

D'Amore et al. reported that serum levels of bFGF, another fibrogenic cytokine, were significantly increased in 61% of DMD patients, all of whom fell in the 4–9 yr age group, suggesting that bFGF is involved in the pathogenesis of muscular dystrophy (36). We have found that TGF- β 1 levels increased with age up to 6 yr and afterwards declined to very low levels, while connective tissue proliferation continued to increase (Fig. 4 a). This trend is similar to that D'Amore reported for bFGF (36). Thus both these cytokines are expressed in the early stages of fibrosis and we conjecture that they are involved in this process, while in later stages of DMD, fibrosis may be perpetuated by other mediators or by autocrine processes, as is the case in hepatic fibrosis (37).

It has been reported that TGF- β 1 mRNA is constitutively expressed in monocytes but only after their activation do these cells secrete the TGF- β 1 protein, suggesting a crucial posttranscriptional regulation of protein expression (38). It should be emphasized that in DMD, mononuclear cell infiltrates, composed of macrophages, activated T lymphocytes and natural

killer cells, are occasionally observed, mainly at the site of endomysial inflammation (8, 9, 39). At these sites, the infiltrating cells may be partially responsible for local secretion or activation of fibrogenic cytokines (13, 16), including TGF- β 1, which is able to up-regulate its own synthesis (40). Our results show that TGF- β 1 is present in the endomysium of DMD muscles; and that this localization differs from that found in BMD and SMA, where TGF- β 1 is located in the perimysium. Our findings confirm, therefore, Yamazaki et al.'s report of TGF- β 1 in the endomysium (33) but not in the muscle fibers; these authors used paraffin-embedded sections, whereas we examined frozen material.

After an initial stimulatory effect on inflammatory cells, TGF- β 1 exerts an antiinflammatory action, inhibiting synthesis of TNF- α and IL-1 (41, 42). On a cytokine profile examination of DMD muscles we were not able to detect, by RNA-PCR, IL-1 α transcripts, while TNF- α transcripts were detected in a minority (23%) of patients (43): this is consistent with an immunosuppressant activity of TGF- β 1.

TGF- β 1 is secreted in a latent form, that must be activated before binding to its receptor. This activation process is not well understood in vivo but an acidic environment, or a release of proteases or sialidases (for example from infiltrating cells) may trigger TGF- β 1 activation (40, 44, 45). Recent studies have suggested an active role of mast cells in the pathogenesis of fibrosis in dystrophic muscles (10, 46): intramuscular injections of purified mast cell granules induced widespread myofiber necrosis in dystrophin-negative mdx mice, but not in normal mice (11). Mast cells, which are interspersed within muscle tissue, can be activated by physical (heat, cold, irradiation) and

chemical agents (for example Ca^{2+} , anaphylatoxins, lectins) (10), and release granules containing proteases and cytokines, which induce effector cell recruitment or their activation. Recruited cells may promote connective tissue proliferation by secretion of additional cytokines (e.g., TGF- β 1) increasing the fibrotic process (46).

Based on our findings, we propose a model for TGF- β 1-mediated fibrosis in DMD, outlined in Fig. 7. Muscle degeneration, secondary to dystrophin absence, is followed by myofiber necrosis. An inflammatory reaction may take place and may lead to focal release of TGF- β 1 and other fibrogenic cytokines. TGF- β 1 release may trigger activation of extracellular matrix and this would lead to connective tissue proliferation. Fibrosis may further worsen muscle degeneration. In conclusion, our results indicate that TGF- β 1 is actively involved in connective tissue proliferation in DMD muscle and that its maximal production is age related, preceding the severe muscle organizational derangement that occurs later.

Furthermore, our findings support the idea that an early antifibrotic treatment in dystrophic patients may prevent or limit the proliferation of the connective tissue in their muscles. A similar conclusion was drawn by Gorospe et al. (10) in their analysis of mast cell involvement in dystrophic muscle degeneration. An antifibrotic approach has been successful in the kidney, skin, lung, brain, joint, and arterial wall fibrotic diseases (47–53). In this regard we note that empirical treatment of DMD patients with steroids (54) or cyclosporine A (55) has produced a slight and transient improvements of muscle strength which may be related, at least in part, to an effect on inflammation-related release of fibrogenic cytokines. However, it should be remembered that cyclosporine A in vitro increases TGF- β 1 mRNA expression even though an immunosuppressive effect is exerted ultimately (21). Finally, we note that the presence of an active fibrogenic process in dystrophic muscles may render therapy for the replacement of dystrophin less feasible and less effective.

Acknowledgements

We thank Drs. F. Dworzak and C. Antozzi for performing the muscle biopsies, S. Daniel and F. Blasevich for technical assistance, Drs. S. DiDonato and B. Colombo for facilitating densitometric analysis, Dr. R. Spreafico for facilitating fibrosis analysis, E. Ronchi and Dr. A. Biffi (National Cancer Institute, Milan) for advice on the slot blot analysis, and D. Ward for help with the English.

This work was partially supported by Telethon, Italy and by Ministry of Health grants to F. Cornelio.

References

- Emery, A. E. H. 1987. Duchenne muscular dystrophy. In Oxford Monographs on Medical Genetics. P. Harper and M. Bobrow, editors. Oxford University Press, Oxford. 71–91.
- Engel, A. G., M. Yamamoto, and K. H. Fischbeck. 1994. Dystrophinopathies. In Myology, A. G. Engel and C. Franzini-Armstrong, editors. McGraw-Hill Inc. New York. 1133–1187.
- Koenig, M., A. H. Beggs, M. Moyer, S. Scherpf, K. Heindrich, T. Bettecken, G. Meng, C. R. Muller, M. Lindlöf, H. Käariäinen, et al. 1989. The molecular basis for Duchenne versus Becker muscular dystrophy: correlation of severity with type of deletion. *Am. J. Hum. Genet.* 45:498–506.
- Hoffman, E. P., R. H. Brown, and L. M. Kunkel. 1987. Dystrophin: the protein product of the Duchenne muscular dystrophy locus. *Cell.* 51:919–928.
- Dubowitz, V. 1985. The muscular dystrophy. In *Muscle Biopsy: A Practical Approach*. Bailliere Tindall, East Sussex United Kingdom. 289–404.
- Cornelio, F., and I. Dones. 1984. Muscle fiber degeneration and necrosis

in muscular dystrophy and other muscle diseases: cytochemical and immunocytochemical data. *Ann. Neurol.* 16:694–701.

7. Morandi, L., M. Mora, E. Gussoni, S. Tedeschi, and F. Cornelio. 1990. Dystrophin analysis in Duchenne and Becker muscular dystrophy carriers: correlation with intracellular calcium and albumin. *Ann. Neurol.* 28:674–679.

8. McDouall, R. M., M. J. Dunn, and V. Dubowitz. 1990. Nature of the mononuclear infiltrate and the mechanism of muscle damage in juvenile dermatomyositis and Duchenne muscular dystrophy. *J. Neurol. Sci.* 99:199–217.

9. Arahata, K., and A. G. Engel. 1984. Monoclonal antibody analysis of mononuclear cells in myopathies. I. Quantitation of subsets according to diagnosis and sites of accumulation and demonstration and counts of muscle fibers invaded by T cells. *Ann. Neurol.* 16:193–208.

10. Gorospe, J. R. M., M. D. Tharp, J. Hinckley, J. N. Komegay, and E. P. Hoffman. 1994. A role for mast cells in the progression of Duchenne muscular dystrophy? Correlations in dystrophin-deficient humans, dogs and mice. *J. Neurol. Sci.* 122:44–56.

11. Gorospe, J. R. M., M. D. Tharp, T. Demitsu, and E. P. Hoffman. 1994. Dystrophin-deficient myofibers are vulnerable to mast cell granule-induced necrosis. *Neuromus. Disord.* 4:325–333.

12. Duance, V. C., H. R. Stephens, M. Dunn, A. J. Bailey, and V. Dubowitz. 1980. A role for collagen in the pathogenesis of muscular dystrophy? *Nature (Lond.)* 284:470–472.

13. Wahl, S. M. 1994. Transforming growth factor β : the good, the bad, and the ugly. *J. Exp. Med.* 180:1587–1590.

14. Wahl, S. M., N. McCartney-Francis, and S. E. Mergenhagen. 1989. Inflammatory and immunomodulatory roles of TGF- β . *Immunol. Today.* 8:258–261.

15. Roberts, A. B., and M. B. Sporn. 1989. The transforming growth factor β s. In *The Handbook of Experimental Pharmacology. Peptide Growth Factor and Their Receptors*. M. B. Sporn and A. B. Roberts, editors. Springer-Verlag, Heidelberg, Germany. 419–472.

16. Kehrl, J. H., L. M. Wakefield, A. B. Roberts, S. Jakowlew, M. Alvarez-Mon, R. Deynck, M. B. Sporn, and A. S. Fauci. 1986. Production of transforming growth factor β by human T lymphocytes and its potential role in the regulation of T cell growth. *J. Exp. Med.* 163:1137–1150.

17. Sporn, M. B., and A. B. Roberts. 1992. Transforming growth factor- β : recent progress and new challenges. *J. Cell Biol.* 119:1017–1021.

18. Broekelmann, T. J., A. H. Limper, T. V. Colby, and J. A. McDonald. 1991. Transforming growth factor β 1 is present at sites of extracellular matrix gene expression in human pulmonary fibrosis. *Proc. Natl. Acad. Sci. USA.* 88:6642–6646.

19. Castilla, A., J. Prieto, and N. Fausto. 1991. Transforming growth factor β 1 and α in chronic liver disease. *N. Engl. J. Med.* 324:933–940.

20. Morandi, L., M. Mora, P. Bernasconi, R. Mantegazza, M. Gebbia, M. R. Balestrini, and F. Cornelio. 1993. Very small dystrophin molecule in a family with a mild form of Becker dystrophy. *Neuromusc. Disord.* 3:65–70.

21. Li, B., P. K. Sehajpal, A. Khanna, H. Vlassara, A. Cerami, K. H. Stenzel, and M. Suthanthiran. 1991. Differential regulation of transforming growth factor β and interleukin 2 genes in human T cells: demonstration by usage of novel competitor DNA constructs in the quantitative polymerase chain reaction. *J. Exp. Med.* 174:1259–1262.

22. Chomczynski, P., and N. Sacchi. 1987. Single-step method of RNA isolation by acid guanidinium thiocyanate-phenol-chloroform extraction. *Anal. Biochem.* 162:156–159.

23. Engel, A. G. 1994. Quantitative morphological studies of muscle. In *Myology*. A. G. Engel and C. Franzini-Armstrong, editors. McGraw-Hill, Inc. New York. 1018–1045.

24. Dasch, J. R., D. R. Pace, W. Waegell, D. Inenaga, and L. Ellingsworth. 1989. Monoclonal antibodies recognizing transforming growth factor- β . Bioactivity neutralization and transforming growth factor β 2 affinity purification. *J. Immunol.* 142:1536–1541.

25. Border, W. A., and N. A. Noble. 1994. Transforming growth factor β in tissue fibrosis. *N. Engl. J. Med.* 331:1286–1292.

26. Kovacs, E. J. 1991. Fibrogenic cytokines: the role of immune mediators in the development of scar tissue. *Immunol. Today.* 12:17–23.

27. Massagué, J., L. Attisano, and J. L. Wrana. 1994. The TGF- β family and its composite receptors. *Trends Cell Biol.* 4:172–178.

28. Davidson, J. M. 1992. Wound repair. In *Inflammation: Basic Principles and Clinical Correlates*. J. I. Gallin, I. M. Goldstein, and R. Snyderman, editors. Raven Press Ltd., New York. 809–819.

29. Roberts, A. B., M. E. Joyce, M. E. Bolander, and M. B. Sporn. 1990. Transforming growth factor β (TGF- β): a multifunctional effector of both soft and hard tissue regeneration. In *Growth Factors in Health and Disease: Basic and Clinical Aspects*. B. Westermark, C. Betsholtz, and B. Hökfelt, editors. Excerpta Medica, Amsterdam. 89–101.

30. Massagué, J., S. Cheifetz, M. Laiho, D. A. Ralph, F. M. B. Weiss, and A. Zentella. 1992. Transforming growth factor- β . *Cancer Surveys.* 12:81–103.

31. Barnard, J. A., R. M. Lyons, and H. L. Moses. 1990. The cell biology of TGF- β . *Biochem. Biophys. Res. Commun.* 163:56–63.

32. Zentella, A., and J. Massagué. 1992. Transforming growth factor β induces

myoblast differentiation in the presence of mitogens. *Proc. Natl. Acad. Sci. USA*. 89:5176-5180.

33. Yamazaki, M., S. Minota, H. Sakurai, K. Miyazono, A. Yamada, I. Kanazawa, and M. Kawai. 1994. Expression of transforming growth factor- β 1 and its relation to endomysial fibrosis in progressive muscular dystrophy. *Am. J. Pathol.* 144:221-226.

34. Siebert, P. D., and J. W. Larrick. 1992. Competitive PCR. *Nature (Lond.)*. 359:557-558.

35. Wang, A. M., M. V. Doyle, and D. F. Marck. 1989. Quantitation of mRNA by the polymerase chain reaction. *Proc. Natl. Acad. Sci. USA*. 86:9717-9721.

36. D'Amore, P. A., R. H. Brown, P.-T. Ku, E. P. Hoffman, H. Watanabe, K. Arahata, T. Ishihara, and J. Folkman. 1994. Elevated basic fibroblast growth factor in the serum of patients with Duchenne muscular dystrophy. *Ann. Neurol.* 35:362-365.

37. Friedman, S. L. 1993. The cellular basis of hepatic fibrosis. *N. Engl. J. Med.* 328:1828-1835.

38. Kim, S. J., K. Park, D. Koeller, K. Y. Kim, L. M. Wakefield, M. B. Sporn, and A. B. Roberts. 1992. Post-transcriptional regulation of the human transforming growth factor- β 1 gene. *J. Biol. Chem.* 267:13702-13707.

39. Mantegazza, R., F. Andreetta, J. R. Oksenberg, O. Simoncini, P. Bernasconi, M. Mora, F. Cornelio, and L. Steinman. 1993. Molecular analysis of TCR repertoire of T lymphocyte infiltrate in polymyositis: evidence for restricted TCR V α and V β rearrangements. *J. Clin. Invest.* 91:2880-2886.

40. Wahl, S. M., J. B. Allen, H. L. Wong, S. F. Dougherty, and L. R. Ellingsworth. 1990. Antagonistic and agonistic effects of transforming growth factor β and IL-1 in rheumatoid synovium. *J. Immunol.* 145:2514-2519.

41. Brandes, M. E., J. B. Allen, Y. Ogawa, and S. M. Wahl. 1991. Transforming growth factor β 1 suppresses acute and chronic arthritis in experimental animals. *J. Clin. Invest.* 87:1108-1113.

42. Shull, M. M., I. Ormsby, A. B. Kier, S. Pawlowski, R. J. Diebold, M. Yin, R. Allen, C. Sidman, G. Proetzel, D. Calvin, et al. 1992. Targeted disruption of the mouse transforming growth factor- β 1 gene results in multifocal inflammatory disease. *Nature (Lond.)*. 359:693-699.

43. Andreetta, F., P. Bernasconi, E. Torchiana, F. Baggi, F. Cornelio, and R. Mantegazza. 1994. T cell infiltration in polymyositis is characterized by co-expression of cytotoxic and T-cell activating cytokine transcripts. In *T-Cell Receptor Use in Human Autoimmune Diseases*. M. M. Davis and J. Buxbaum, editors. *Ann. NY Acad. Sci.*, New York. In Press.

44. Lyons, R. M., L. E. Gentry, A. F. Purchio, and H. L. Moses. 1990. Mechanism of activation of latent recombinant transforming growth factor β 1 by plasmin. *J. Cell. Biol.* 110:1361-1367.

45. Jullien, P., T. M. Berg, and D. A. Laurence. 1989. Acidic cellular environments: activation of latent TGF- β and sensitization of cellular responses to TGF- β and EGF. *Int. J. Cancer* 43:886-891.

46. Galli, S. J. 1993. New concepts about the mast cell. *N. Engl. J. Med.* 328:257-265.

47. Roberts, A. B., M. B. Sporn, R. K. Assoian, J. M. Smith, N. S. Roche, L. M. Wakefield, U. I. Heine, L. A. Liotta, V. Falanga, J. H. Kehrl, and A. S. Fauci. 1986. Transforming growth factor type β : rapid induction of fibrosis and angiogenesis in vivo and stimulation of collagen formation in vitro. *Proc. Natl. Acad. Sci. USA*. 83:4167-4171.

48. Border, W. A., S. Okuda, L. R. Languino, M. B. Sporn, and E. Ruoslahti. 1990. Suppression of experimental glomerulonephritis by antiserum against transforming growth factor β 1. *Nature (Lond.)*. 346:371-374.

49. Shah, M., D. M. Foreman, and M. W. Ferguson. 1992. Control of scarring in adult wounds by neutralising antibody to transforming growth factor β 1. *Lancet*. 339:213-214.

50. Giri, S. N., D. M. Hyde, and M. A. Hollinger. 1993. Effect of antibody to transforming growth factor β 1 on bleomycin induced accumulation of lung collagen in mice. *Thorax*. 48:959-966.

51. Logan, A., M. Berry, A. M. Gonzalez, S. A. Frautschy, M. B. Sporn, and A. Baird. 1994. Effects of transforming growth factor β on scar production in the injured central nervous system of the rat. *Eur. J. Neurosci.* 6:355-363.

52. Wahl, S. M., J. B. Allen, G. L. Costa, H. L. Wong, and J. R. Dasch. 1993. Reversal of acute and chronic synovial inflammation by anti-transforming growth factor β . *J. Exp. Med.* 177:225-230.

53. Wolf, Y. G., L. M. Rasmussen, and E. Ruoslahti. 1994. Antibodies against transforming growth factor β -1 suppress intimal hyperplasia in a rat model. *J. Clin. Invest.* 93:1172-1178.

54. Mendell, J. R., R. T. Moxley, R. C. Griggs, M. H. Brooke, G. M. Fenichel, J. P. Miller, W. King, L. Signore, S. Pandya, J. Florence, et al. 1989. Randomized, double-blind six-month trial of prednisone in Duchenne's muscular dystrophy. *N. Engl. J. Med.* 320:1592-1597.

55. Sharma, K. R., M. A. Mynhier, and R. G. Miller. 1993. Cyclosporine increases muscular force generation in Duchenne muscular dystrophy. *Neurology*. 43:527-532.