

Accumulation of PiZ α_1 -Antitrypsin Causes Liver Damage in Transgenic Mice

Joyce A. Carlson, Beverly Barton Rogers, Richard N. Sifers, Milton J. Finegold, Shirley M. Clift, Francesco J. DeMayo, David W. Bullock, and Savio L. C. Woo

Departments of Cell Biology, Gastroenterology, and Pathology, Howard Hughes Medical Institute and Institute for Medical Genetics, Baylor College of Medicine, Houston, Texas 77030

Abstract

Circulating α_1 -antitrypsin is synthesized primarily in the liver and secreted into the bloodstream, where it serves as the major protease inhibitor. The PiZ variant of α_1 -antitrypsin is associated with decreased levels of the protein in sera as a result of its retention within hepatocytes. Homozygosity for the variant allele predisposes individuals to the development of pulmonary emphysema and an increased risk for liver disease. We and others have previously demonstrated that the normal PiM human α_1 -antitrypsin gene can be properly expressed in the livers of transgenic mice. The PiZ variant of the human α_1 -antitrypsin gene was introduced into the germline of mice to determine whether the mutant protein would accumulate in mouse hepatocytes and if such accumulation would result in the development of liver damage in an animal model. As expected, the mutant human protein was abundantly synthesized in the livers of the transgenic animals and accumulated within the rough endoplasmic reticulum of hepatocytes as it does in human patients. PiZ mice developed significantly more liver necrosis and inflammation than PiM transgenic mice or control littermates. The degree of liver damage was correlated with the amount of PiZ α_1 -antitrypsin accumulated in the liver of the different pedigrees of mice. Although 40% of PiZ mice tested were seropositive for mouse hepatitis virus (MHV), the degree of liver damage was not influenced by the MHV seropositivity; rather, it was related only to the presence of accumulated PiZ protein.

Introduction

α_1 -Antitrypsin (α_1 -AT)¹ is the most abundant serine protease inhibitor in plasma. A major physiological function of this protein appears to be protection of elastic fibers in the lung

Dr. Carlson's present address is Department of Medicine, Malmo General Hospital, S-214 Malmo, Sweden. Dr. Rogers's present address is Department of Pathology, Women and Infants Hospital, 101 Dudley Street, Providence, RI 02904. Dr. Clift's present address is Genentech, 460 Pt. San Bruno Blvd., South San Francisco, CA 94080. Dr. Bullock's present address is Lincoln College, Canterbury, New Zealand. Address reprint requests to Dr. Milton J. Finegold, Director of Laboratories, Texas Children's Hospital, 6621 Fannin, Houston, TX 77030.

Received for publication 14 September 1988 and in revised form 23 November 1988.

1. Abbreviations used in this paper: α_1 -AT, α_1 -antitrypsin; E, eosin; H, hematoxylin; MHV, mouse hepatitis virus; RER, rough endoplasmic reticulum; SPF, specific pathogen free.

J. Clin. Invest.

© The American Society for Clinical Investigation, Inc.

0021-9738/89/04/1183/08 \$2.00

Volume 83, April 1989, 1183-1190

from hydrolytic destruction by excessive leukocyte elastase (1). Among the more than 30 variants of human α_1 -antitrypsin, the PiZ form is associated with decreased levels of α_1 -AT in sera (2). The circulatory deficiency of this protein results from its retention within the rough endoplasmic reticulum (RER) of hepatocytes (3).

Homozygosity for the PiZ allele predisposes individuals to develop pulmonary emphysema (2) and liver disease, including neonatal cholestasis (3), cirrhosis (4), and hepatoma (5). It has been estimated that ~5% of PiZZ infants (6) and 50% of adults with homozygous α_1 -AT deficiency exhibit liver cirrhosis at death (5). PiMZ heterozygosity may also contribute to the development of chronic liver disease and carcinoma (7-11), although the data are controversial (12).

Considerable data support the hypothesis that alveolar destruction leading to emphysema is caused by an imbalance between leukocyte elastase and α_1 -AT in the lungs, but at present no firm data exist to explain the pathogenesis of liver disease in α_1 -AT deficiency. This question is of increasing importance at a time when liver transplantation is frequently performed for juvenile cirrhosis (13) and replacement therapy for circulating α_1 -AT deficiency is available (14). In this study, we have generated transgenic mice that express the PiZ α_1 -AT gene to test whether retention of the mutant PiZ protein in hepatocytes is sufficient to cause hepatocellular damage and chronic liver injury. Mice bearing multiple copies of the normal PiM human α_1 -AT gene (15, 16) and nontransgenic littermates of all transgenic mice have been used as controls for the histopathological evaluation.

Methods

Production, maintenance, and identification of transgenic mice. Cloning of the PiZ allele of the human α_1 -AT gene has previously been reported (15). Methods for the preparation of the DNA, its microinjection into mouse embryos, and identification of transgenic offspring by Southern blot analysis of mouse tail DNA are identical to those reported for the production of transgenic mice bearing the normal PiM allele of human α_1 -AT (15, 16). At the age of 1 mo, litters were weaned. Transgenic mice were housed in the same cage as were their sex-matched littermates, and maintained with unlimited access to food (MRH 22/5 Rodent Blox 8840; Premier Lab Diets, Inc., Peoria, IL) (composition available upon request) and fresh water. Original animals were regarded as specific pathogen free (SPF) by suppliers and all animals were maintained under SPF conditions. All experiments were approved by the Baylor institutional review board and followed the guidelines of the National Research Council for the care and use of laboratory animals.

Detection of human α_1 -antitrypsin in mouse sera. Blood was collected from mice by orbital vein puncture using heparinized capillary tubes. After centrifugation, 2- μ l serum samples were treated with disruption buffer at 90°C for 5 min and proteins were fractionated by SDS-PAGE (17). Protein bands were identified after Western blotting (18) onto nitrocellulose membranes by species specific antisera as previously described (15). Quantitation was performed by electroimmunoassay (16).

Histopathology. 243 mice aged 6–20 mo from pedigrees bearing the human PiZ and PiM genes and their respective age and sex matched littermates were killed by cervical dislocation and autopsied. Tissues were fixed in Carson Millonig 10% phosphate-buffered formalin, pH 7.4, and embedded in paraffin for light microscopy. Samples were coded to permit unbiased histological analysis by two observers (B. B. Rogers and M. J. Finegold). Sections stained with hematoxylin (H)-eosin (E), periodic-acid Schiff (PAS), and trichrome were evaluated for each of the following characteristics: (a) presence, quantity, and distribution of hepatocellular globular inclusions; (b) hepatocellular necrosis; (c) cholestasis; (d) lobular inflammation (acute and chronic); (e) portal tract inflammation (acute and chronic); (f) portal fibrosis; (g) architectural disarray; and (h) hyperplastic or regenerating nodules. Each characteristic was scored from 0 to 3+, where 0 was absence of the feature, 1+ was mild, 2+ was moderate, and 3+ was severe.

Sections of selected livers were stained for human α_1 -AT by standard immunoperoxidase methods (16). Liver sections from a PiZZ human served as a positive control. Nontransgenic mouse liver and incubation of adjacent sections with nonimmune goat sera provided negative controls.

Electron microscopy. Selected specimens from each group were examined, following standard procedures (16). Thin sections were stained with uranyl acetate and lead citrate and examined in a Joel 100 C transmission electron microscope. Immunoelectron microscopy was performed as previously described (16). Goat anti-rabbit IgG (Cooper Cappel Laboratories, Malvern, PA) was tagged with *Staphylococcus A* protein labeled with gold beads. Species-specific rabbit anti-human α_1 -AT was used as the primary antibody. This antiserum did not react with mouse α_1 -AT.

Viral studies. To evaluate the health status of the mouse colony and the possible presence of confounding factors affecting histopathological analysis of liver sections, a broad screen of viral antibody titers was performed on sentinel animals (mouse virus screen; Microbiological Associates, Inc., Rockville, MD). As some of the sentinels had positive mouse hepatitis virus (MHV) serology, 132 serum samples obtained at killing were later analyzed for MHV antibodies. No other viruses known to cause liver disease were demonstrated in the colony.

Statistical methods. Liver pathology scores in transgenic mice and their nontransgenic littermates were compared for each pedigree and each group. Calculations were performed using the Mann-Whitney method of nonparametric statistics with the T1 correction for cases with multiple ties (19). The significance of the amount of α_1 -AT and the presence or absence of antibodies to MHV were tested by the same method.

Results

Identification of transgenic mice. The presence of mice bearing the PiZ human α_1 -AT allele was demonstrated by Southern blot analysis of mouse tail DNA as previously described (15). The human α_1 -AT gene was identified as hybridizing bands at 6.3 and 2.7 kb (Fig. 1). Six Fo transgenic lines were generated as shown in lanes 1, 2, 3, 4, 7, and 8, and these mice were designated Z1.01, Z6.03, Z12.02, Z6.06, Z13.00, and Z11.03, respectively. The frequency of transmission of the human α_1 -AT gene to subsequent generations has followed a typical Mendelian pattern in pedigrees Z1.01, Z6.03, and Z11.03 (data not shown). By comparison of band intensities to those of serially diluted cloned DNA standards, it was estimated that lines Z1.01 and Z11.03 contained ~ 10 gene copies per cell compared with a single gene copy in line Z6.03 (data not shown). The production of mice bearing the normal PiM human α_1 -AT allele has been previously reported (15). Pedigree M2.03 contained ~ 50 gene copies per cell as compared with 100 copies in M3.03 and 10 copies in M5.00.

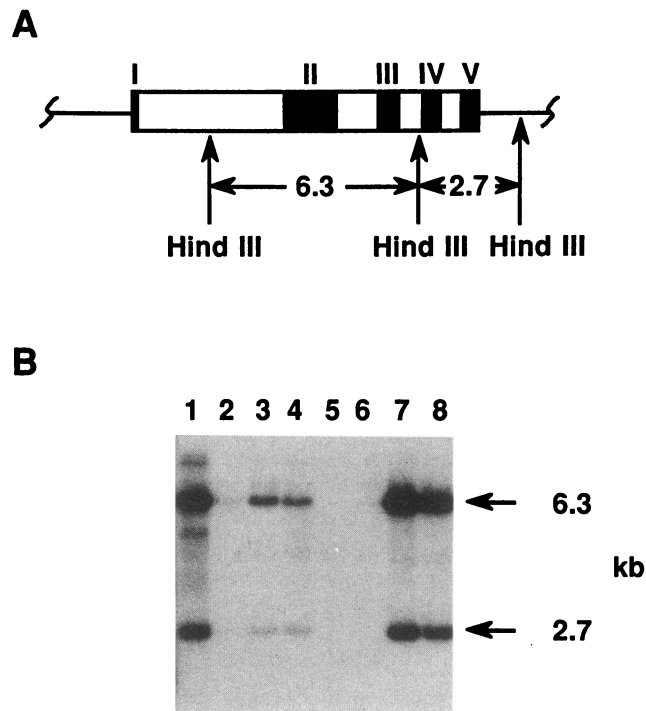


Figure 1. (A) Schematic representation of the human α_1 -AT gene. Exonic regions are shown in black and designated by roman numerals. Vertical arrows show the position of Hind III restriction sites which generate 6.3- and 2.7-kb DNA fragments detected in the Southern blot analysis. (B) Detection of the human α_1 -AT gene in transgenic mouse DNA. Approximately 10 g of DNA extracted from mouse tails was digested to completion with Hind III and subjected to agarose gel electrophoresis. The fractionated DNA was transferred to nitrocellulose and hybridized with a 32 P-labeled nick-translated human α_1 -AT cDNA. The filter was washed to a stringency of $0.2\times$ SSC at 65°C and hybridizing bands were detected by auto-radiography. Lane 1, Z1.01; lane 2, Z6.03; lane 3, Z12.02; lane 4, Z6.05; lane 7, Z13.00; lane 8, Z11.03. Lanes 5 and 6 are DNA from nontransgenic mice.

Detection of human α_1 -AT in mouse serum. Because α_1 -AT is a major serum protein, expression of the transgene could be determined by detection of human α_1 -AT in the sera of transgenic animals. As shown in Fig. 2, varying levels of expression of the transgene were observed. Progeny from lines Z1.01 (lane 4) and Z11.03 (lane 6) exhibited human α_1 -AT in their sera at levels similar to that of a homozygous PiZZ individual (lane 2), which was ~ 10 – 15% of that detected in a normal PiMM subject (lane 1). In contrast, line Z6.03 exhibited very low serum levels of human α_1 -AT (lane 5). In this experiment, a mixture of antibodies against human and mouse α_1 -AT was used so that the mouse α_1 -AT was also detected in mouse sera as a band with a slightly faster migration than the human band (Fig. 2, lanes 3–6). Similarly, mice from line M2.03 exhibited plasma α_1 -AT levels similar to normal PiM humans (15). M5.00 plasma α_1 -AT was $\sim 20\%$ and M3.03 $\geq 200\%$ of normal human PiM levels (15). These estimates were verified by electroimmunoassay, which showed plasma levels of 0.05, 0.20, and 0.35 times normal human levels for Z6.03, Z1.01, and Z11.03 heterozygotes, respectively. PiM heterozygotes had levels of 1.2, 2.0, and 3.2 times the normal human level (1.35 g/liter) in pedigrees M5.00, M2.03, and M3.03, respectively (data not shown). Progeny from these six transgenic lines

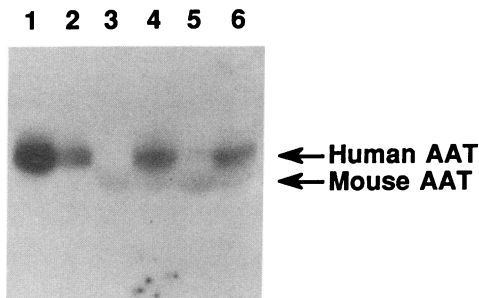


Figure 2. Detection of human α_1 -AT in sera from transgenic mice. Equivalent volumes (2.1) of sera from mice were heated in disruption buffer and subjected to SDS-PAGE. After the transfer of the fractionated proteins to nitrocellulose, the filter was subjected to immunoblotting for the detection of human α_1 -AT using a crude (non-species-specific) preparation of goat anti-human α_1 -AT. Both human and mouse α_1 -AT were detected as shown: Lane 1, human PiMM; lane 2, human PiZZ; lane 3, nontransgenic mouse; lane 4, Z1.01; lane 5, Z6.03; lane 6, Z11.03.

representing low and high expression of the PiM and PiZ transgenes were used in subsequent experiments.

Histopathology. Hepatocytes of mice carrying 10 copies of the human PiZ gene (pedigrees Z1.01 and Z11.03) exhibited numerous cytoplasmic globular inclusions that stained light pink in H- and E-stained sections, bright pink with PAS (Fig. 3), and bright red in trichrome stains. Using a peroxidase-tagged antibody to human α_1 -AT, the identity of the accumulated material was confirmed as human α_1 -AT (Fig. 4). Purified antisera to mouse α_1 -AT, provided by Dr. Gretchen Darlington of the Pathology Department, Baylor College of Medicine, failed to stain the inclusions. Electron microscopy and immunoelectron microscopy revealed that the accumulated human PiZ α_1 -AT was localized in the rough endoplasmic reticulum (Figs. 5 and 6), just as in the human PiZZ liver. The largest inclusions sometimes exceeded the size of a normal cell, but most hepatocytes containing them were morphologi-

cally intact. However, multiple small foci of necrosis were present, and these areas frequently showed fragmentation of hepatocytes and globules. Associated with such foci were clusters of leukocytes (Fig. 7). The distribution of the globules was panlobular, unlike the human condition, in which periportal hepatocytes are primarily affected. Necrotic foci with inflammation were likewise random in the lobule. However, there were also leukocytic infiltrates in occasional portal tracts and in surrounding terminal hepatic veins not directly associated with α_1 -AT globules.

Fibrosis was infrequent and modest in all groups and never distorted the lobular architecture. Mild degrees (1+) consisted of delicate strands of collagen expanding portal areas or extending in finger-like fashion from portal tracts or terminal hepatic veins into the lobules. Moderate fibrosis (2+) was rare. It was defined as denser patches of collagen occupying the width of a sinusoid. Trichrome stains were used for these estimates.

Cholestasis was observed only once, in a control liver. Bile duct proliferation occurred in small foci of three PiZ transgenic mice. Small nodules of hepatocytes were observed only once in a PiZ mouse and once in a control.

Quantitative analysis of the pathological findings, therefore, was based on inflammation (lobular plus perivenous plus portal), necrosis, and fibrosis. The scores for each alteration in individual animals from each group were tabulated, ranked, and compared. The results are shown in Table I and Fig. 8. There is a significant increase in inflammation, necrosis, and total pathology score (adding each of the categories together) in the PiZ transgenic mice compared with their control littermates and with PiM transgenic mice ($P < 0.001$). An increase in fibrosis failed to reach statistical significance in PiZ mice versus their controls ($P = 0.08$). However, a significant increase in fibrosis was observed among PiZ mice versus PiM mice ($P = 0.009$). Furthermore, PiM mice exhibited no significant increase in pathological findings compared with their controls, even though α_1 -AT does accumulate in hepatocytes of PiM mice bearing a high copy number of the transgene (16).

Microscopically identifiable globules of α_1 -AT were not

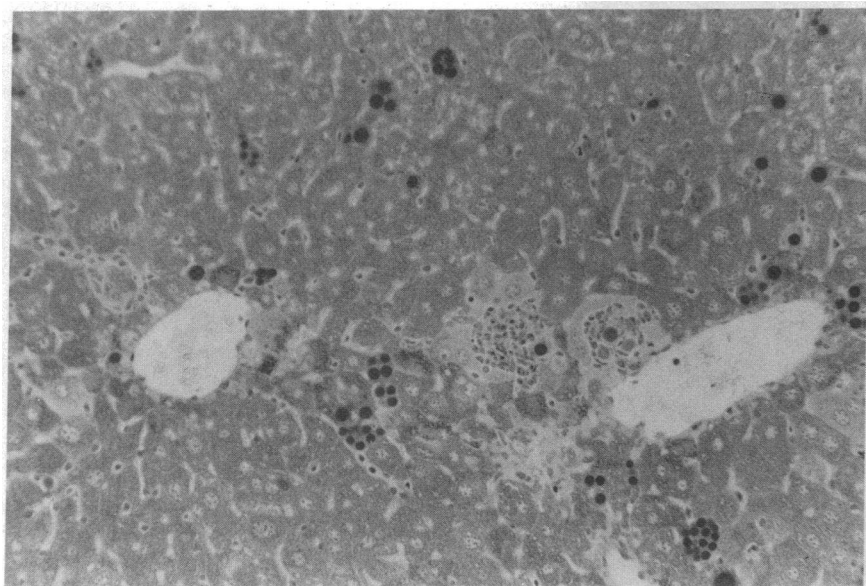


Figure 3. Hepatocytes in the liver of a PiZ transgenic mouse contain many globular cytoplasmic inclusions. (PAS stain, $\times 160$.)

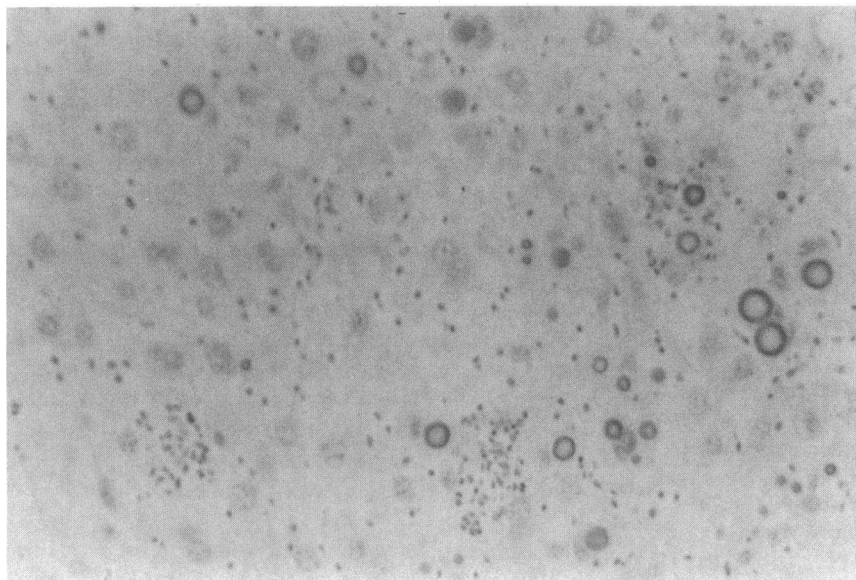


Figure 4. Human α_1 -AT is demonstrable in mouse hepatocyte inclusions using a specific goat antibody labeled with peroxidase. The globules stain brown in this reaction and appear to be dark spheres in the photograph. ($\times 400$.)

found in pedigree Z6.03, which had only one copy of the human PiZ gene and exhibited a low level expression of the transgene. The difference in biopsy scores of 23 mice from that pedigree versus their controls was less dramatic than the differences between 69 mice from the two 10-copy number pedigrees and their littermate controls (Table II). The transgenic mice carrying the PiM gene showed globular accumulation of protein in only three cases, and the accumulation of the PiM protein did not affect total pathology score.

The presence of occasional necroinflammatory lesions in the livers of some control mice raised the possibility that MHV or some other environmental agent could be responsible. Although all the mice were derived from SPF sources and efforts were made to maintain the same conditions, serological data revealed that MHV had infected some sentinel animals. Therefore, the pathological findings were reanalyzed in rela-

tion to the MHV status of the animals. Although not all the mice had serological studies performed, sufficient numbers were available to draw the conclusions from the data shown in Table III and Fig. 9. The conclusions from those data strongly support the concept that the intrahepatic accumulation of the PiZ protein is responsible for liver damage regardless of the MHV status of the animal. MHV-negative PiZ mice had virtually the same degree of liver injury as MHV-positive PiZ carriers. All but one of the PiM mice tested were MHV positive and their biopsy scores were, as shown earlier, much lower than PiZ animals and little different from controls.

Discussion

It has been established for 25 years that the human PiZ α_1 -AT deficiency state predisposes individuals to early onset panlob-

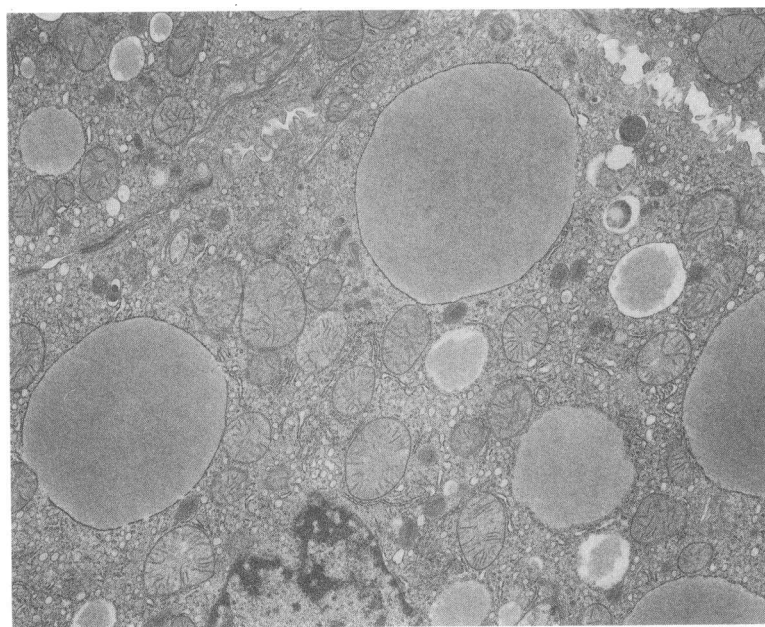


Figure 5. Accumulation of α_1 -AT in the RER of a mouse hepatocyte expressing the human gene for PiZ α_1 -AT. This pattern of retention is identical to that seen in human PiZZ homozygote liver. (Uranyl acetate, lead citrate, $\times 6,900$.)

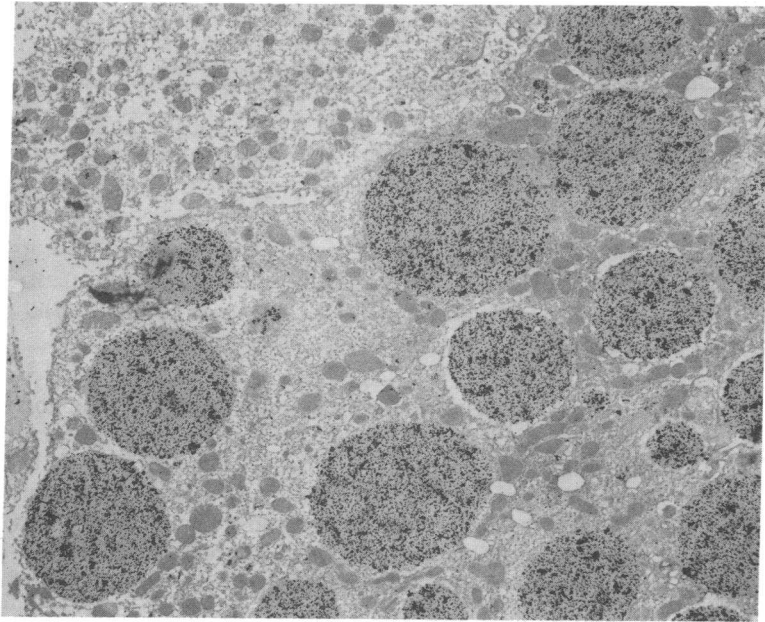


Figure 6. Specific accumulation of human PiZ α_1 -AT in mouse hepatocyte RER is demonstrated by immunoelectron microscopy. The black grains are due to gold attached to antibody by Staph A protein. (Uranyl acetate, $\times 5,000$.)

ular emphysema (2). Observations that neonatal cholestasis and juvenile cirrhosis were associated with the accumulation of globular inclusions of α_1 -AT in the RER of hepatocytes soon followed (3). These observations were extended to reveal a high prevalence of liver cirrhosis among adult PiZ individuals (5). The only available treatment for the liver disease at this time is orthotopic liver transplantation (13).

Of PiZ adults who have been systematically followed, it appears that $\sim 50\%$ die at a mean age of 52 yr of severe lung disease. Those subjects have mild or no signs of liver disease. Mortality of the remaining 50% occurs ~ 10 yr later with signs of chronic progressive liver disease at death and milder lung disease (20). Among PiMZ heterozygotes, lung disease is not significantly increased but chronic progressive liver disease has been found occasionally with progression to cirrhosis and,

rarely, hepatoma (11). It thus appears that patients with lower rates of secretion and low plasma α_1 -AT levels risk rapid development of emphysema, and those with somewhat higher rates of synthesis have better protection of alveolar tissue, but a greater prevalence of liver disease. These epidemiological data have led to the hypothesis that accumulation of α_1 -AT in the liver is potentially hepatotoxic.

The distinction between the two major forms of disease has become important with the availability of replacement therapy (14). If liver disease is caused by a deficiency of the circulating antiprotease rather than by intracellular accumulation, then systemic replacement therapy would be the treatment for both liver and lung disease. However, if liver disease is caused by an hepatotoxic effect of retained antiprotease, replacement therapy would not be beneficial.

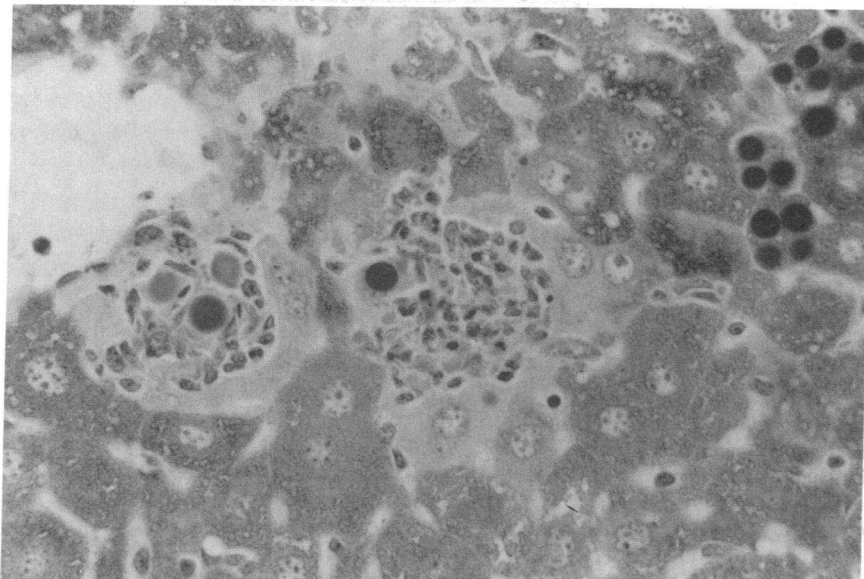


Figure 7. PiZ mouse liver has multiple foci of hepatocellular necrosis and clusters of inflammatory cells around the residual debris and fragmented globules. (PAS, $\times 400$.)

Table I. Histopathology of the Liver in Transgenic Mice

Human α_1 -AT	No. of mice	Specific pathologic features			Total pathology score		
		Necrosis	Inflammation	Fibrosis	Mean	SD	SE
Z gene	93	1.12	3.29	0.47	4.86	± 3.16	± 0.328
Z littermate controls	37	0.41	1.51	0.22	2.14	± 2.30	± 0.378
M gene	84	0.51	2.09	0.14	2.75	± 2.71	± 0.300
M littermate controls	29	0.28	1.83	0.10	2.17	± 2.51	± 0.466

Pathology scores of the Z and M transgenic mice differed at a value of $P < 0.001$ in the one-tailed Whitney U test. The scores for Z mice vs. littermate controls likewise differed at a value of $P < 0.001$. M transgenic mice scores did not differ from those of control littermates.

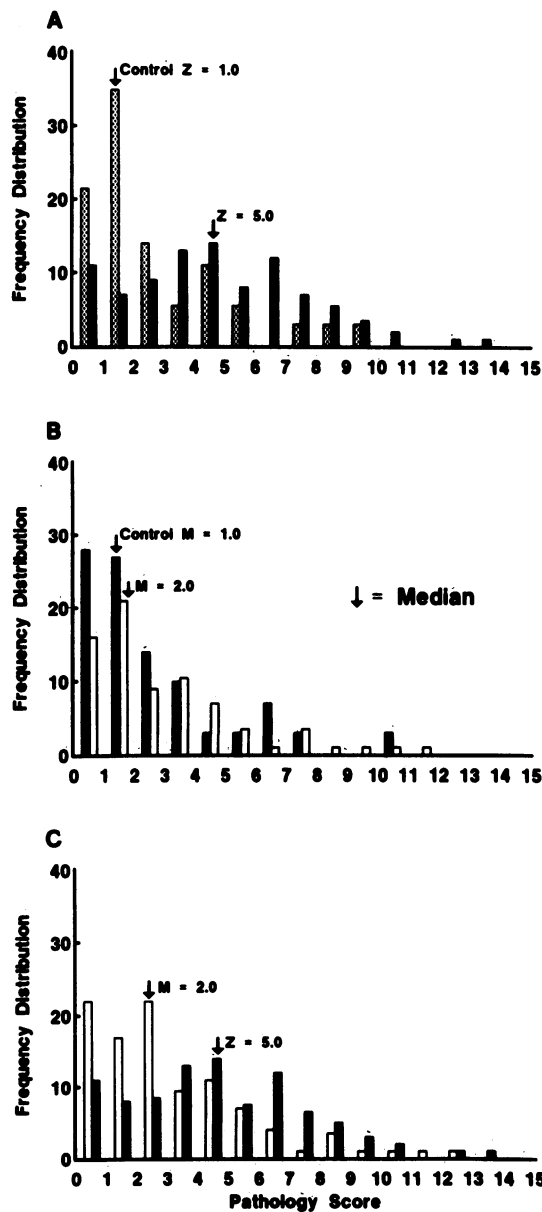


Figure 8. (A, B, and C) The frequency distribution of total pathology scores for all mice in each group is plotted. The percent of animals having each score (x axis) is given on the y axis and the mean is indicated for each group by the arrow. The difference in scores for (A) PiZ transgenic mice and their littermate controls is significant at a level of $P \leq 0.001$. (C) The same is true for the difference in scores between PiZ and PiM mice. (B) No difference was found between PiM mice and their littermate controls.

Animal models using exogenous proteases and inhibitors have been developed to substantiate the hypothesis that emphysema in the human PiZ α_1 -AT deficiency state is caused by protease-antiprotease imbalance at the alveolar level (21), but no animal model has been available to study the biosynthesis and secretion of mutant α_1 -AT and pathogenesis of liver disease in this condition. In this paper we report the production of transgenic mice that bear single or multiple copies of the human PiZ variant α_1 -AT gene. These mice clearly demonstrate hepatic synthesis, intracellular accumulation, and a low level of secretion of the human protein, corresponding to the human PiZ deficiency state. The presence of multiple copies of the human gene in each cell provides an exaggerated model of protein retention in two pedigrees. On the other hand, the mice continue to synthesize and secrete endogenous protease inhibitors, and thus have no circulating α_1 -AT deficiency state.

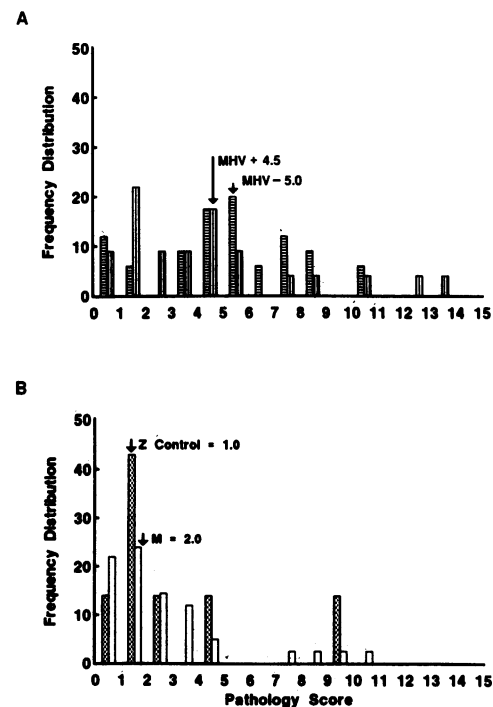


Figure 9. The effect of MHV on PiZ and PiM mice versus controls is not significant. A compares the total pathology scores of PiZ gene mice with and without serologic evidence of MHV. B compares PiM mice positive for MHV with control nontransgenic mice negative for MHV. Differences are not significant. Only 1 of 14 PiM littermate controls was negative for MHV, so PiZ littermate controls are shown.

Table II. Liver Injury in Relationship to Expression of the Human PiM and PiZ α_1 -Antitrypsin Genes in Transgenic Mice

	M mice				Z mice				
		C		C		C		C	
Pedigree	2.03		3.03		6.03		1.01		11.03
No. of mice	29	10	28	15	23	8	30	10	39
Gene copy number	50	0	100	0	1	0	10	0	>10
Plasma α_1 -AT concentration*	2.0	0	3.2	0	0.05	0	0.20	0	0.35
Mean globule score [†]	0	0	0.1	0	0	0	2.1	0	2.9
Difference in mean biopsy score (M - CM, Z - CZ)	0.13		0.82		1.28		2.13		3.94
P value	0.38		0.06		<0.028		<0.002		<0.0001

* Mouse plasma α_1 -AT concentration/normal human plasma α_1 -AT concentration. [†] Abundance of α_1 -AT globular inclusions on light microscopy of liver biopsies, scored from 0-3+.

Although this difference may appear to limit the value of the animal model, it creates a unique opportunity to specifically evaluate the pathogenetic effect of the retention of PiZ α_1 -AT within the RER of hepatocytes.

The results of this study clearly demonstrate the development of acute liver necrosis and inflammation in relation to the presence of the human PiZ gene and the quantity of its protein product. The unanticipated finding of similar histopathological alterations in a small number of control mice led us to the realization that despite their pathogen-free source and maintenance, significant numbers of mice in all groups had serological evidence of exposure to MHV. But this discovery provided further evidence for the contribution of the PiZ protein to liver damage, as no differences in degree of liver injury could be demonstrated between PiZ mice with and without MHV. In contrast, a very significant difference was observed between PiZ and PiM mice positive for MHV. However, none of the PiZ mice studied up to 20 mo of age developed cirrhosis or hepatoma.

Limitations of the validity of any animal model include differences in metabolism and life expectancy between species. The normal life expectancy of healthy laboratory mice is 2 yr (22). This period of time may not be sufficient for development of chronic liver disease with severe fibrosis and cirrhosis. Furthermore, there is no known spontaneous severe murine

fibrosis or cirrhosis, and chronic administration of toxins or constant dietary deficiencies have been required to produce murine liver disease experimentally (23). Mice infected with *Schistosoma mansoni* do develop extensive fibrosis, however (24). In future experiments, the transgenic PiZ mice will be subjected to chronic low-level hepatotoxicity to determine whether the human pattern of chronic disease can be reproduced.

Acknowledgments

We thank Mrs. Billie Smith for providing technical assistance in histology and immunoperoxidase staining and Mrs. Linda Rehm for routine and immunoelectron microscopic preparation of liver sections. Dr. Gregory Buffone helped with the statistical analysis. We also thank Mrs. Janet DeMayo for the densitometric analysis of immunoblots. We also express our appreciation to Mrs. Virginia Bates for typing this manuscript.

This research was supported in part by National Institute of Health (NIH) grants HL-27509 and HL-37188 awarded to S. L. C. Woo, who is also an Investigator of the Howard Hughes Medical Institute. R. N. Sifers is the recipient of NIH postdoctoral fellowship HL-07343. J. A. Carlson was supported by NIH training grant AM-07479.

Note added in proof. Transgenic mice carrying a 21.4-kb fragment with the human PiZ gene have been reported by Dyaico et al. to display liver damage similar to that which we have described. (1988. *Science [Wash. DC]*. 242:1409-1412.)

References

- Lieberman, J. 1976. Elastase, collagenase, emphysema and α_1 -antitrypsin deficiency. *Chest*. 70:62-65.
- Laurell, C.-B., and S. Eriksson. 1963. The electrophoretic α_1 -globulin pattern of serum in α_1 -antitrypsin deficiency. *Scand. J. Clin. Lab. Invest.* 15:132-140.
- Sharp, H. L. 1971. α_1 -Antitrypsin deficiency. *Hosp. Pract.* 6:63-96.
- Berg, N. O., and S. Eriksson. 1972. Liver disease in adults with α_1 -antitrypsin deficiency. *N. Engl. J. Med.* 287:1264-1267.
- Eriksson, S., J. Carlson, and R. Velez. 1986. Increased risk for cirrhosis and hepatoma in homozygous α_1 -antitrypsin deficiency. *N. Engl. J. Med.* 314:736-739.
- Sveger, T. 1984. Prospective study of children with α_1 -antitrypsin deficiency: eight-year-old follow-up. *J. Pediatr.* 104:91-94.
- Rawlings, W., Jr., J. Moss, H. S. Cooper, and S. R. Hamilton. 1974. Hepatocellular carcinoma and partial deficiency of alpha-1-antitrypsin (MZ). *Ann. Intern. Med.* 81:771-773.

Table III. Liver Injury in Relation to MHV

Human α_1 -AT	MHV+		MHV-	
	n	Mean \pm SD	n	Mean \pm SD
Z mice	20	4.90 \pm 3.22	32	4.66 \pm 2.78
CZ mice	8	2.38 \pm 2.92	9	1.78 \pm 2.17
M mice	40	2.88 \pm 2.62	1	—
CM mice	13	2.00 \pm 2.34	0	—

Pathology scores of the MHV + Z and MHV + M transgenic mice differed by a P value of 0.003 in the one-tailed Mann-Whitney U test. (Using t test, the P value was 0.006). MHV + Z mice scores differed from MHV + CZ scores with a P value of 0.002. The mean pathology scores were higher for MHV+ than MHV- mice in both the Z gene and control groups, but the differences were not significant.

8. Cruz, M., J. A. Urolina, D. Pedrola, and F. Munoz-Lopez. 1975. Cirrhosis and heterozygous α_1 -antitrypsin deficiency in a 4-year-old girl. *Helv. Paediat. Acta.* 30:501-507.
9. Lieberman, J., R. M. Siltan, C. M. Aglizzo, and J. McMahon. 1975. Hepatocellular carcinoma and intermediate α_1 -antitrypsin deficiency (MZ phenotype). *Am. J. Clin. Pathol.* 64:304-310.
10. Hodges, J. R., G. H. Millward-Sadler, C. Barbatis, and R. Wright. 1981. Heterozygous MZ alpha₁-antitrypsin deficiency in adults with chronic active hepatitis and cryptogenic cirrhosis. *N. Engl. J. Med.* 304:557-560.
11. Carlson, J., and S. Eriksson. 1985. Chronic "cryptogenic" liver disease and malignant hepatoma in intermediate α_1 -antitrypsin deficiency identified by a PiZ-specific monoclonal antibody. *Scand. J. Gastroenterol.* 20:835-842.
12. Morin, T., J. P. Martin, G. Feldmann, B. Rueff, J. P. Benhamou, and C. Ropartz. 1975. Heterozygous alpha-1-antitrypsin deficiency and cirrhosis in adults, a fortuitous association. *Lancet.* i:250.
13. Gordon, R. D., B. W. Shaw, Jr., S. Iwatsuki, C. O. Esquivel, and T. E. Starzl. 1987. Indications for liver transplantation in the cyclosporine era. *Surg. Clin. North. Am.* 66:541-558.
14. Wewers, M. D., A. Casolaro, S. E. Sellers, S. C. Swayze, K. M. McPhaul, J. T. Wittes, and R. G. Crystal. 1987. Replacement therapy for α_1 -antitrypsin deficiency associated with emphysema. *N. Engl. J. Med.* 316:1055-1062.
15. Sifers, R. N., J. A. Carlson, S. M. Clift, F. J. DeMayo, D. W. Bullock, and S. L. C. Woo. 1987. Tissue specific expression of the human α_1 -antitrypsin gene in transgenic mice. *Nucleic Acids Res.* 15:1459-1475.
16. Carlson, J. A., B. B. Rogers, R. N. Sifers, H. K. Hawkins, M. J. Finegold, and S. L. C. Woo. 1988. Multiple tissues express α_1 -antitrypsin in transgenic mice and man. *J. Clin. Invest.* 82:26-36.
17. Laemmli, U. K. 1970. Cleavage of structural proteins during the assembly of the head of bacteriophage T₄. *Nature (Lond.).* 227:680-685.
18. Towbin, H., T. Staehelin, and J. Gordon. 1979. Electrophoretic transfer of proteins from polyacrylamide gels to nitrocellulose sheets: procedure and some applications. *Proc. Natl. Acad. Sci. USA.* 76:4350-4354.
19. Conover, W. J. 1980. Practical Nonparametric Statistics. John Wiley & Sons, New York. 215-220.
20. Eriksson, S. 1987. α_1 -Antitrypsin deficiency and liver cirrhosis in adults: an analysis of 35 Swedish autopsied cases. *Acta. Med. Scand.* 221:461-467.
21. Janoff, A., B. Sloan, G. Weinbaum, V. Damiano, R. A. Sandhaus, J. Elias, and P. Kimbel. 1977. Experimental emphysema induced with purified human neutrophil elastase. Tissue localization of the instilled protease. *Am. Rev. Respir. Dis.* 115:461-468.
22. Kaplan, H. M., N. R. Brewer, and W. H. Blair. 1983. Physiology. In *The Mouse in Biomedical Research*. Vol III. H. L. Foster, J. D. Small, and J. G. Fox, editors. Academic Press, New York. 247-292.
23. Cornelius, C. E. 1988. Animal Models. In *The Liver: Biology and Pathobiology*. 2nd ed. I. M. Arias, W. B. Jakoy, H. Popper, D. Schachter, and D. Shafritz, editors. Raven Press, New York. 1315-1336.
24. Saber, M. A., D. A. Schafritz, and M. A. Zern. 1983. Changes in collagen and albumin mRNAs in liver tissue of mice infected with *Schistosoma mansoni* as determined by in situ hybridization. *J. Cell Biol.* 97:986-992.