

Rapid Publication

Human Squamous Cell Lung Cancers Express Increased Epidermal Growth Factor Receptors

Fred J. Hendler and Bradford W. Ozanne

Departments of Internal Medicine & Microbiology, Southwestern Medical School, University of Texas Health Science Center, Dallas, Texas 75235

Abstract. Epidermal growth factor (EGF) promotes the growth of cultured benign and malignant cells. Recent studies have demonstrated that the amount of EGF receptor is elevated in squamous cell carcinoma cells in tissue culture when compared with normal epidermal cells. This study demonstrates that elevated levels of EGF receptor are detected in biopsy specimens of human squamous cell carcinomas of the lung with a murine monoclonal antibody, EGF-R1, which binds specifically to the receptor. The increased receptor ranged from 2.5- to 5-fold that of normal skin. These findings have been observed in 11 of 11 squamous carcinomas and two of two epidermoid head and neck cancers. Seven of eight adenocarcinomas, two of two small cell, and four of eight undifferentiated lung cancers had negligible amounts of EGF receptor. The EGF receptor antibody did not bind significantly to normal lung tissues and 35 nonepidermoid tumors. Therefore, EGF receptor may be an excellent marker for epidermoid malignancies.

Introduction

Epidermal growth factor (EGF)¹ promotes the growth of a wide variety of cultured normal and malignant cells in vitro (1).

Dr. Hendler is a Junior Faculty Fellow of the American Cancer Society. This work is supported by National Institutes of Health grant CA-32895 to Dr. Hendler and CA-23403 to Dr. Ozanne. Address correspondence to Dr. Hendler at the Cancer Center.

Received for publication 9 April 1984.

1. *Abbreviations used in this paper:* EGF, epidermal growth factor; EGF-R1, a murine monoclonal epidermal growth factor receptor-specific antibody.

Cultured tumor cells and their normal counterparts usually express equal numbers of EGF receptors (1-3). The one exception is cultured human squamous carcinoma cells. Several of these cell lines have been reported to express 4-7-fold more EGF receptors than do cultured keratinocytes (4). Whether this elevation reflects an increased level of EGF receptors in these squamous cell carcinomas in vivo has not been determined. EGF receptors have not as yet been quantitated in human tumor specimens. The present study examined human lung cancer biopsy specimens for the presence of EGF receptors. The measurement of receptor utilized a murine monoclonal antibody, EGF-R1, which has been previously described to specifically bind to the human EGF receptor by immunofluorescence (4, 5), binding assays in both fixed and unfixed tissue (5), and with immunoprecipitation (4-7). This report demonstrates that an EGF receptor-specific murine monoclonal antibody, EGF-R1 (5), binds to human squamous cell carcinomas. The levels of EGF receptor as determined by antibody binding to fixed cryosections are much greater in squamous tumors than in normal skin and most nonepidermoid lung cancers. This observation suggests that an increased number of EGF receptors may be a hallmark of epidermoid malignancies in vivo.

Methods

Tissue preparation

Tumor specimens were obtained from patients undergoing routine diagnostic procedures at Baylor University Hospital, Dallas, TX, the Dallas Veterans Administration Medical Center, and Parkland Memorial Hospital, Dallas, TX. Cryosections (6-8 μ m) were obtained from cryostat frozen specimens which were being studied in this manner for diagnostic purposes. Representative sections of each specimen that was obtained were stained with hematoxylin and eosin to confirm the diagnosis. Cryosections were fixed in 50% acetone-phosphate-buffered saline (PBS), washed four times with PBS, air dried, and stored at -70°C.

Binding of EGF-R1 to EGF receptors

Assay of EGF receptors. We employed a radioimmunoassay technique that had been developed for detecting antibody binding to mammary

J. Clin. Invest.

© The American Society for Clinical Investigation, Inc.

0021-9738/84/08/0647/05 \$1.00

Volume 74, August 1984, 647-651

carcinomas (8–10). EGF-R1 and 2b, an irrelevant control antibody of the same IgG isotype, were radiolabeled with ^{125}I using lactoperoxidase to an activity of $\sim 5 \times 10^3$ cpm/ng of antibody (11). The cryosections were covered with $100 \mu\text{l}$ radioiodinated monoclonal antibody (200,000 cpm trichloroacetic acid precipitable counts per minute) in PBS-50% calf serum. Sections were incubated for 3 h at 24°C and washed four times with PBS-5% calf serum. Sections were exposed to X-ray film (XAR, Eastman Kodak Co., Rochester, NY) for 16 h before development. Some slides were subsequently either stained with hematoxylin and eosin, or dipped in photographic emulsion (NTB-2, Eastman Kodak Co.), exposed for 96 h before development, and then stained with hematoxylin and eosin.

Quantitation of binding. EGF-R1 binding was quantitated by two techniques. Binding to all tissues was studied by reviewing autoradiographs on the X-ray film. Initially, binding was quantitated by scanning densitometry and scored 0–4. Subsequently, the autoradiographs were

then independently viewed by three observers and similarly scored. When emulsion autoradiography was performed, the photographic grains in the emulsion were counted using a computerized grain-counting device (Magiscan; Joyce-Loebl-Nikon, Garden City, NY), and confirmed by manual counting. 10 microscopic fields of $100 \mu\text{m}^2$ were counted per cryosection using a $100\times$ objective. The areas within the field that did not contain tumor were computer subtracted and the grain counts presented were normalized to an area of $100 \mu\text{m}^2$.

Results

The specificity and sensitivity of the assay is demonstrated in Fig. 1, which represents a typical study of EGF-R1 binding to four lung tumors and one normal skin biopsy. The photomicrographs show that more EGF-R1 bound to the squamous

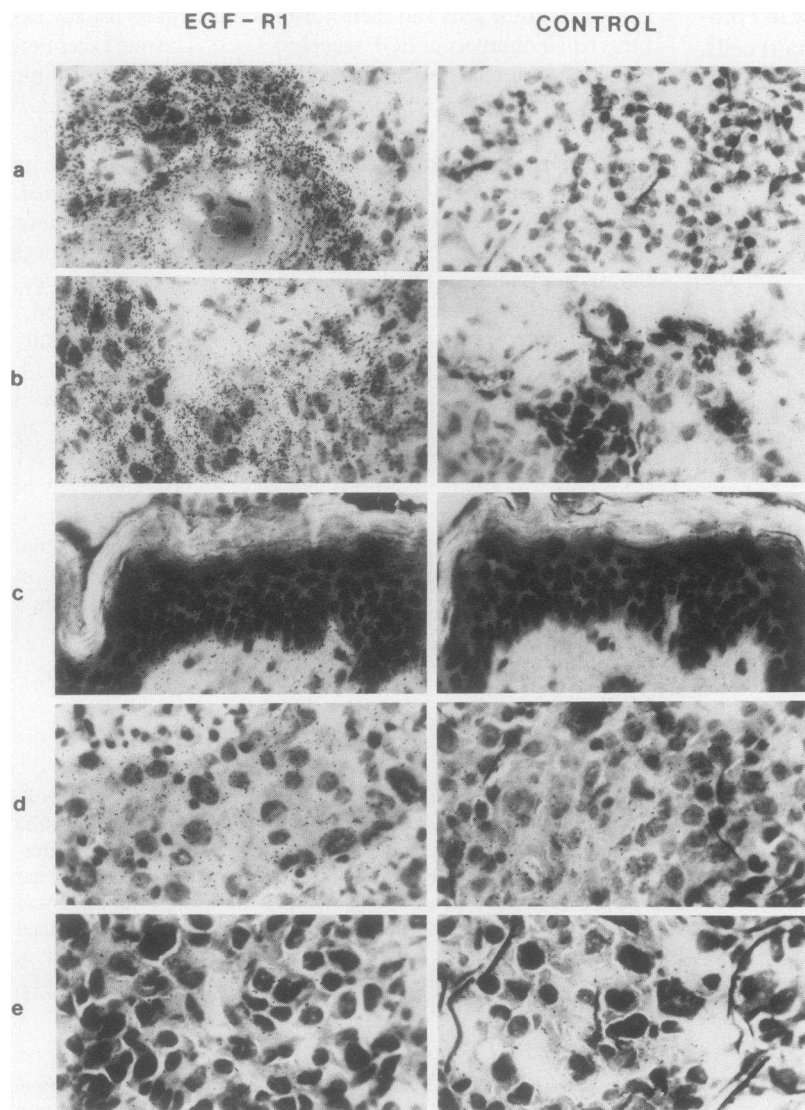


Figure 1. Binding of ^{125}I -EGF-R1 to fixed cryosections of lung cancer and normal skin. Tissue specimens obtained from patients undergoing diagnostic procedures were frozen and cut into 6–8- μm sections. The cryosections were fixed with acetone-PBS and adjacent sections were incubated with either ^{125}I -EGF-R1 (*left*) or a control ^{125}I -IgG monoclonal antibody (2b IgG) (*right*) for 3 h at 24°C . After four washes with PBS that contained 5% serum, the sections were dried, coated with photographic emulsion (NTB-2, Eastman Kodak Co.), and exposed for 96 h before development and staining with hematoxylin and eosin. The histologic diagnoses were as follows: *a*, squamous cell carcinoma; *b*, squamous cell carcinoma; *c*, normal skin; *d*, adenocarcinoma; and *e*, undifferentiated carcinoma in each pair of micrographs. $\times 630$.

carcinomas (Fig. 1, *a* and *b*) than to the adenocarcinoma (Fig. 1 *d*), an undifferentiated carcinoma (Fig. 1 *e*), or normal skin (Fig. 1 *c*). The amount of ^{125}I -EGF-R1 bound (Fig. 1, left) was much greater than the amount of a control antibody bound (Fig. 1, right) for all specimens except the undifferentiated carcinoma.

To quantitate the data of Fig. 1, the number of radioactive grains per $100\ \mu\text{m}^2$ of tissue sections were counted. These data confirmed the visual observation. The squamous tumors bound from 2.5 to 5 times as much EGF-R1 as normal skin and 3–6 times that of the adenocarcinoma (Table I). The number of grains that were present in the two squamous tumors and skin were significantly different at a probability $P < 0.001$. Similarly, the difference between the skin and adenocarcinoma and the adenocarcinoma and the undifferentiated carcinoma were all significant at $P < 0.001$.

For rapid evaluation of many tumor specimens, cryosections which had been reacted with antibody were covered with X-ray film that was then directly exposed for 16 h and examined at a gross level. The same cryosections that were used in Fig. 1 were used in Fig. 2. The density of the gross autoradiogram was consistent with the number of photographic grains that were detected with the emulsion, and the areas of intense binding represented the areas of squamous tumor in the biopsy specimens. On the basis of visual intensity, five subgroups have been recognized with semiquantitative grading from absent binding (0) to very intense binding (4+). For example, specimen 2 *a* represents an example of 4+, 2 *b* is 3+, 2 *c* and 2 *d* are 1+, and 2 *e* is 0. These visual impressions were substantiated by scanning densitometry, which confirmed the distinctions between the graded levels of EGF-R1 binding.

Using this rapid autoradiographic analysis, biopsy specimens from 29 patients with lung cancer have been evaluated (Table II). In the squamous cell carcinomas, EGF-R1 bound to 10 out of 11 intensely. The binding of EGF-R1 was uniform within the tumor except in areas of keratin formation and necrosis, where it was markedly decreased. EGF-R1 bound to only two of eight adenocarcinomas, and to only one of these tumors with moderate intensity. Neither of the small cell carcinomas bound EGF-R1. 50% of the undifferentiated lung tumors bound EGF-

R1 intensely. Normal lung bronchioles and alveoli in sections that contained lung cancer failed to bind significant amounts of EGF-R1. In addition, two squamous tumors of the head and neck were tested; both bound high levels of EGF-R1 (Table II). A total of 35 nonepidermoid tumors have been studied, of which none have greater EGF-R1 binding than normal skin. Six other monoclonal antibodies which bind antigens that are present in normal and malignant lung tissue have failed to preferentially bind to squamous carcinomas.

Discussion

The data that is presented may be of major clinical significance. High levels of EGF receptor were detected in all the squamous cell carcinomas of the lung and the head and neck studied. The EGF receptor content appears to be low in normal lung, skin, and epithelial cells. The ratio of specific binding of EGF-R1 to squamous cell carcinomas over normal skin in our assays is similar to that observed for EGF binding to squamous cell carcinoma cell lines as compared with cultured keratinocytes (4). Therefore, the level of EGF receptor may be an excellent marker for squamous malignancies. Since none of the other lung tumors that were studied had increased amounts of EGF receptor, except for four undifferentiated lung carcinomas, the presence of increased EGF receptors may be a useful means of distinguishing epidermoid from small cell and adenocarcinomas, which is often difficult to do with small biopsy specimens, even when electron microscopy is employed. Similarly, undifferentiated lung cancers may be segregated into those of squamous and nonsquamous origin using these assays. Such a subclassification may aid in determining appropriate therapies or prognosis for each subgroup.

The advantages of the assay techniques that are reported herein are significant. The assay can be done on very small biopsy specimens, which are often all the tissue that was obtained for diagnostic purposes. It is a direct antibody assay which reduces the background binding and allows for direct quantitation. By using a radioimmunoassay rather than immunofluorescence or immunoperoxidase, the sensitivity can be varied by changing the exposure time. When reacted slides are treated with photographic emulsion, binding can be correlated with the histology of the tumor through direct observation by many observers. The use of X-ray film autoradiographs enables rapid detection of ligand binding. We have used a similar approach to study antigens in breast cancer (8–10), and we believe that the technique can be generalized to any ligand that recognizes fixed tissue. Although the anti-EGF receptor antibody binds to the squamous carcinomas, we have been unable to demonstrate binding of ^{125}I -EGF to the cryosections. It seems likely that the EGF does not bind to the receptor after fixation, whereas the antibody recognizes the receptor in fixed tissue.

The noted increase in EGF receptor content in squamous tumors compared with normal bronchial epithelium, alveoli, and skin further support the hypothesis that increased expression

Table I. Quantitation of EGF-R1 Antibody Binding to EGF Receptors in Fixed Sections of Lung Cancers and Normal Skin

Tissue	EGF-R1	Control
	Grains/100 $\mu\text{m}^2 \pm \text{SD}$	Grains/100 $\mu\text{m}^2 \pm \text{SD}$
Squamous cell carcinoma, 1	6,388 \pm 73.5	193.5 \pm 23.8
Squamous cell carcinoma, 2	3,622 \pm 60.0	214.7 \pm 40.5
Normal skin	1,472 \pm 44.8	175.7 \pm 22.0
Adenocarcinoma	1,170 \pm 34.6	146.7 \pm 40.7
Undifferentiated cancer	342.8 \pm 38.5	225.9 \pm 37.8

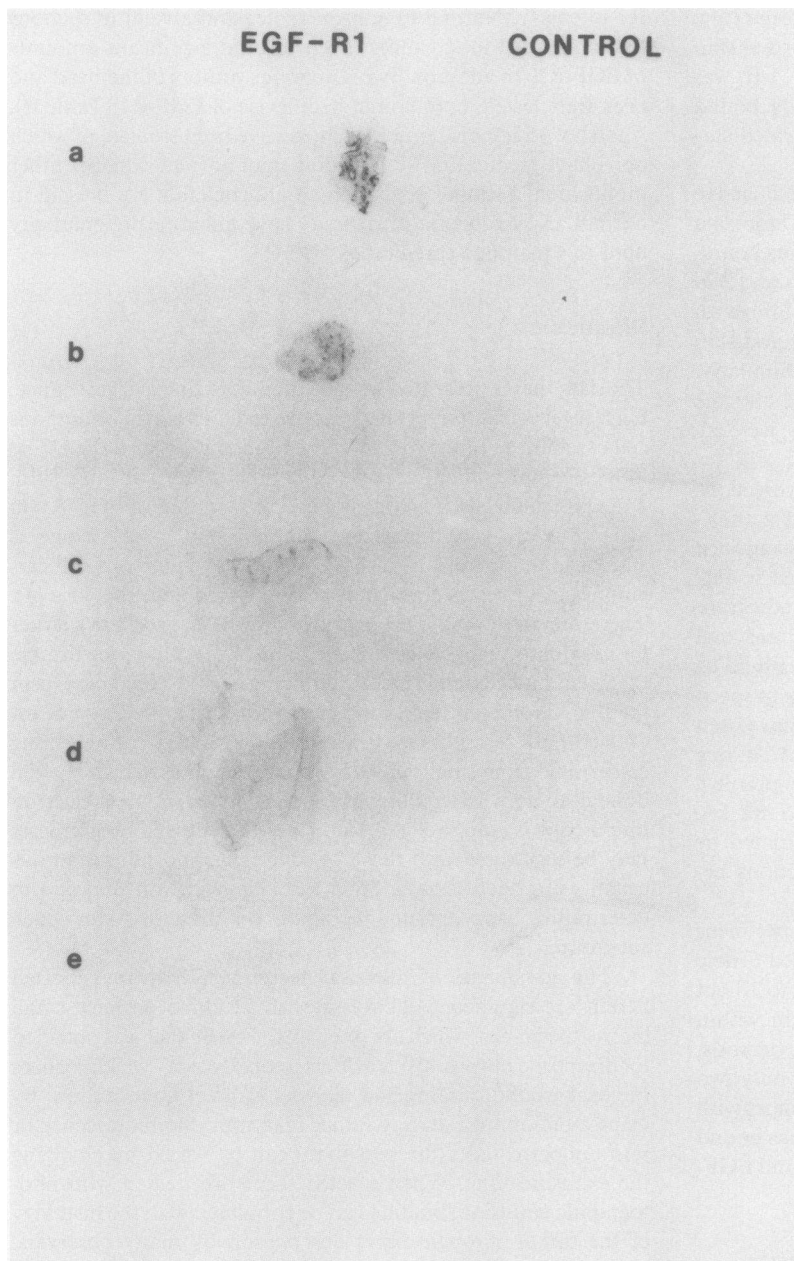


Figure 2. X-ray autoradiographs of ^{125}I -EGF-R1 bound to cryosections of lung cancer and normal skin. The identical tissue sections used in Fig. 1 are shown here. After reaction with either ^{125}I -EGF-R1 or ^{125}I -control antibody, the sections were exposed to X-ray film (XAR, Eastman Kodak Co.) for 16 h. The slides were subsequently dipped in photographic emulsion, which generated the emulsion autoradiograph shown in Fig. 1. The order of specimens is identical to that shown in Fig. 1: *a*, squamous cell carcinoma; *b*, squamous cell carcinoma; *c*, normal skin; *d*, adenocarcinoma; and *e*, undifferentiated carcinoma.

of EGF receptor is a property that is specific to epidermoid malignancies and is not an alteration that is common to tumors derived from other embryonic tissues or to proliferating epithelial cells in general. The specificity and consistency of the increase in expression of EGF receptors by squamous tumors suggests that the increase is an important step during tumorigenesis. It could provide the potential tumor cell with the ability to continually proliferate when the supply of growth factor is restricted

and/or to escape terminal differentiation. The EGF receptor is a tyrosine-specific protein kinase (12) that phosphorylates some of the same targets that are phosphorylated by viral-transforming proteins (11, 13, 14), and there is structural homology with the v. erb B oncogene (7). Although the role of the receptor in tumorigenesis remains to be defined, the elevated tyrosine kinase activity may well contribute to the malignant state of epidermoid carcinomas.

Table II. Binding of EGF-R1 Antibody to EGF Receptors in Lung Cancers and Nonmalignant Tissue

Tissue	No. of specimens	Intensity of antibody binding				
		0	1+	2+	3+	4+
Lung cancers	29					
Squamous	11	—	—	1	2	8
Adeno	8	6	1	1	—	—
Small cell	2	2	—	—	—	—
Undifferentiated	8	4	—	—	1	3
Other epidermoid neoplasms	2	—	—	—	—	2
Nonepidermoid neoplasms	35	13	22	—	—	—
Nonneoplastic						
Lung						
Alveoli	18	18	—	—	—	—
Bronchioles	14	14	—	—	—	—
Skin	4	—	4	—	—	—

Acknowledgments

We wish to thank Drs. W. Kingsley, Baylor University Medical Center, Dallas, TX, and E. Lee, Dallas Veterans Administration Medical Center, for reviewing the pathological specimens; Drs. M. Buja, K. Muntz, and J. Mitchell for assistance with the emulsion autoradiography and computerized grain counting; D. House for excellent technical assistance; and E. Rudisill and D. Tucker for preparing the manuscript. We also thank Drs. M. Brown and E. P. Frenkel for helpful suggestions and reviewing the manuscript for us. We thank Drs. J. W. Uhr, R. G. Smith, and R. Robinson (University of Texas Health Science Center at Dallas) for critically reading this manuscript.

References

1. Carpenter, G., K. J. Lembach, M. M. Morrison, and S. Cohen. 1975. Characterization of the binding of ¹²⁵I-labeled epidermal growth factor to human fibroblasts. *J. Biol. Chem.* 250:4297-4304.
2. Todaro, G. J., J. E. DeLarco, and S. Cohen. 1977. Transformation

by murine and feline sarcoma viruses specifically blocks binding of epidermal growth factor to cells. *Nature (Lond.)* 264:26-31.

3. Carpenter, G., and S. Cohen. 1979. Epidermal growth factor. *Annu. Rev. Biochem.* 48:193-216.

4. Cowley, G., J. Smith, B. Gusterson, F. Hendler, and B. Ozanne. 1984. The amount of EGF receptor is elevated on squamous cell carcinomas. *In* The Cancer Cell. Cold Spring Harbor Laboratory, Cold Spring Harbor, NY. In press.

5. Waterfield, M. D., E. Mayes, P. Stroobant, P. Bennett, S. Young, P. Goodfellow, G. S. Banting, and B. Ozanne. 1982. A monoclonal antibody to the human epidermal growth factor receptor. *J. Cell. Biochem.* 20:149-161.

6. Cooper, J. A., E. Scolnick, B. Ozanne, and T. Hunter. 1983. Epidermal growth factor receptor metabolism and protein kinase activity in human A431 cells infected with Snyder-Theilen feline sarcoma virus or Harvey or Kirsten murine sarcoma virus. *J. Virol.* 48:752-764.

7. Downward, J., Y. Yarden, E. Mayes, G. Scrace, N. Toddy, P. Stockwell, A. Ullrich, J. Schlessinger, and M. Waterfield. 1984. Close similarity of epidermal growth factor receptor and v. erb-B oncogene protein sequences. *Nature (Lond.)* 307:521-526.

8. Hendler, F. J., D. Yuan, and E. S. Vitetta. 1981. Characterization of a monoclonal antibody to human breast cancer cells. *Trans. Assoc. Amer. Phys.* 94:217-224.

9. Yuan, D., F. J. Hendler, and E. S. Vitetta. 1982. Characterization of a monoclonal antibody reactive with a subset of human breast tumors. *J. Natl. Cancer Inst.* 68:719-728.

10. Hendler, F. J., and D. Yuan. 1983. Binding of H59 and other monoclonal antibodies to human breast cancer. *In* Rational Basis for Chemotherapy. B. A. Chabner, editor. Alan R. Liss, New York. 309-314.

11. Bishop, J. M. 1983. Cellular oncogenes and retroviruses. *Annu. Rev. Biochem.* 52:301-354.

12. Ushiro, H., and S. Cohen. 1980. Identification of phosphotyrosine as a product of epidermal growth factor-activated protein kinase in A431 cell membranes. *J. Biol. Chem.* 255:8363-8365.

13. Erikson, E., D. J. Shealy, and R. Erikson. 1981. Evidence that viral transforming gene products and epidermal growth factor stimulate phosphorylation of the same cellular protein with similar specificity. *J. Biol. Chem.* 256:11381-11384.

14. Cooper, J. A., and T. Hunter. 1981. Four different classes of retroviruses induce phosphorylation of tyrosine present in similar protein. *Mol. Cell. Biol.* 1:394-407.